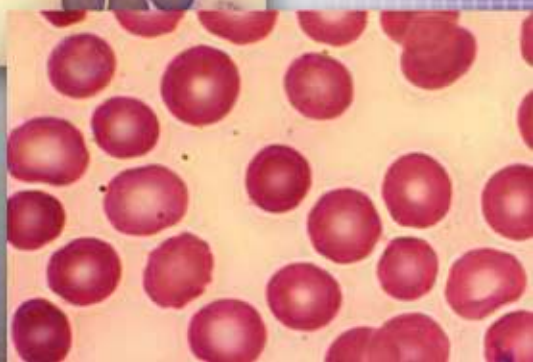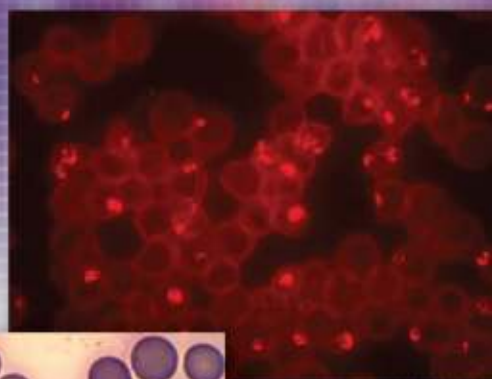
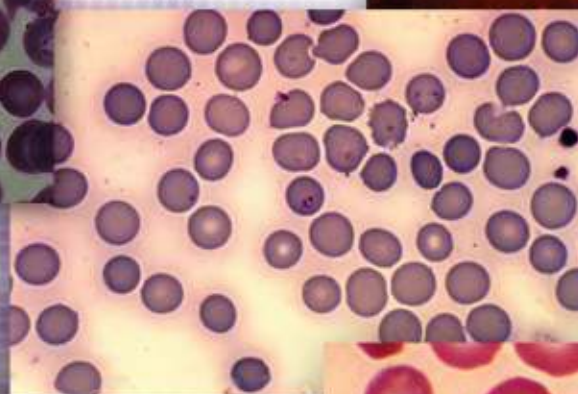
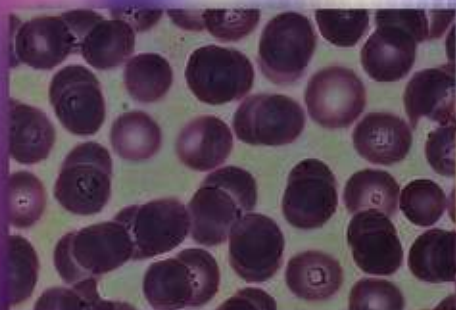


JAMES SCHALLER, M.D.

A Laboratory Guide to Human Babesia Hematology Forms

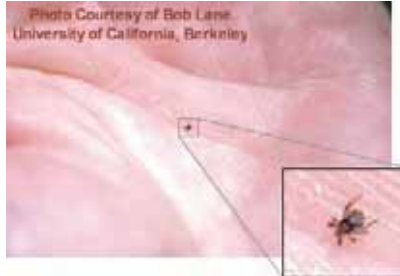


A Laboratory Guide to Human Babesia Hematology Forms

by

James Schaller, M.D., M.A.R.

Babesia Can Be Carried by “Invisible” Ticks



Cover Art by Philip Chow

Illustrations by Jamie Joyce,
James Schaller, M.D. and David Schaller

Book Production by The Gombach Group

Medical Research by Randall Blackwell
and James Schaller, M.D.

Copy Editing by Lindsay R. Gibson

Microscopy support for this text was provided by many national and international researchers who were profoundly kind and generous with their knowledge. Their numbers prevent specific thanks. They have been thanked in private. I would however like to thank Jeremy Bresette, John Voss and Stephen Fry M.S., M.D. for sacrificial slide samples provided during very busy times.

Disclaimer

Dr. Schaller is not a dermatologist. He is also not a specialist in infectious disease medicine. He is not a pathologist. He is also not claiming any expertise as a microscopist. Each of these specialties has over 2,000 diseases to treat and study. Dr. Schaller is only interested in four infections and has read and published on only these four. The medical ideas, health thoughts, health comments, products and any claims made about specific illnesses, diseases, and causes of health problems in this book are purely speculative, hypothetical, and are not meant to be authoritative in any setting. No comment or image has been evaluated by the FDA, CDC, NIH, IDSA or the AMA. Never assume any United States medical body, society, or the majority of American physicians endorse any comment in this book. No comment in this book is approved by any government agency, medical body or medical society. Nothing in this book is to be used to diagnose, treat, cure or prevent disease. The information provided in this book is for educational purposes only. It is not intended as a substitute for the advice from your physician or other healthcare professional. This book is not intended to replace or adjust any information contained on, or in, any product label or packaging.

No patient should use the information in this book for the diagnosis or treatment of any health problem, or for prescription of any medication or other treatment. You should consult with a healthcare professional before deciding on any diagnosis, or initiating any treatment plan of any kind. Dr. Schaller does not claim to be an expert in any illness, disease or treatment. In this book, he is merely sharing one of his interests. Please do not start any diet, exercise or supplementation program, or take any type of nutrient, herb, or medication without clear consultation with your licensed healthcare provider.

Babesia or Bartonella treatment comments and reports of possible positive or negative treatment outcomes are hypothetical. No treatment should be rejected or embraced by anyone based on the preliminary research and study in this book.

Some reports in this book are the result of various novel dosing, self-initiated by proactive patients. They were nevertheless monitored often. Some patients were inherited right after various treatment trials. Their outcomes were promptly measured.

In this book Dr. Schaller makes no authoritative proven claim about any treatment. Dr. Schaller only offers hypothetical ideas. Dr. Schaller makes no authoritative claims about medications, nutrients, herbs or various types of alternative medicine. The ideas in this book will need to be submitted to your local expert in allopathic medicine or to other licensed health care practitioners. This book is not meant to be an informal or formal guideline book that presumes to control 800,000 physicians or the 300 million patients they serve. You are asked to let the wisdom of your health care practitioners and your own study be a starting point to guide treatment tailored specifically to your body. Again, Dr. Schaller makes no claim to be an expert in any aspect of medicine. He makes no claim to know more than other physicians.

Dr. Schaller makes no claim that any statement in this book is correct.

Names and minor personal details within this book have been changed to preserve privacy.

Since this appears to be the first book exclusively dedicated to showing Babesia forms, it is likely it contains errors. This is common with books that are the first on a topic. Every reasonable effort has been made to try to not overstate findings. Further, it is important to realize that any single image can have multiple causes, and not all of these may be known to this author or to other health practitioners. Therefore, all health care practitioners should look for other confirmations outside this book, before beginning on any treatment plan if possible. It is fully appreciated that it is hard to diagnose Babesia infections.



To Richard and Annie Swartley

Thank you for sacrificing for the world, America and my family



Contents

The Insight Disaster	1
An Introduction to Babesia Identification	5
Distinguishing Babesia from Bartonella, Platelets and Anemia	11
Babesia Images from the Centers for Disease Control	37
Babesia in Thick Smears	79
Babesia FISH Samples	85
Babesia Sketches	99
Babesia Images with Commentary	139
Enlarged Babesia Single Cells	191
Final Sample Forms	209
Babesia Image Search List for Lab	229
Other Sample Publications of Dr. Schaller	231

Why is this book important?

It is the first book in history to collect every major presentation of Babesia.



Insight is Everything

They pretended to listen to me with glassy eyes. They had obvious signs of Lyme disease, Babesia or Bartonella, but they smirked and ignored me.

They are part of the lost, and their lives will be ruined forever.

The Insight Disaster

Many people with tick or flea-borne infections are unable to “see” themselves. They do not notice tiny decreases in their abilities or personality changes.


The first thing to go with Babesia and other tick-borne infections is insight.



Life is hard for Gus. He never reflects on tick or flea infections, even when he is out in his backyard. He has no insight. Insight is an advanced brain ability that depends on a very well functioning brain. Any inflammation or infection can destroy it.

I routinely meet people with tick or flea infections, and they have clear subtle psychiatric or cognitive troubles, and they reject any appeal for testing. Some call such people “too far gone.” They say such people are “too late.” If you are a health care worker try to prevent the loss of such people.

Joe is rigid and defensive about tick infection topics. You try talking to him and in August he pretends it is January. He refuses to consider that his time near wild shrubs or woods could have exposed him to invisible, infectious dot-sized ticks.



Dad simply does not want to hear new ideas or other opinions. He is too far gone.

Avoidance and ignoring reality are common in some Babesia infected patients. Their “let’s move along” thought process is much like a young child who avoids eating peas by pretending the vegetables are not on his plate. Infected patients will often say “this does not exist,” or “I am 100% fine.”

Since veterinary research shows that tick infections are active in all 50 states, health care workers need to be thinking with 2010 medical mind sets concerning such **emerging infections** as Babesia, Atypical Bartonella and Lyme disease. Missing these infections is dangerous and can result in irreversible internal health problems for infected patients.

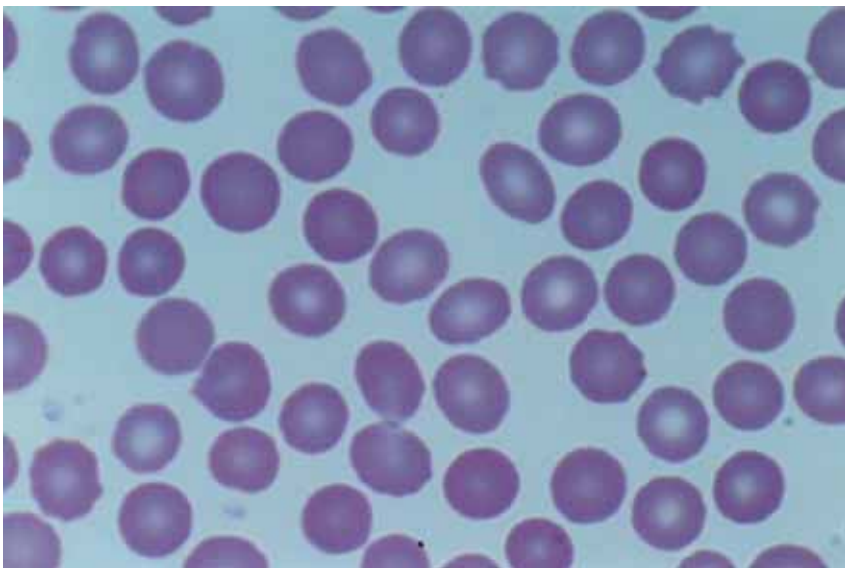
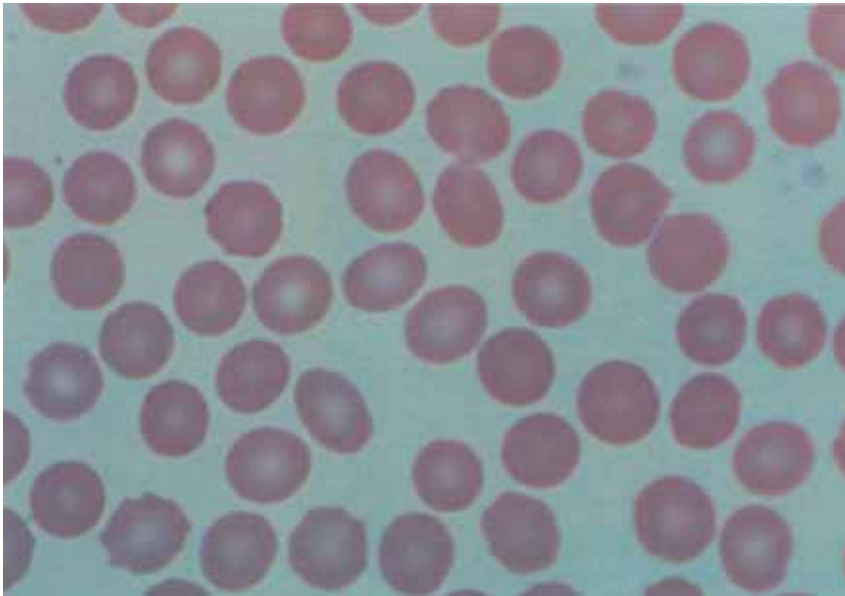
I have met a number of physicians who are aggressive learners of tick and flea infections. They report that if one person in a family has Babesia, Bartonella, or Lyme, at least 50% of the others in the family have it, and if two family members have Lyme disease or Atypical Bartonella, the entire family should be tested. The same could be said about Babesia. If one family member has it, it should be aggressively and fully checked by very extensive testing in other family members. Many simple and routine lab tests miss Babesia, Bartonella and Lyme disease. Smart and talented laboratory researchers and fine companies have just not been able to optimize their testing. And many species are not yet even able to be tested for yet, partly because they have only recently been discovered, or there is little demand for investment in optimal testing.

An Introduction to Babesia Identification

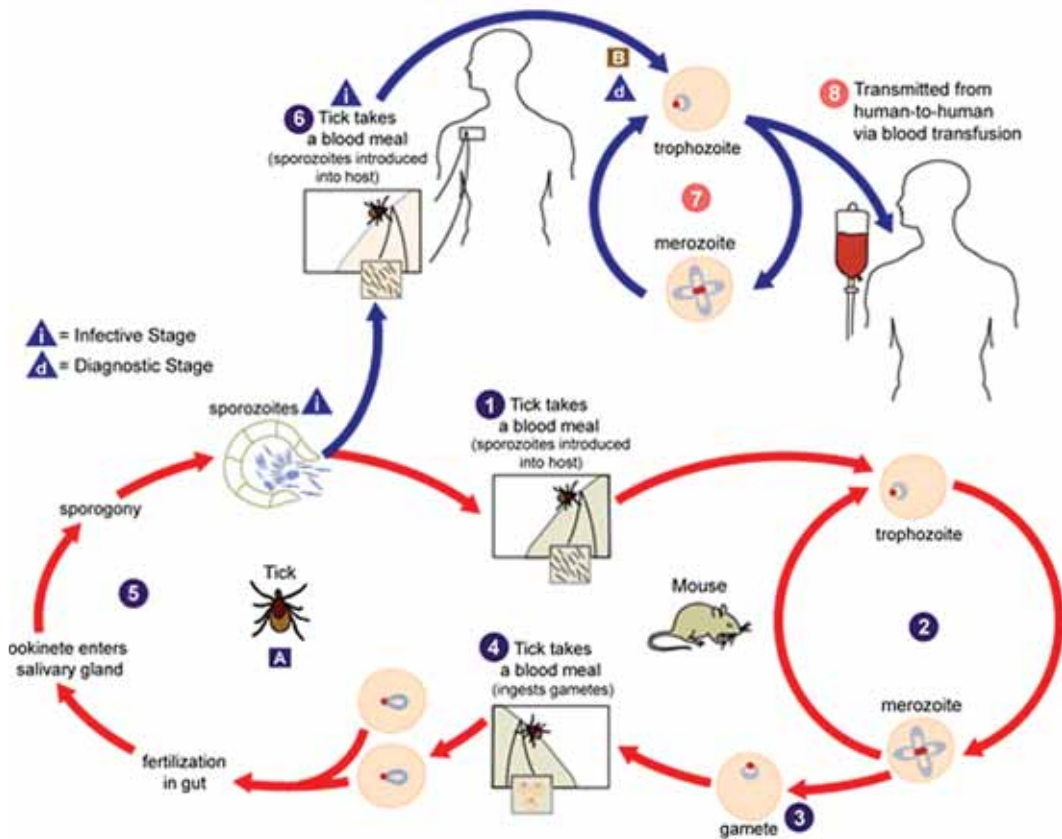
When examining red blood cells, it is important to know the general health, diseases and surgeries in any patient whose blood smear slide is being reviewed.

Virtually every slide in this book is derived from patients with approximately normal iron levels, and none had blood or bone marrow disease. No one had serious spleen disease or a spleen removal. Further, patients had no genetic blood related diseases.

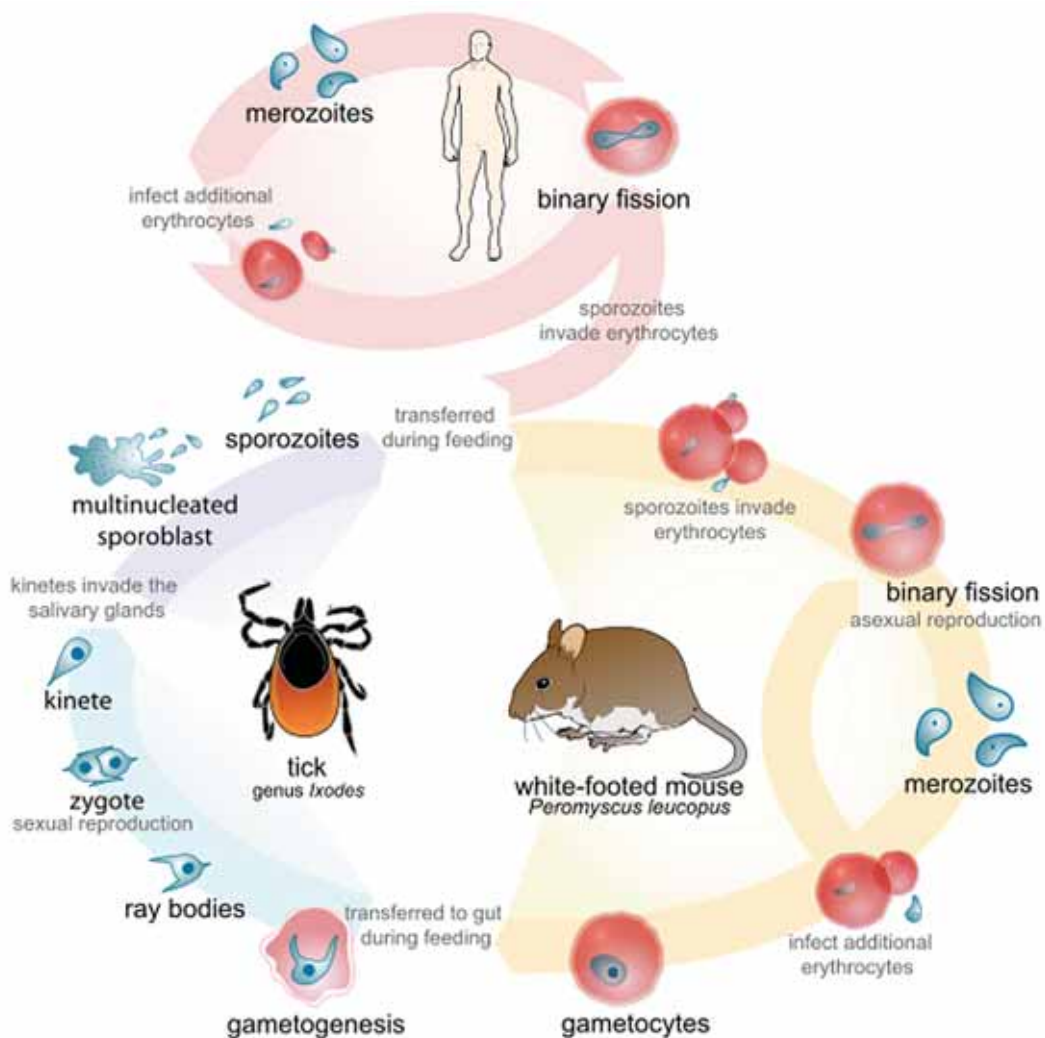
**Normal Red Blood Cells with no nucleus
and hollowed-out centers.**



Above images: Normal red blood cells with no evidence of bacteria or parasite infection. Note the hollow white centers, indicating the absence of any nucleus. No Babesia or Bartonella is present in these red blood cells and there are no bacteria attached to the outer cell membranes. (Blood slides courtesy of Stephen Fry, M.S., M.D., and Jeremy Bresette, B.S., MT)

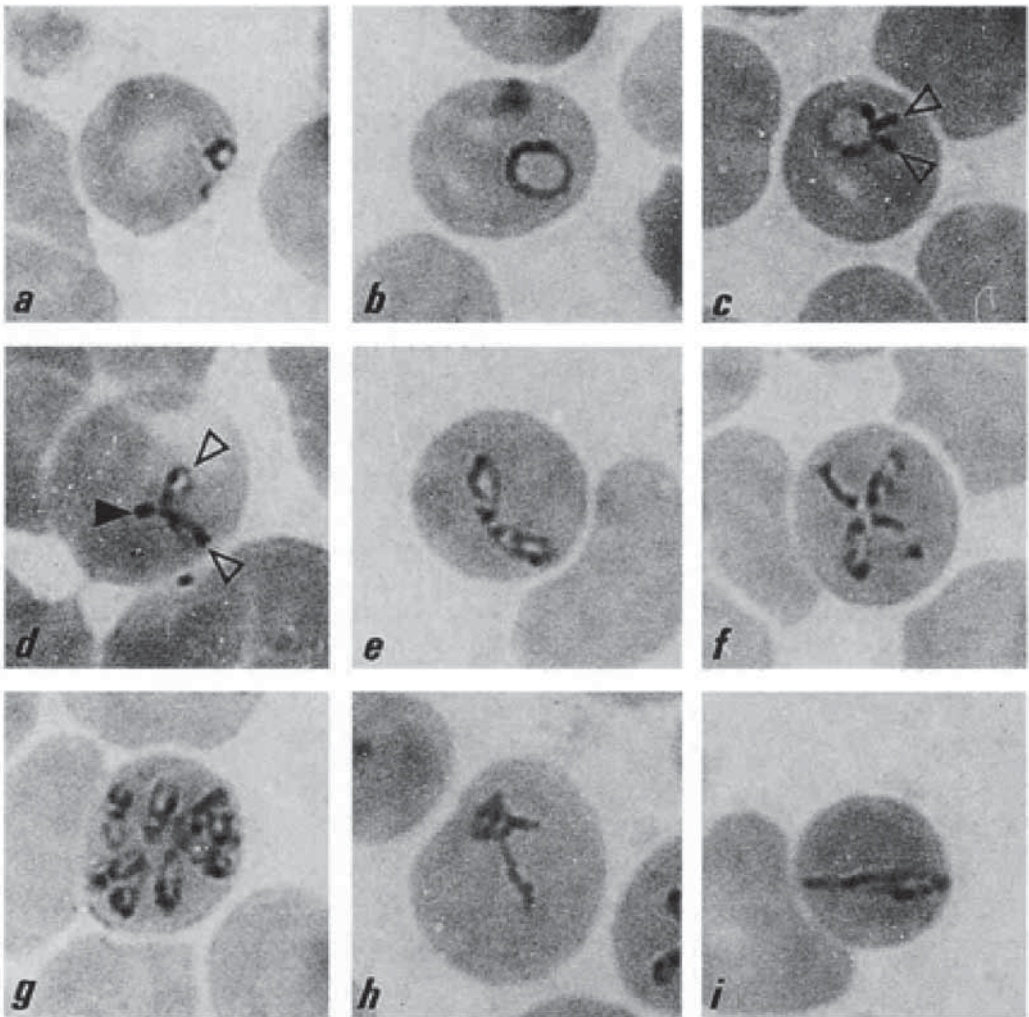


Some of the forms shown above can be seen in blood smear samples. Note the diversity. They appear as more than simple ring forms.



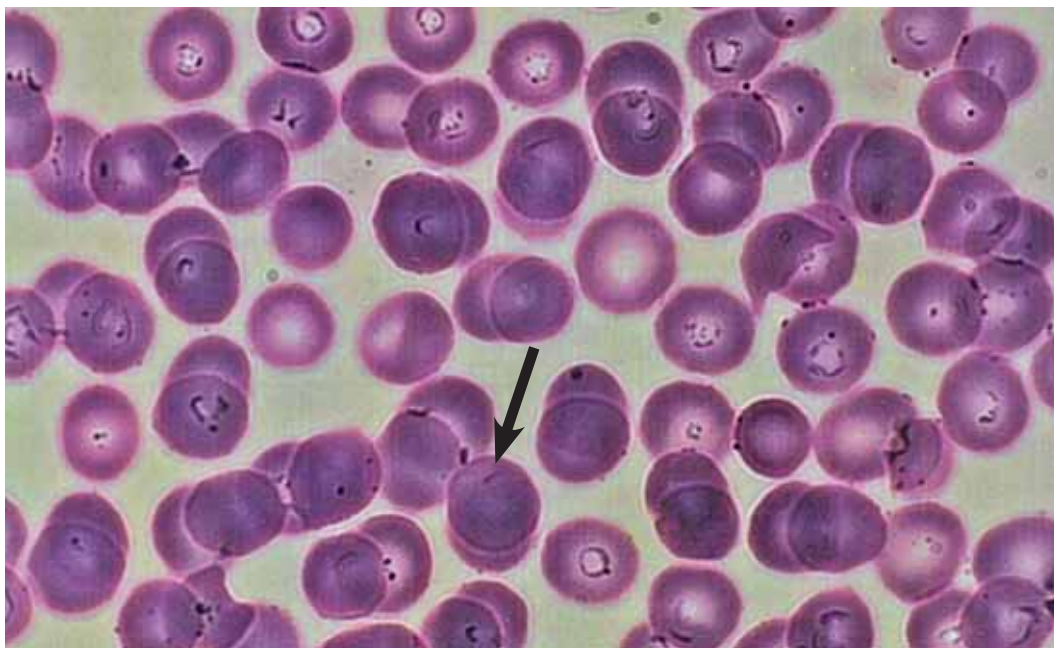
Note the stunning variety of Babesia forms. In most parasite and hematology books one might only see three of these many forms.

Distinguishing Babesia From Bartonella, Platelets and Anemia



Giemsa-stained blood smear from a patient who acquired babesiosis in Missouri. A. Ring stage, just after invasion of the erythrocyte by a merozoite. B. Trophozoite stage. C. Trophozoite stage with two budding merozoites (hollow arrows). D. Two merozoites (hollow arrows) joined by a residual body (solid arrow). E. Paired piriform parasites. F. Tetrad form (“Maltese cross”). G. Polyparasitism. H. Crisis form. I. Crisis form.

Herwaldt BL, Persing DH, Precigont EA, Goff WL, Mathiesen DA, Taylor PW, Eberhard ML, Gorenflot AF, 1996. A fatal case of babesiosis in Missouri: identification of another piroplasm that infects humans. *Ann Intern Med* 124: 643–650. Reprinted images used with written permission from the *Annals of Internal Medicine*.

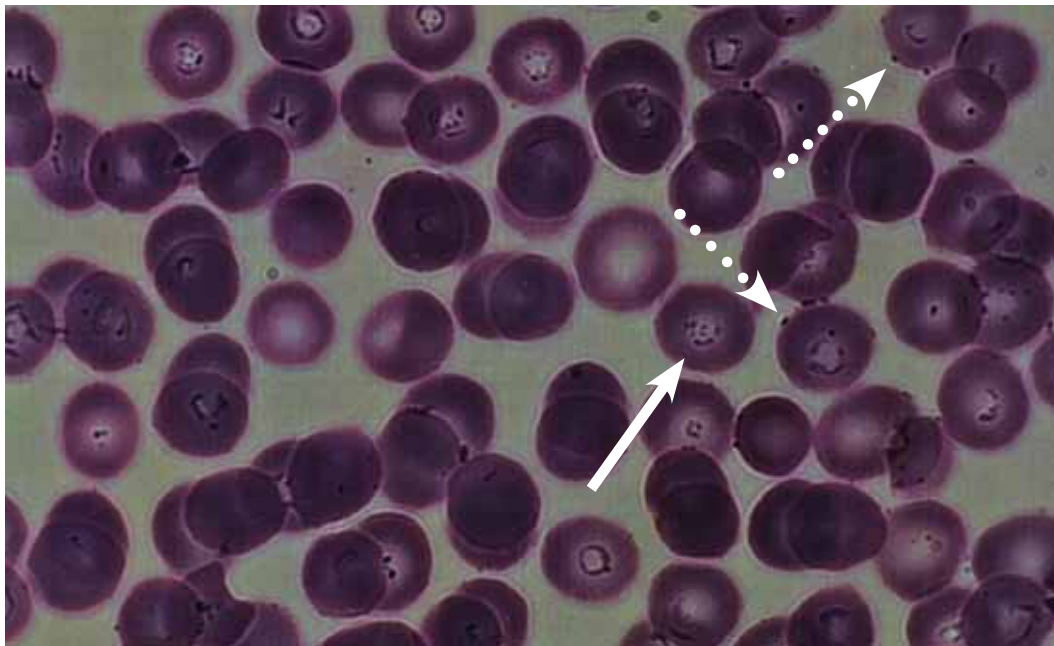


Babesia “Worm Pattern” or Bartonella Bacteria Cluster?

On occasion, some red blood cell (RBC) infectious findings are unclear. One challenge is determining if something is Bartonella bacteria or Babesia without any cytoplasm around it. The problem is that Bartonella can go inside the RBC and also attach to the outside of the RBC. And Babesia is **inside** the RBC and also can be **outside** the RBCs and sometimes can attach to the outer RBC edge.

So sometimes we have to use other labs or look at other forms present in a slide to determine if we are looking at Babesia, Bartonella or some iron related finding, e.g., an immature red blood cell or reticulocyte.

This worm-like form can be found with Babesia and some forms of animal or perhaps human Bartonella. Looking at other findings on a slide may help determine if one or both of these infections are present.



Babesia or Bartonella?

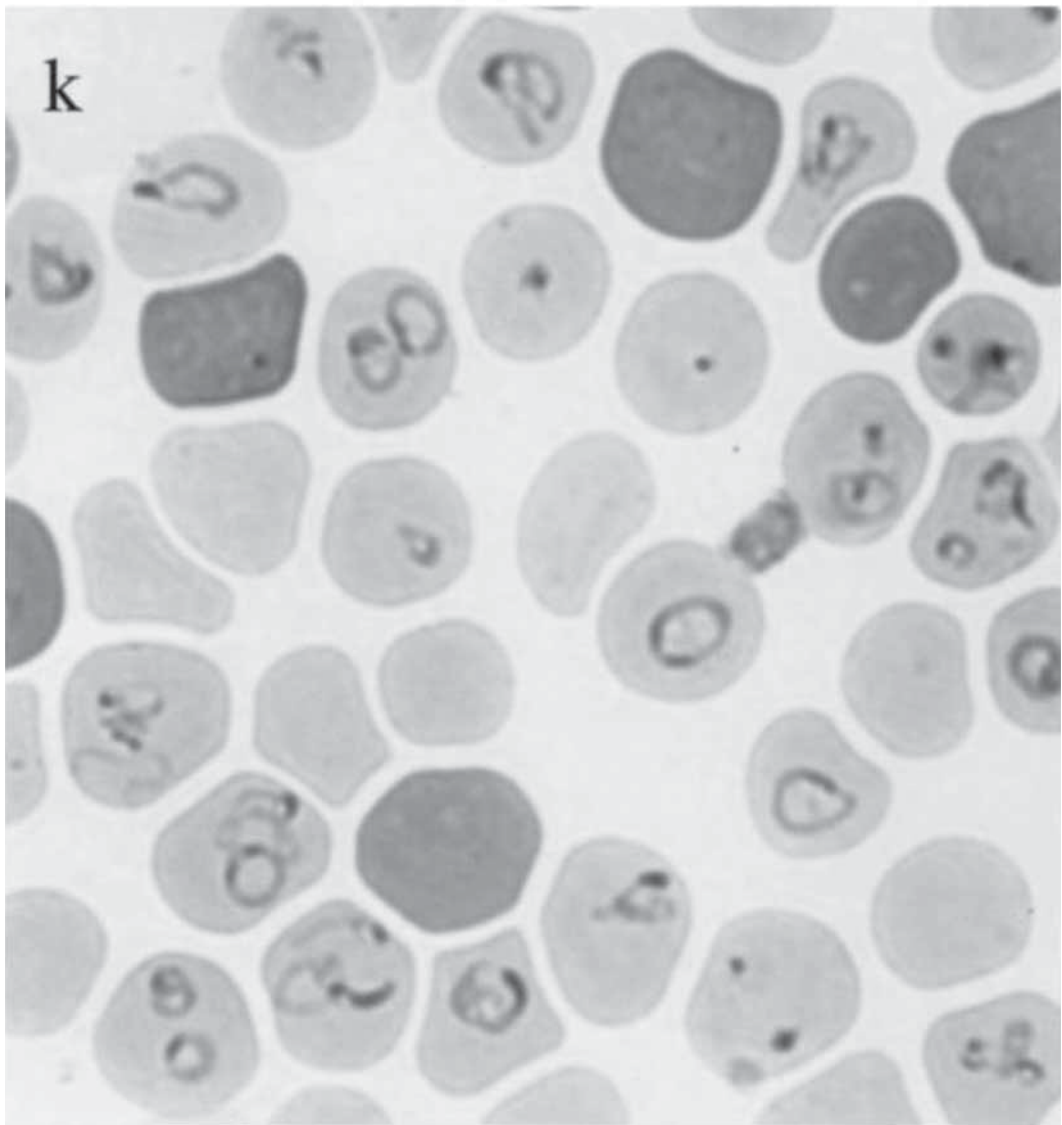
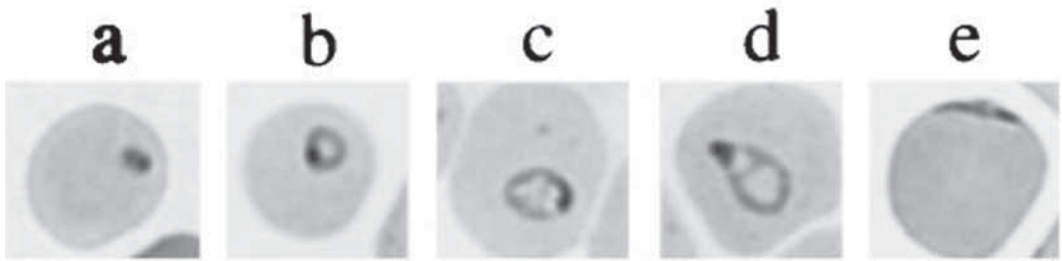
The oval Bartonella bacteria marked with dotted arrows on the outside of these highly enlarged RBCs are quite large. And since Bartonella can enter the cell and also the center of the RBC, it is hard to know if this wide area in the center of the RBC is some type of Babesia, a cluster of Bartonella bacteria or a combination of both. High quality genus PCR will allow us to determine the presence of the parasite Babesia or the bacteria Bartonella. And yet, in this book, our unique collection of Bartonella images **inside** RBCs shows they do not seem to form rings.

Another way to begin to learn how to distinguish Babesia from Bartonella is to note the size of the organism attached to the outside of the RBC. Is it tiny? Does it have clear cytoplasm around it? Do the outer oval dots resemble bacteria-like organisms inside the RBC? My concern is how informed a few Bartonella experts are about Babesia forms when they can look **exactly** like some Bartonella forms. Many use DNA markers for Bartonella, adding to the chance that it is Bartonella if the DNA or PCR testing is superior. We have found no US lab that is fully accurate at detecting Bartonella or Babesia DNA. While some forms can look similar between Babesia and Bartonella, I believe when one sees a ring it is Babesia.

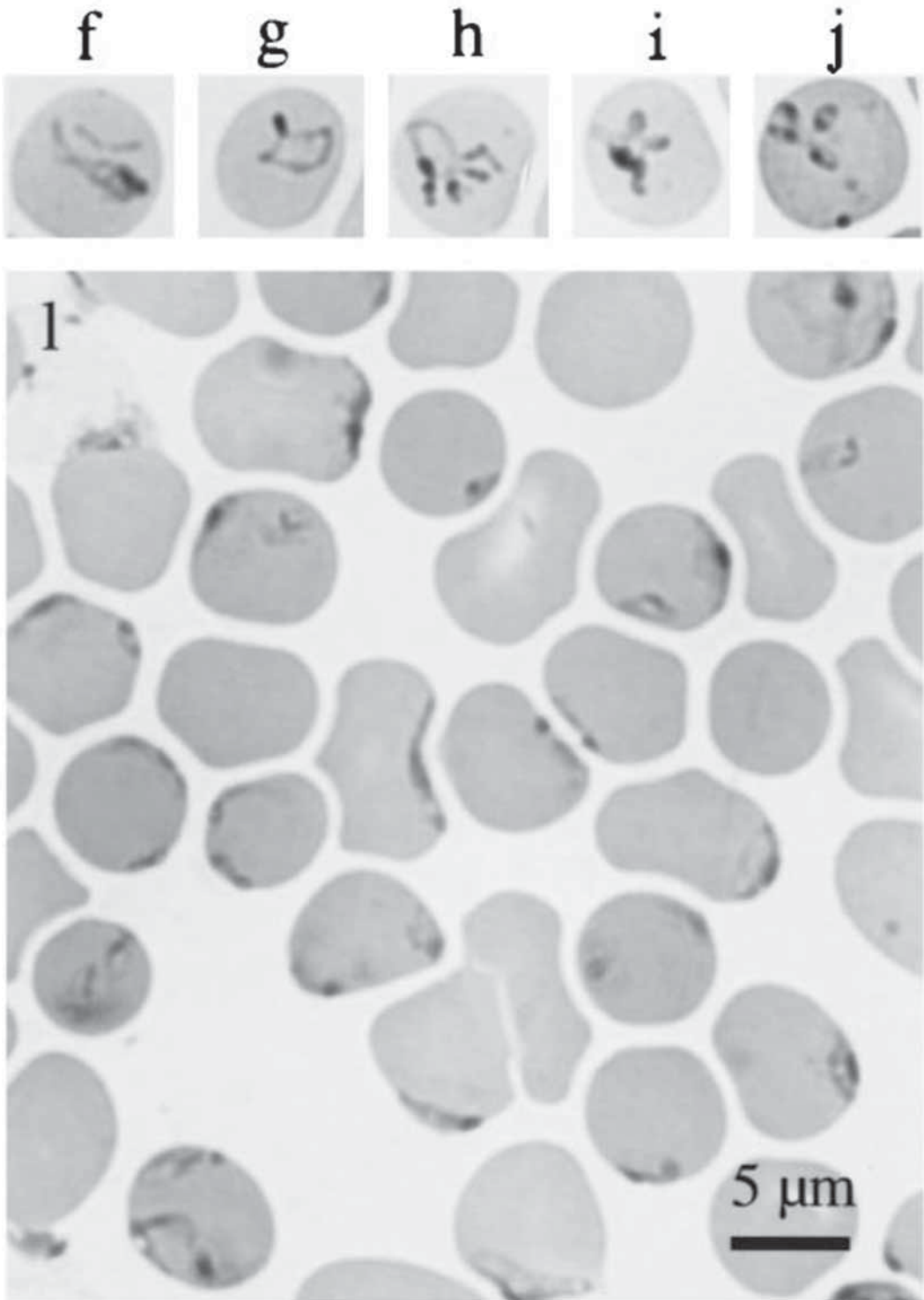
A few microbiologists think that Bartonella might form rings when inside RBCs. This is speculative. **Genus** PCR will be available possibly from Fry clinical labs perhaps in the fall of 2008, and this will help determine what infectious agent is Babesia or Bartonella. Further, IGeneX is developing FISH and other new testing for vast numbers of Babesia and Bartonella species — this will also help. And perhaps in time, larger labs will follow their lead with these highly serious emerging infections.

Because both Bartonella and Babesia are emerging infections, it is typical that even our most valuable and sincere health care workers either have no basic knowledge of their existence, or work with beliefs and references that are decades out of date. If our lab science and clinical knowledge does not improve a thousand fold, both infections will continue to cause a myriad of medical problems, including death in severe cases (as I have reported in recent textbooks and medical journals).

Finally, before we start examining cells, I want to remind you that when unusual patterns are present, it is important to look at the presentation of the other red blood cells. Do they show signs of an iron disease or anemia? Do they resemble iron related worm-like findings such as those common in new red blood cells or reticulocytes?



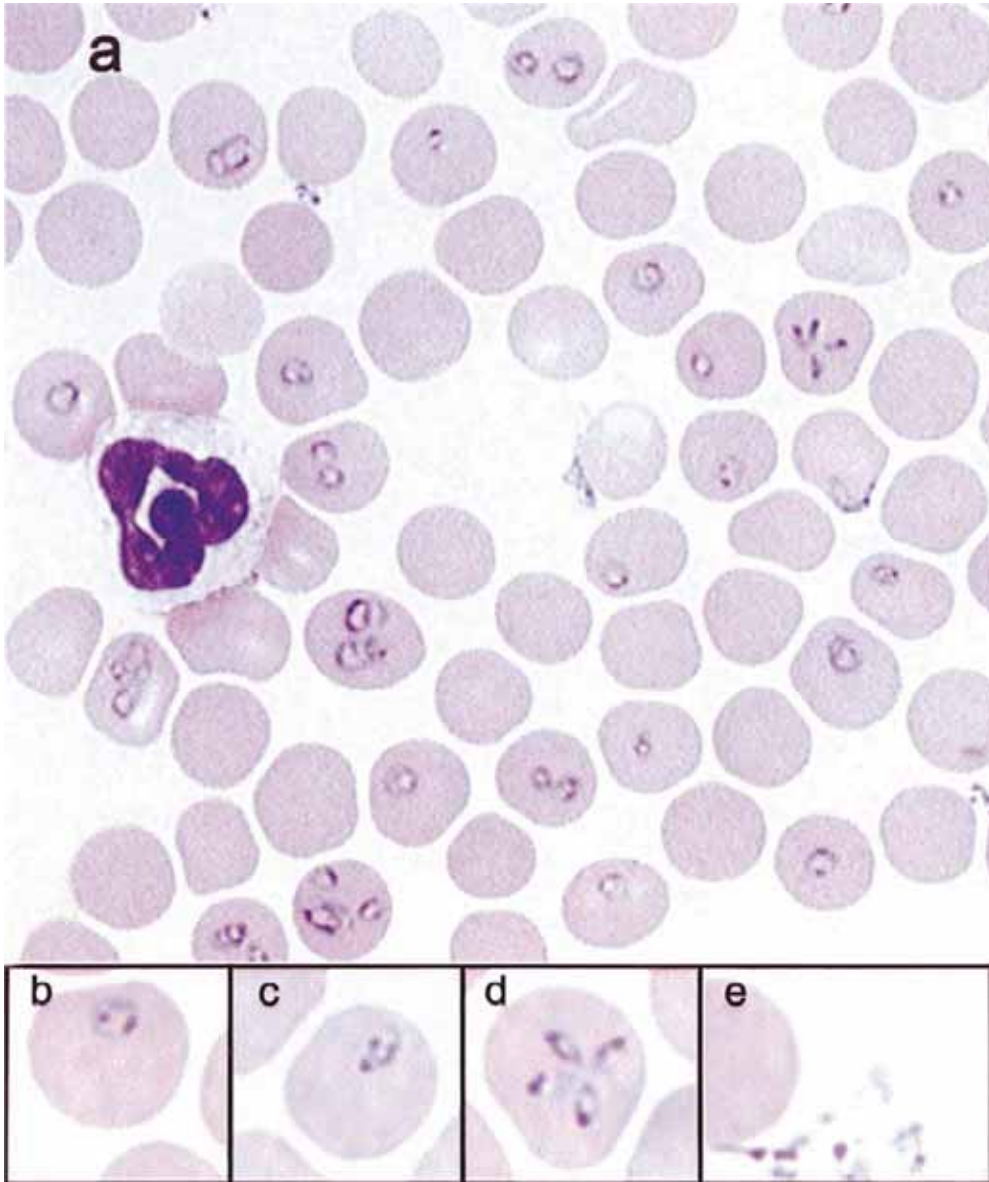
Please note that this Babesia infected sample has approximately 15 different presentations. If someone believed some dot or dots with attached lines were Bartonella, I believe they would be wrong — these are all Babesia forms.



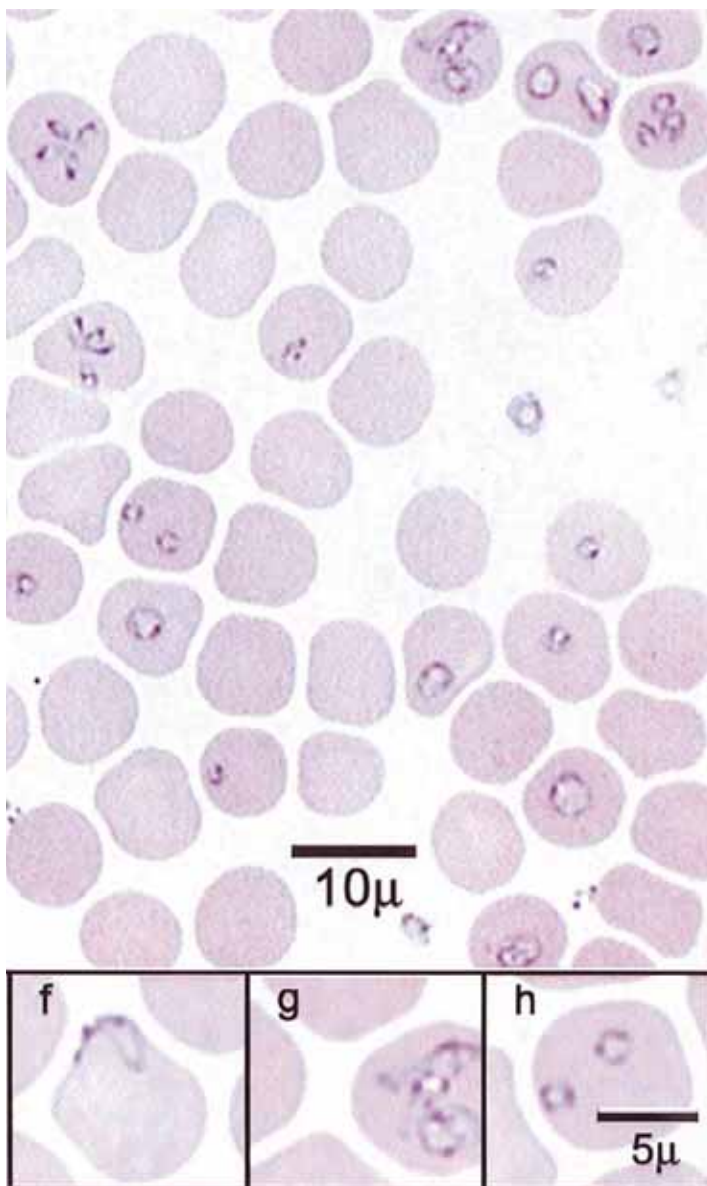
Please note some very important findings in this amazing slide. Figures f and h show straight line formations which could be confused with iron

findings in reticulocytes. An occasional evaluator might also mistake such lines for a couple of Bartonella combined, but this would be an error.

Please also note in these Babesia images, that the formations appear on the edge of the cells and are quite similar to some Bartonella images. However, **they all seem to have at least one dot on the linear outer line.**

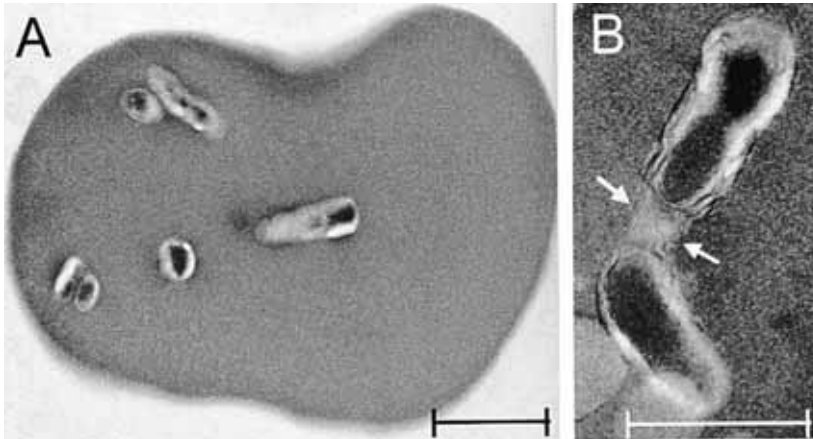


Please note the profound diversity of Babesia above with at least a dozen Babesia patterns. Dots in this entire slide are not Bartonella dots but Babesia forms. Note also that square e illustrates extracellular Babesia.

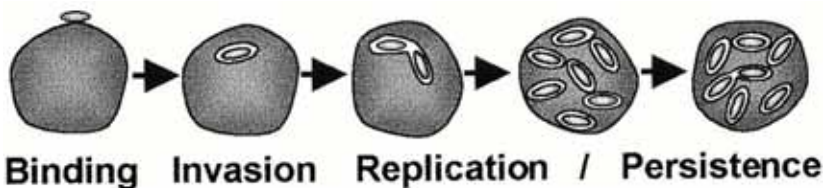


Note the wide range of forms in this slide. For example, square f shows a beaded line that ends with a tongue-like clear cytoplasm edge rolling over the top of the RBC. No dot in this slide is **clear** Bartonella.

In square g there are highly complex rings, dark angled lines and fused forms.

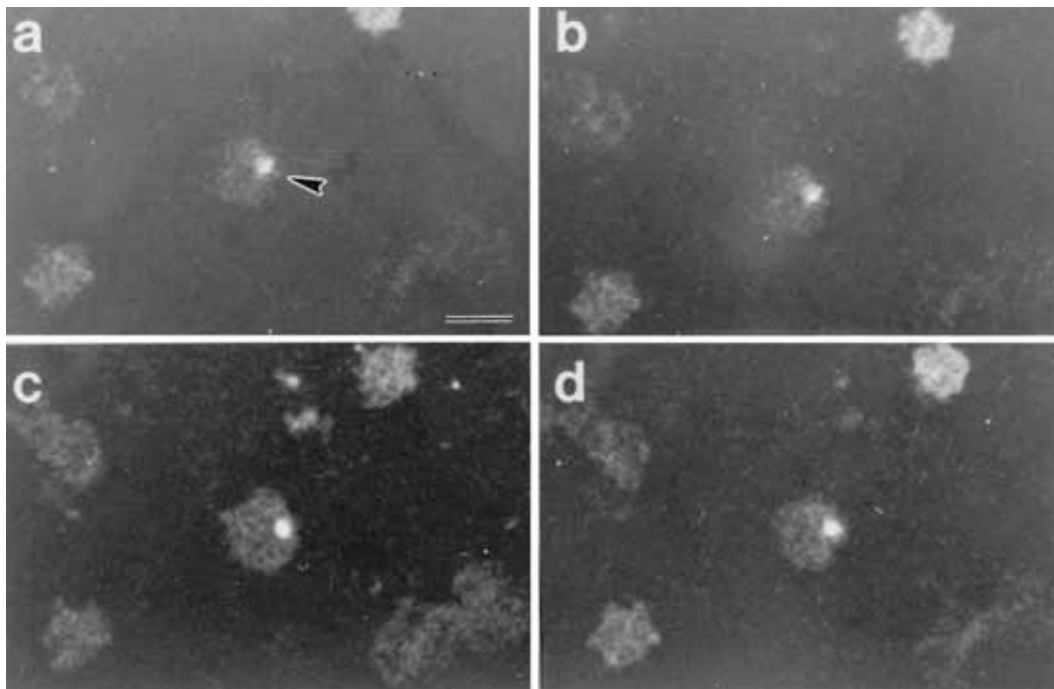


Electron micrographs of rat erythrocytes with *Bartonella*. (A) Cross-section of an erythrocyte showing several intracellular bacteria. Original magnification x12. (B) Two intracellular bacteria presumably surrounded by one vacuolar membrane (arrows). Original magnification x30. Scale bars correspond to 1 μm .



Model of erythrocyte parasitism by *Bartonella* species.

Ralf Schülein, Anja Seubert, Christian Gille, Christa Lanz, Yves Hansmann, Yves Piémont and Christoph Dehio. Invasion and Persistent Intracellular Colonization of Erythrocytes: A Unique Parasitic Strategy of the Emerging Pathogen *Bartonella*. *The Journal of Experimental Medicine*. 2001;193: 2001 1077-1086. Written permission kindly given by Christoph Dehio, Biozentrum of the University of Basel, Dept. of Molecular Microbiology, Switzerland.

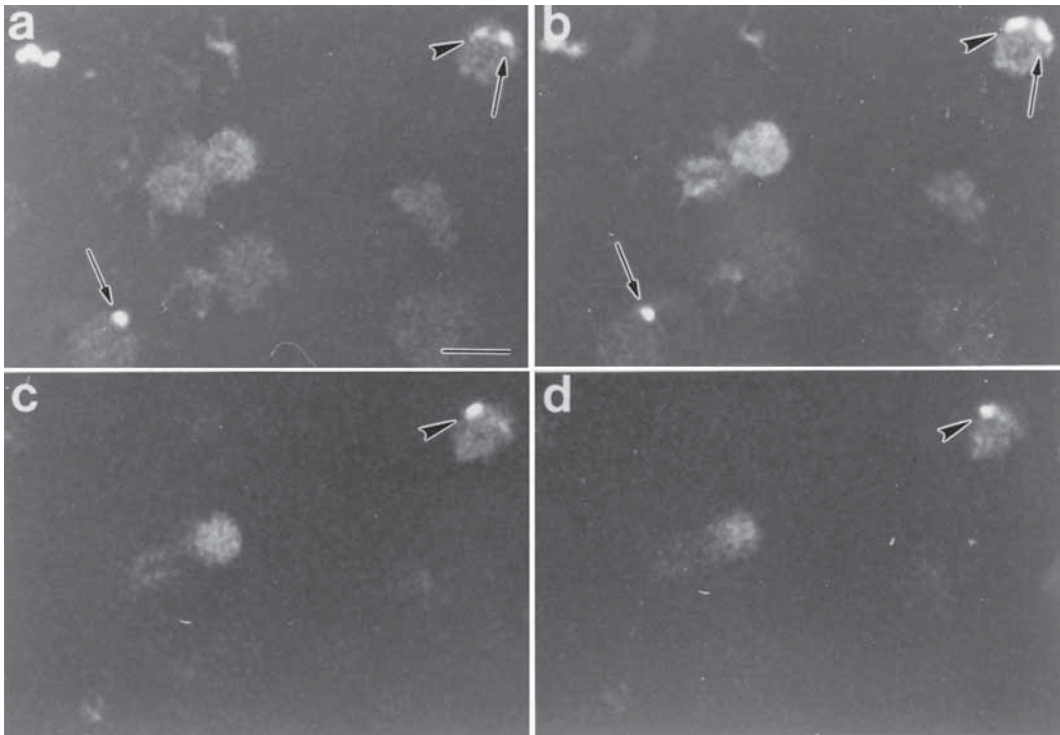


Bartonella Infection Samples Possibly Confused with Babesia Images

Digital sections of feline RBC after infection with *Bartonella henselae*, as viewed by laser scanning confocal microscopy. Shown are sections taken in increments from top to bottom. Note that the fluorescence intensity of the *B. henselae* cell (arrowhead) was low in panels a and b and increased in panel c. The *B. henselae* cell can be seen clearly within the RBC membrane and was probably intracellular. In panel d, the fluorescence intensity of the *Bartonella* cell diminished. Bar, 5 μm ; magnification, $\times 1,000$.

Used with Permission from The American Society of Microbiology.

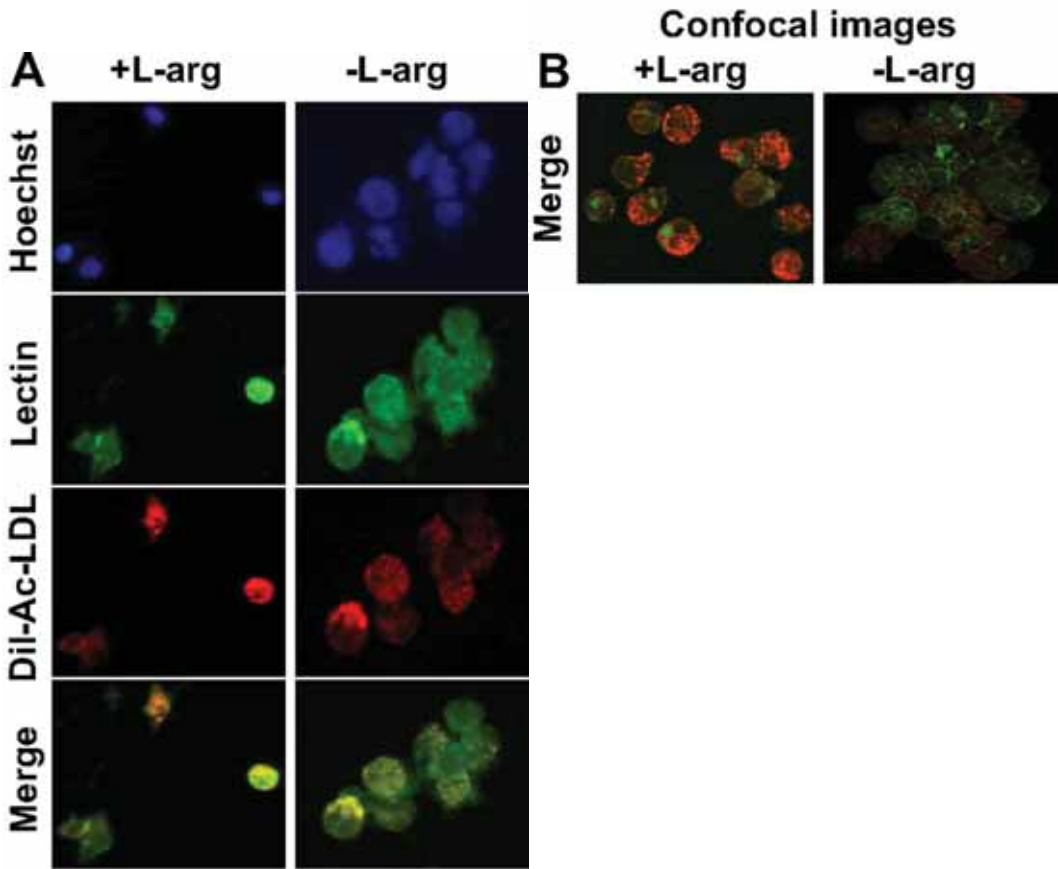
Jane R. Mehock, Craig E. Greene, Frank C. Gherardini, Tae-Wook Hahn, and Duncan C. Krause, *Bartonella henselae* Invasion of Feline Erythrocytes In Vitro. *Infect. Immun.* 1998;66: 3462-3466.



Digital sections of feline RBC after infection with *B. henselae*, as viewed by laser scanning confocal microscopy at various lengths. The arrowhead indicates a likely intracellular *B. henselae* cell, while the arrows indicate probable epicellular *B. henselae* cells.

Used with Permission from The American Society of Microbiology.

Jane R. Mehock, Craig E. Greene, Frank C. Gherardini, Tae-Wook Hahn, and Duncan C. Krause. *Bartonella henselae* Invasion of Feline Erythrocytes In Vitro. *Infect. Immun.* 1998;66: 3462-3466.

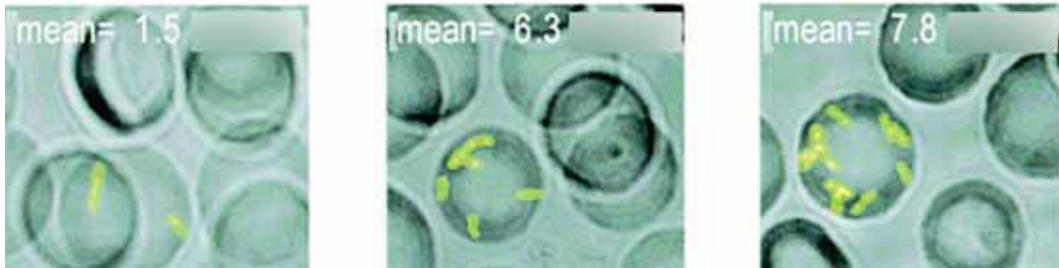


These stunning images show **small round or long oval Bartonella** inside of specialized circulating endothelial progenitor cells. Bartonella enters the vascular lining of blood vessels throughout the body and can be very dangerous.

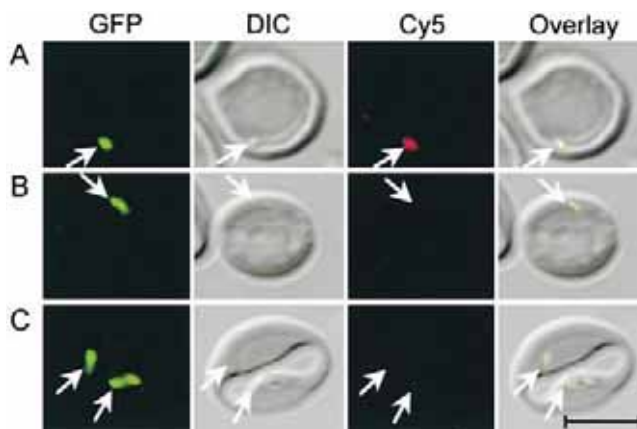
(L-arginine hinders Bartonella processes and might augment emerging treatments. Current routine treatments are ineffective and do not improve functionality and productivity according to a recent English two volume Bartonella textbook).

Bartonella and l-arginine. Circulating endothelial progenitor cells infected with *Bartonella* in the presence or absence of l-arg. (A) Representative images by immunofluorescence. (B) Selected merge images were acquired by confocal microscopy. (Magnification: all, $\times 630$.)

Paola Salvatore, Amelia Casamassimi, et al., Detrimental effects of *Bartonella henselae* are counteracted by l-arginine and nitric oxide in human endothelial progenitor cells. *PNAS*. 2008;105:9427-9432; Copyright 2008 National Academy of Sciences, U.S.A.



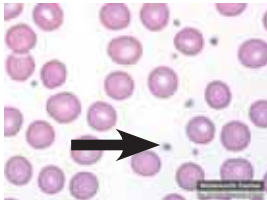
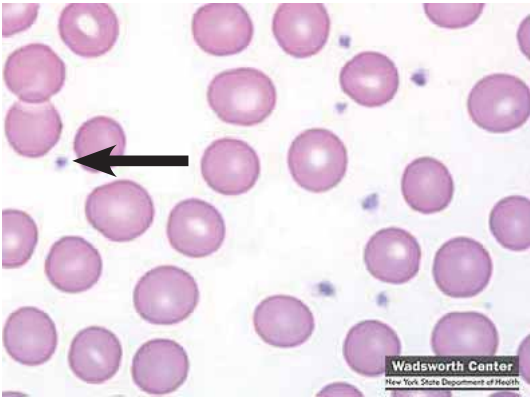
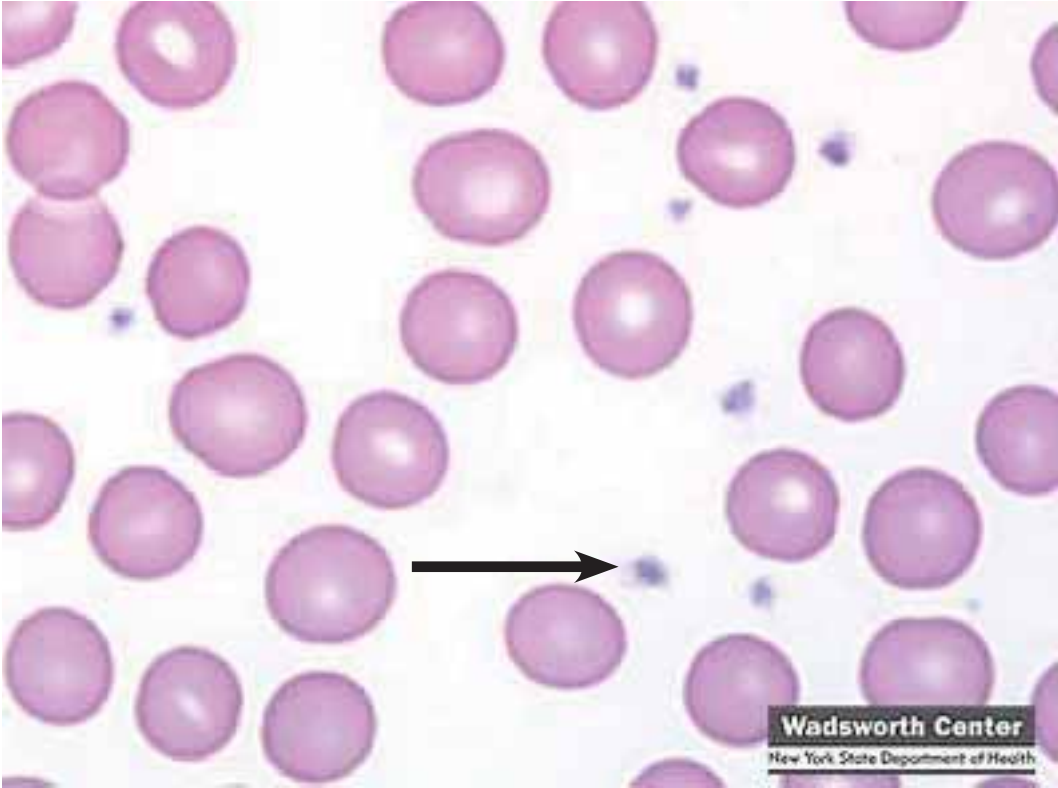
Confocal images of Bartonella infected erythrocytes (RBCs) which appear to have 0-8 Bartonella in each RBC. These numbers may vary with “waves” of infection.



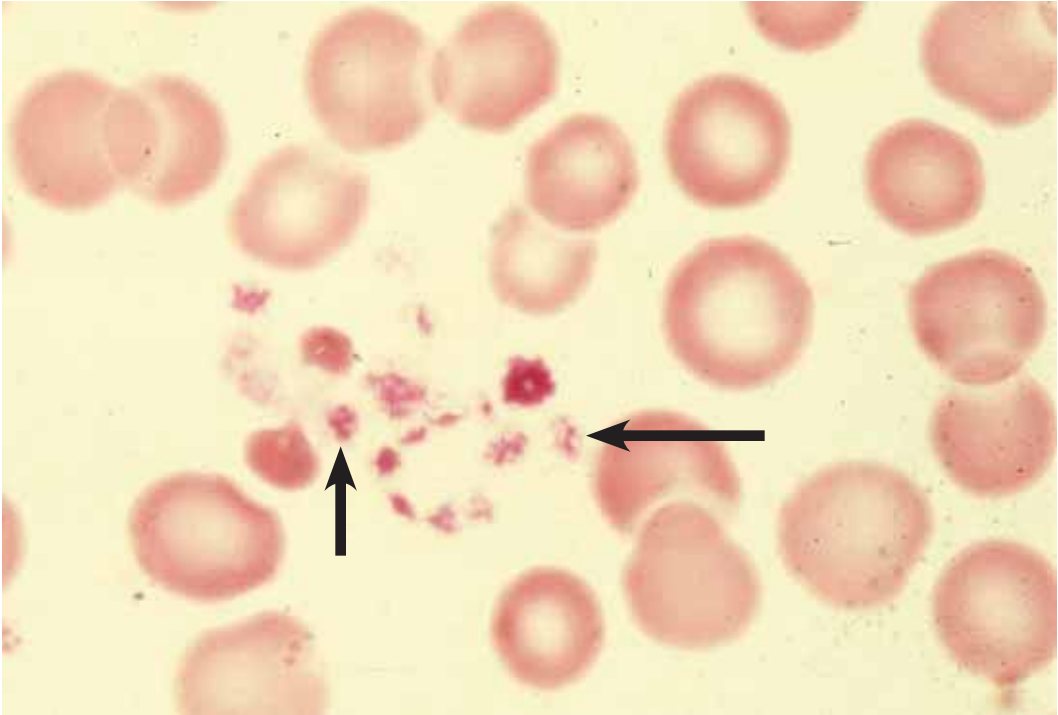
Research Grade Bartonella Highlighting Reveals Shapes and Sizes

Stained RBC smears were analyzed by confocal microscopy using GFP fluorescence (GFP) to visualize bacteria, differential interference contrast (DIC) to visualize RBCs, and Cy5 fluorescence to visualize adherent bacteria. An overlay of all three channels is also shown. Representative infected erythrocytes obtained from blood on day 6 (A and B) or day 7 (C) are shown. Arrows indicate the position of RBC-associated bacteria. The scale bar corresponds to 5 μm .

Ralf Schüle, Anja Seubert, Christian Gille, Christa Lanz, Yves Hansmann, Yves Piémont and Christoph Dehio. Invasion and Persistent Intracellular Colonization of Erythrocytes: A Unique Parasitic Strategy of the Emerging Pathogen Bartonella. *The Journal of Experimental Medicine*. 2001;193: 2001 1077-1086. Written permission kindly given by Christoph Dehio, Biozentrum of the University of Basel, Dept. of Molecular Microbiology, Switzerland.

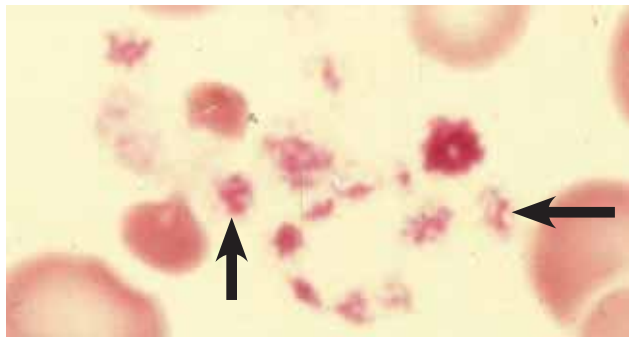


Three resolutions and sizes of the same slide with platelets. Some Babesia forms can look like platelets. Here are normal platelets that do **not** look like Babesia.

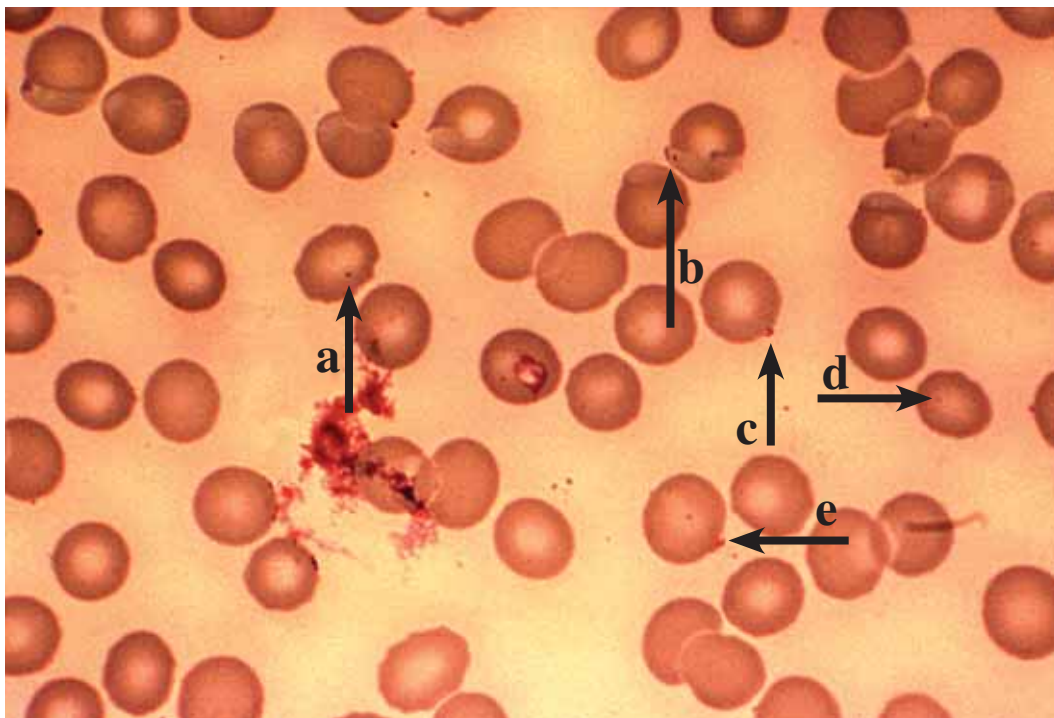


This is a blood sample from approximately 1975. It is the blood of a female CEO of a fortune 500 company. I do not believe that she has Babesia because, while Babesia can have zero symptoms, it is my very strong opinion that it eventually “wins.” In other words, it will eventually defeat the immune system’s ability to control it, and patients will become symptomatic. Babesia illness may present one, five, ten or perhaps even twenty years after the subject receives a tiny invisible deer tick bite.

I do not believe a person can have Babesia for 25 years and have no symptoms. The fact that this woman is highly functional strongly supports Dr. George’s conclusion that this is a platelet presentation rather than an extracellular form of Babesia. The fact that the oval, eye-like forms lack a highly sharp outline is **perhaps** another clue.



(Used with permission from James N. George, M.D.,
University of Oklahoma Health Sciences Center)



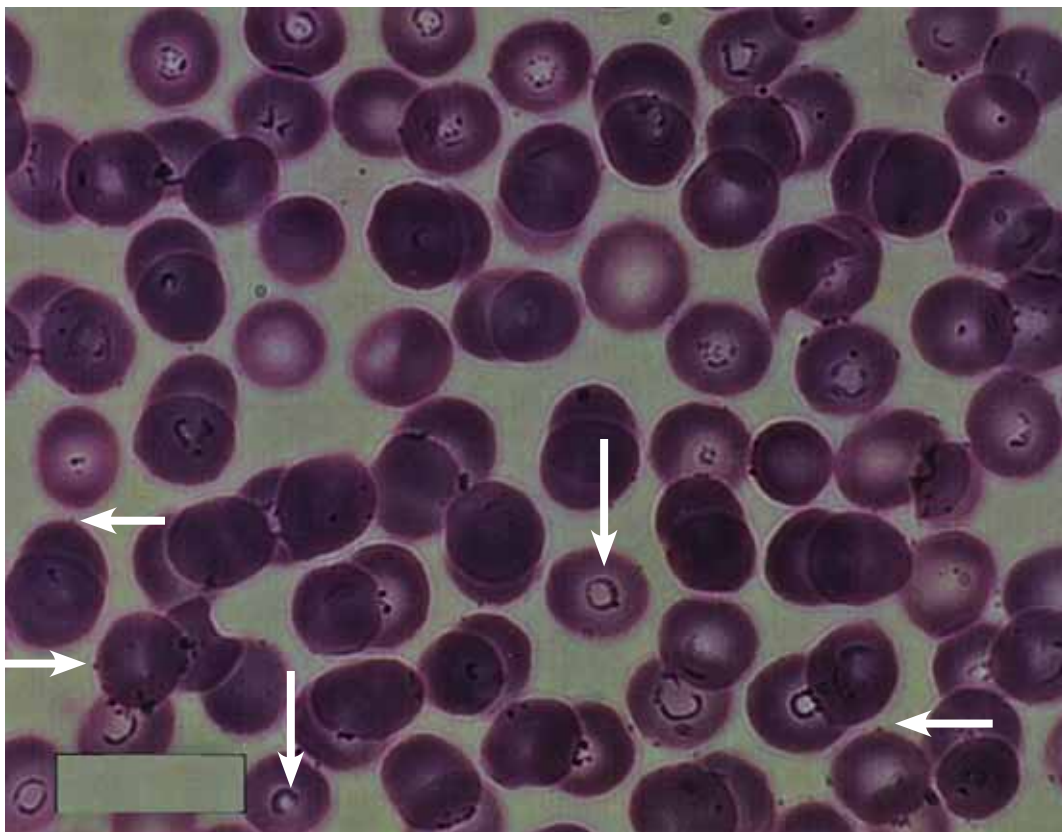
Babesia Forms or Platelets?

One serious problem in microscope examination is that some platelets look exactly like some forms of Babesia. Most parasite and hematology books do not even mention **extra-cellular Babesia**. Why they have this profound omission is a serious question.

It is utterly stunning to see how similar some platelets and Babesia forms can look -- utterly identical. Specifically, forms that are very small and have a dot in the center, resembling a **fried egg**, or those which contain a dot surrounded by **oval-shaped cytoplasm**, could either be a platelet (**involved in clotting**) or a form of Babesia.

I have met some microbiologists who doubted this, and when shown platelet images and parasite books with Babesia images, they were amazed. The problem is that few individuals doing microscopy own both a large collection of books with many platelet forms as well as many books showing Babesia forms. Most books offer 1-3 images of either platelets or Babesia, causing serious and routine errors in identification.

- a. Here is a fried egg pattern which appears to be sitting on the RBC. While Babesia is in this slide, we cannot say if this is Babesia or a platelet, and so we cannot use it to determine the contents of the slide.
- b. Here is an oval form attached to the outside of a RBC with cytoplasm around it. Since it is fairly large, and a few cells away is a large Babesia form, I would conclude that is a Babesia form. Further, its edges are very sharp. Most platelets do not have perfectly sharp edges.
- c. This oval with some dark material inside is not clear enough to define. Since it is **not a uniform color** I would propose it is more likely to be Babesia than Bartonella.
- d. This fried egg looking form with a dot surrounded by cytoplasm could be a platelet or Babesia. It is impossible to determine.
- e. This linear and large oval finding appears to have two parts. Is it two oval Bartonella bacteria? Is it two small Babesia forms? Is it two small platelets? It does not serve any purpose to guess even if one were 90% confident. And if you were confident, I could show you sample images from various books that look like the other two options you dismissed. This is a serious problem in microscopy of this kind. You have to look at 50 images of each of these three options to realize many options exist for what you see.



Some Complex Sides Have Clear Findings

The slide above shows a massive infection. I believe that these RBCs show many forms of Babesia which are classic shapes or patterns (shown with vertical arrows). I believe it also shows oval and round bacteria consistent with Bartonella (shown with horizontal arrows).

One goal of this book is to show you all the major forms of Babesia that seem to be well established and published in respected infection web sites, parasite textbooks and peer-reviewed papers.

Once you have been able to look at all these Babesia forms, which only exist in this publication, we will then have you look at slides yourself. We will see if you can identify Babesia on your own.

We have arranged for one CLIA approved lab, Fry Clinical Labs, to offer you two types of stained blood smears for \$350.00. With these colored and enlarged blood smears in hand you can use this book as a tool for screening blood samples. Health care professionals may even use the information in this book to look for the presence of Babesia. **We hope other labs will soon also offer this service.**

There exists a widespread misconception that blood smears are always carefully examined by workers. The unfortunate reality, however, is that some lab workers do not even use oil on the slide, making it impossible to examine at 1000x magnification. Some only look at the smear for 120 seconds. Others do not have access or use enlarging computer software, which can increase the slide images profoundly. The images in the previous pages, from Fry Clinical Labs, do not represent an image examined at 1000x. In order to see the extra detail necessary to identify Babesia or Bartonella, sometimes a 1000x must be digitally enlarged further.

In the back of this textbook is a form to submit to Fry Clinical Labs requesting that they look for exact and comprehensive Babesia forms. Since no single book has all Babesia forms, we want to make extra sure we ask to be shown every possible form of this life threatening illness.

I have taken the liberty of giving you a comprehensive list of possible Babesia forms to submit with your request forms.

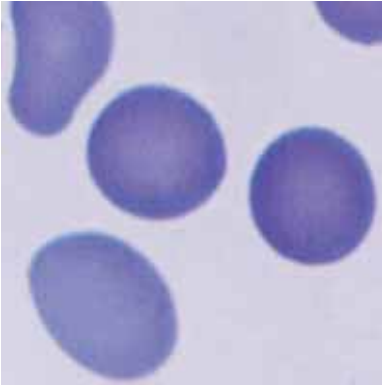
At the present time, Fry Clinical Labs offers two slide images for \$350.00, which will allow you to see your blood carefully stained by both Giemsa and the Fry stain. The latter is possibly the best chemical stain in the world at showing Bartonella forms. And the combination sometimes might show different aspects of Babesia and help you or your health care provider to see for yourselves whether or not you have Babesia.

In this book, I offer a massive collection of Babesia patterns and examples of each pattern, found in government slide collections, top parasite books, medical journals and hematology books, which contain blood smear images of Babesia. Most have very few images and this has led to many Babesia infections being routinely missed in clinical slide samples. Just

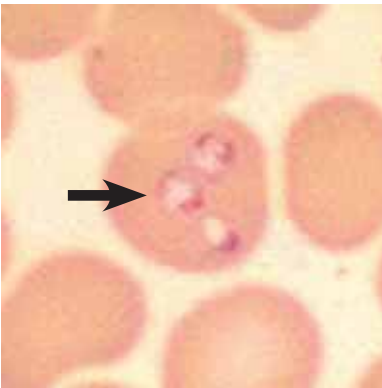
as it takes bank tellers a great amount of time with real money in hand to be able to identify counterfeit currency, it takes many images of Babesia to train the eye of the laboratory worker or aggressive motivated patient to see Babesia. Since I have spent the time learning various forms, I like reading my own patient slides.

Now you can look at blood stained and enlarged with two types of stains. They will be examined by a Fry microbiology tech, but this book will allow you also to look for yourself. No other lab sends you a copy of your stained blood smears with two stains, and showing two different fields.

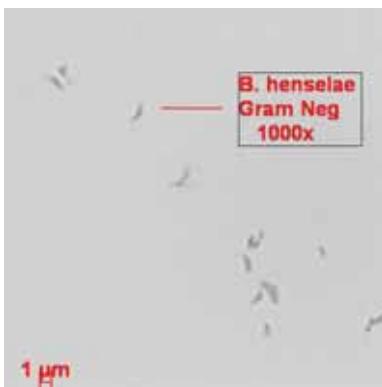
If you are health care worker (either in a lab or in clinical care), I hope you may find that this book improves your ability to diagnose Babesia.



Red Blood Cells are typically 6-9 micrometers. (Some disorders alter this size.)



Babesia form sizes are highly variable depending on the age of the form and what type of form. They are possibly 1/5 of a micron for tiny gametes or trophozoites, and perhaps 2 microns for common rings.



Bartonella are Bacteria.

Some Bartonella are oval and fairly large in an artificial lab culture. Some Bartonella may be well over 1 micron in size as noted in the lower left rule.



Another example of the use of a magnifying glass to help see Babesia in the RBCs or around the RCBs.

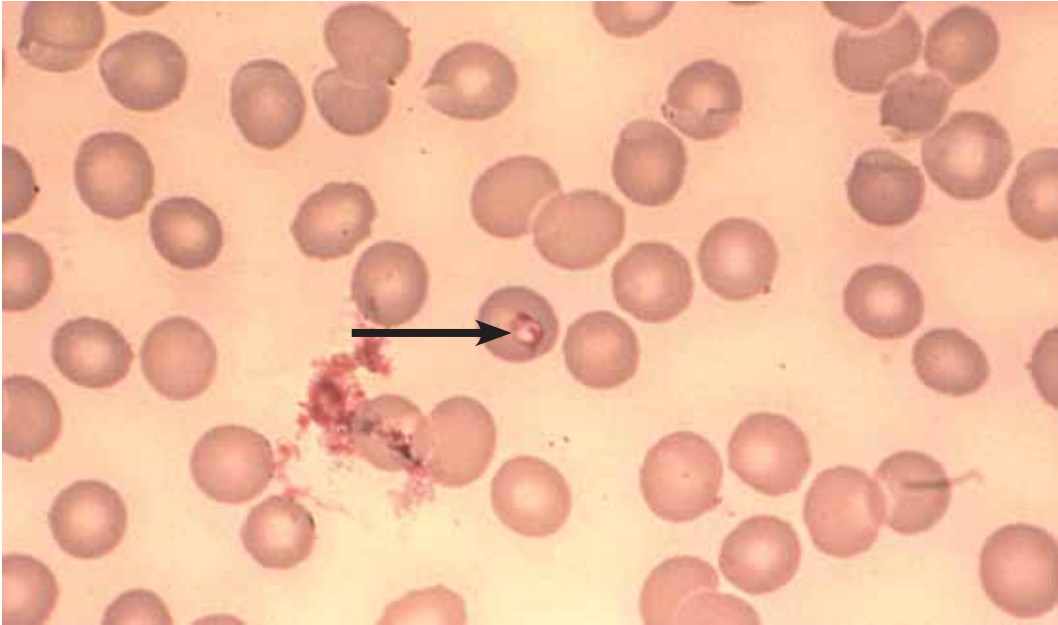
Babesia Images

from the Centers for Disease Control

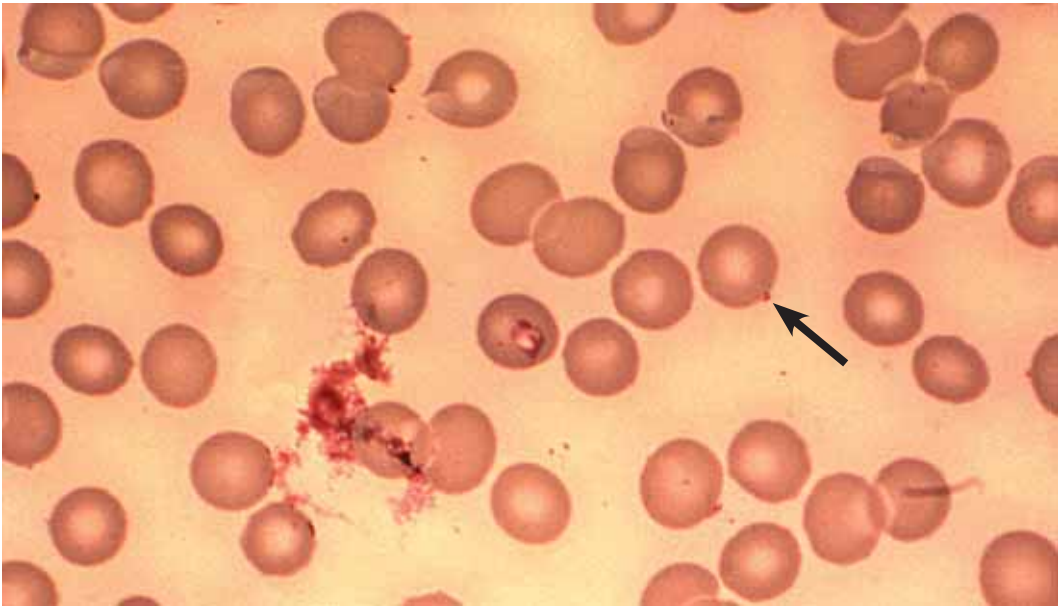
The majority of Babesia infected patients are not diagnosed, and most laboratories miss Babesia routinely. Because this is the case, I want to start by showing established government Babesia forms from a conservative and respected protozoa slide source, the Centers for Disease Control. I do not want patients or health care professionals feeling that the patterns being missed are merely from fringe labs, so we will start with **conservative Babesia pattern sources**.

However, one common problem with these slides and virtually every slide in the books and professional literature, **is the absence of arrows**. The slides merely report that it shows Babesia or Babesia samples. So one is sometimes left questioning whether the slide shows 2, 4 or 6 types of Babesia patterns. In this book, I have tried my best to read the images based on the sum total of what I have read in vast numbers of parasite and hematology books. But this is a problem and limits any book that lists Babesia, Bartonella or platelet slides.

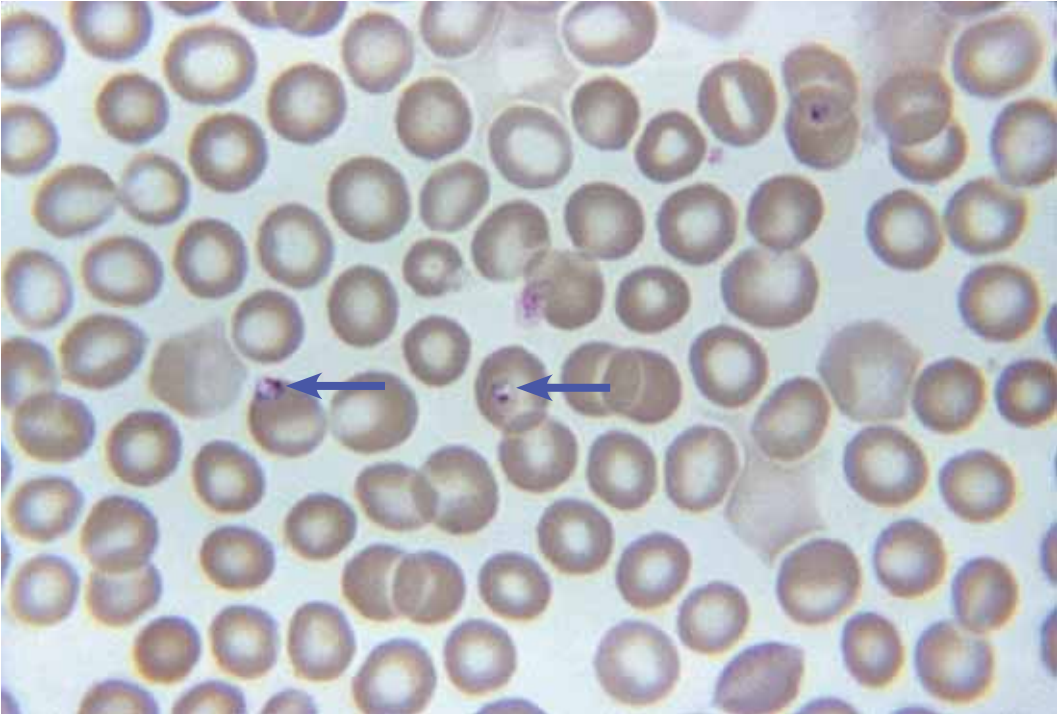Finally, it should be noted that almost all the arrows in these CDC slides are from me.



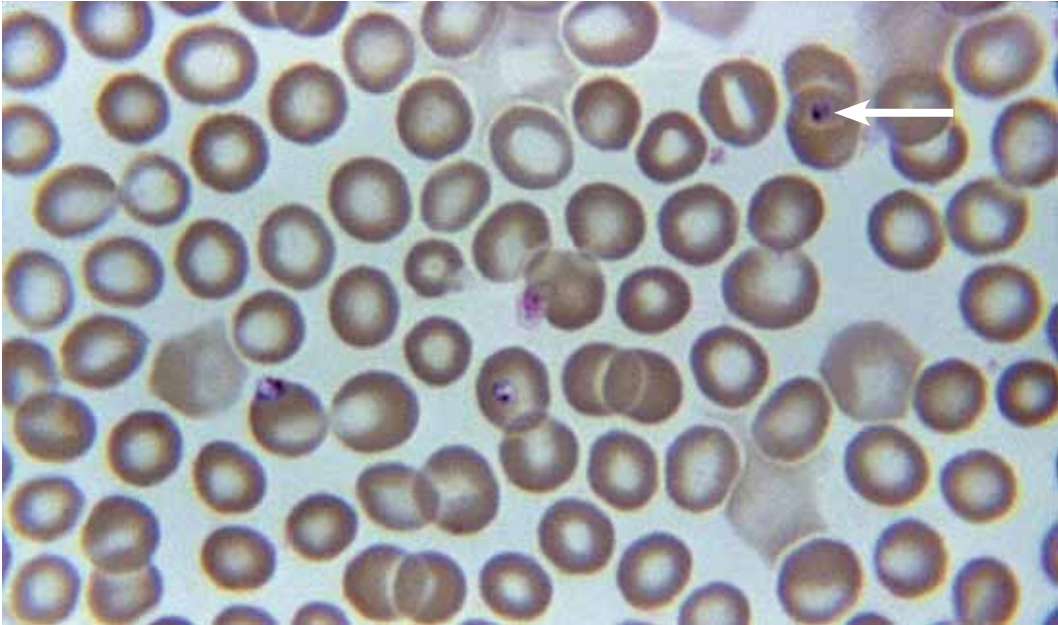
In this Giemsa stained slide, note the Babesia example.



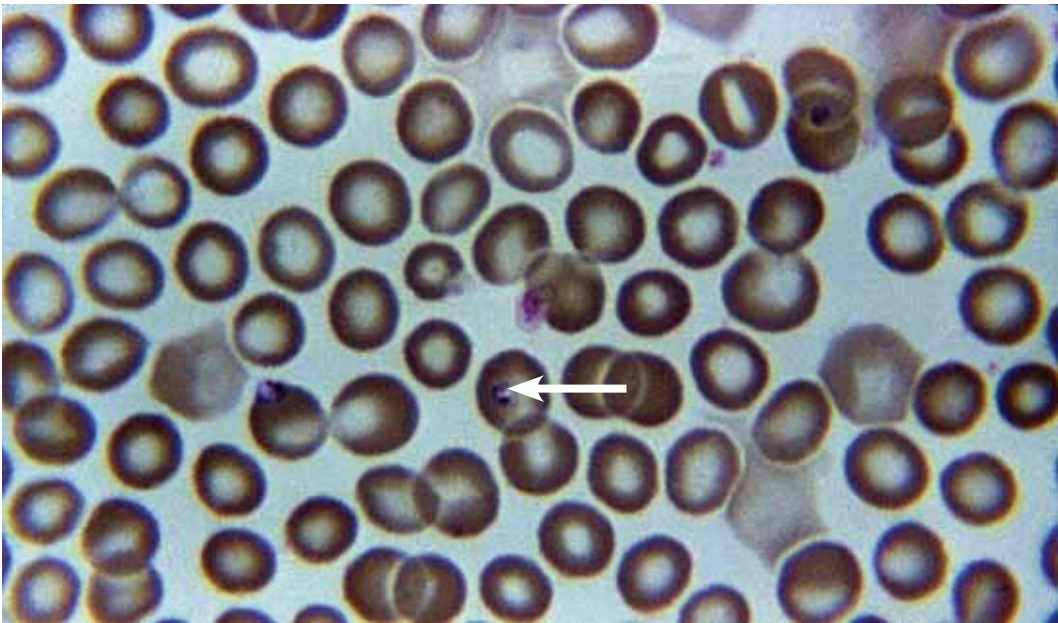
The slide above is shown darkened here to increase the vividness of a possible extracellular sporozoite Babesia pattern.



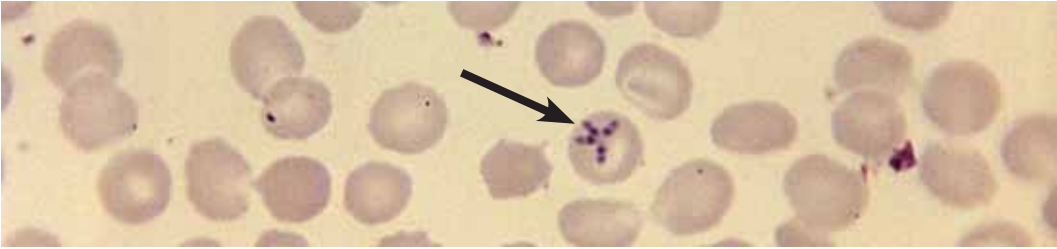
Though Babesia organisms resemble malaria, and both are parasites of red blood cells, these Babesia have unique features. For example, they vary a good deal in shape and size and they do not produce pigment. Because they do not produce pigment they may be harder to discover.



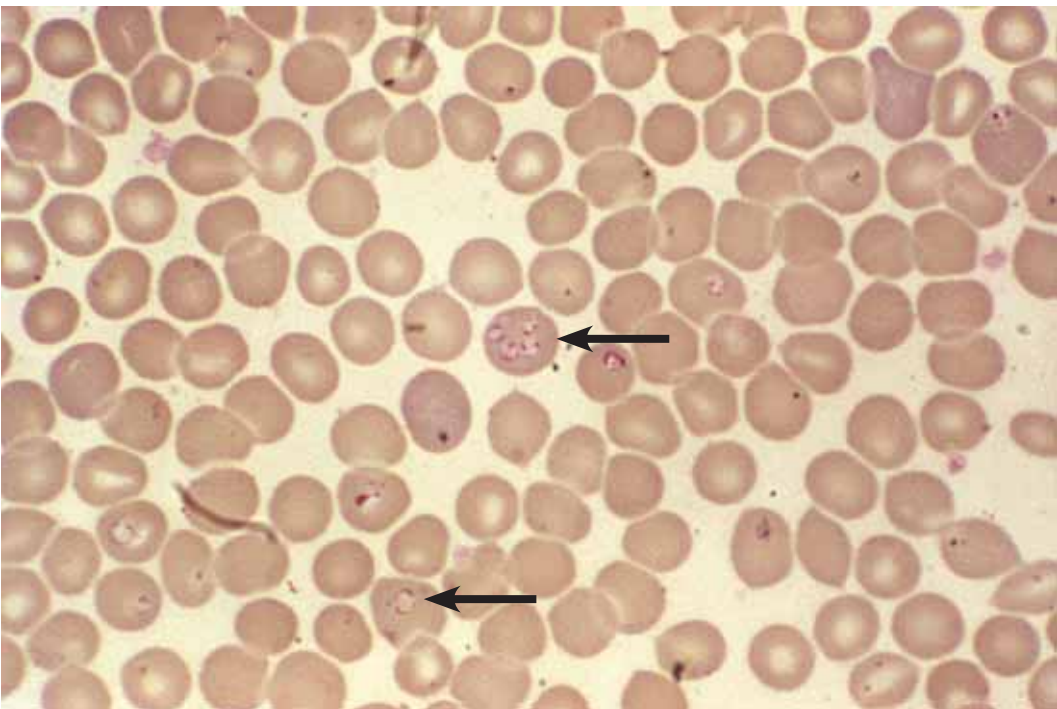
These Babesia images seem to show a good deal of pigment but it is only due to our enhanced shading. The arrow points to a **possible** Babesia pattern.



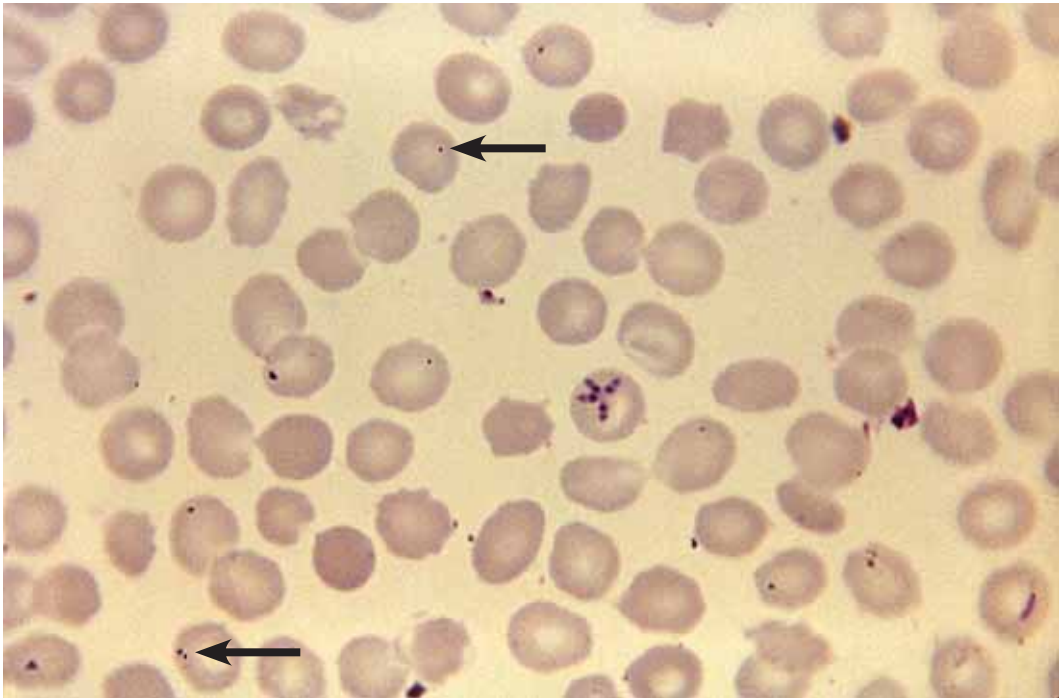This horizontal arrow shows a dense ring with thick DNA staining dark.



Note the classic but rare Babesia “tetrad” or “Maltese Cross.”



Babesia exists in many possible patterns as seen above and in the following images.

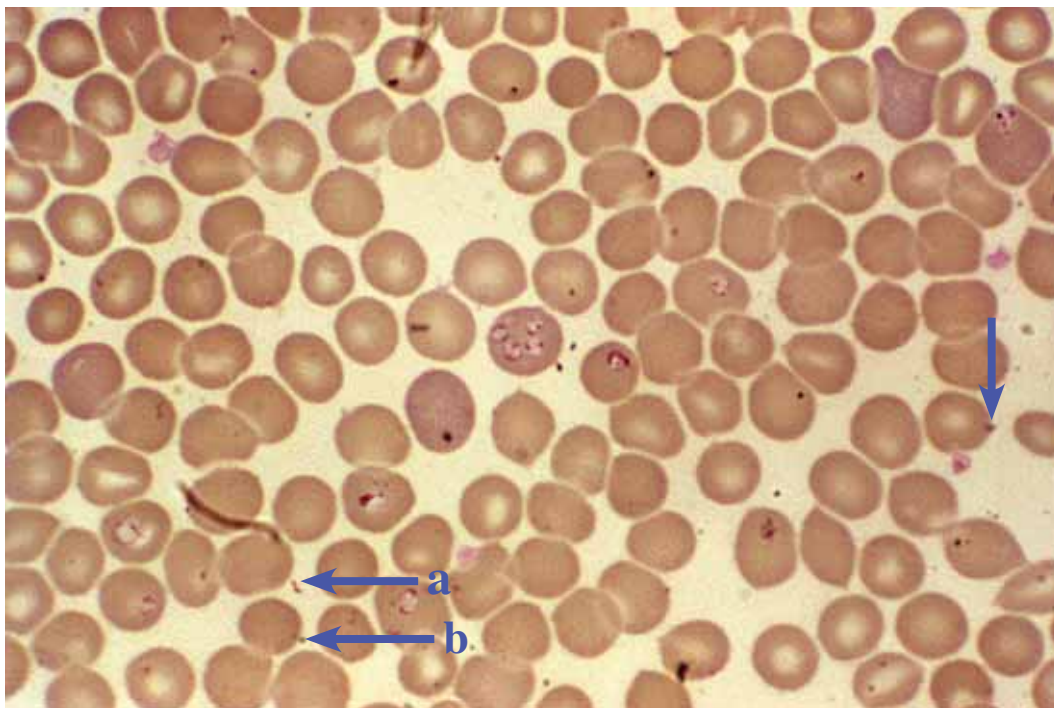


The top arrow shows a dot with clear cytoplasm around it which is found with Babesia and platelets. Most pictures of Bartonella do not have the bacteria surrounded with cytoplasm. However, I found one image that had a clear area around a Bartonella dot. My concern, however, remains with Babesia experts, who seem to know virtually nothing about Bartonella, and vice versa. So sometimes I wonder if they know what they are seeing. Further, few seem to realize that **many patients or animals with one infection can have the other**. And while some researchers perform additional testing in support of the presence of their infection of interest, all too often the “support test” does not address the presence of two to five other infections.

Further, if you stand back and look at this image in its totality, platelets appear to be present but are staining **with irregular edges**. And this slide is flooded with dark dots, dark ovals and dark dots with oval cytoplasm. Therefore I believe this slide shows a vast number of Babesia forms and possibly also some Bartonella forms. To be certain, we would need

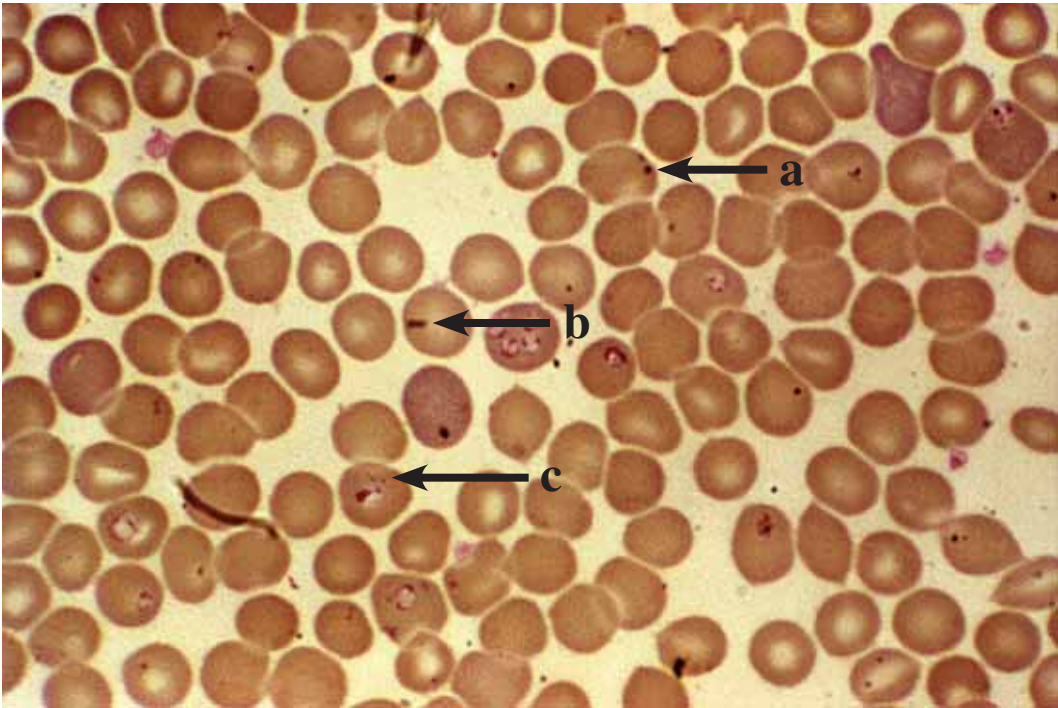
specialized testing such as levels of VEGF, ECP, TNF-a, IL-6, IL-1b and PCR and antibody tests at very high sensitivity. Many labs were found to have very meager PCR and antibody testing when secretly sent positive controls. Their error rate is a concern.

Therefore, learning how to use these other five highly effective, indirect blood tests can be very helpful. In addition, learning the possible 40 physical exam findings found with Bartonella and illustrated in my two part color atlas may also be of use.



In this important slide we see that Babesia can be found outside RBCs as well as on the outer edge of RBCs. In the vertical arrow on the far right one sees Babesia or a platelet with a small amount of oval cytoplasm, which could easily be confused with Bartonella. Yet, while Babesia can be a mere dot with no cytoplasm, and sometimes look like Bartonella bacteria attached to the RBC, Bartonella probably rarely has clear cytoplasm with a dot. And if Bartonella has visible cytoplasm it is likely to require massive magnification to see.

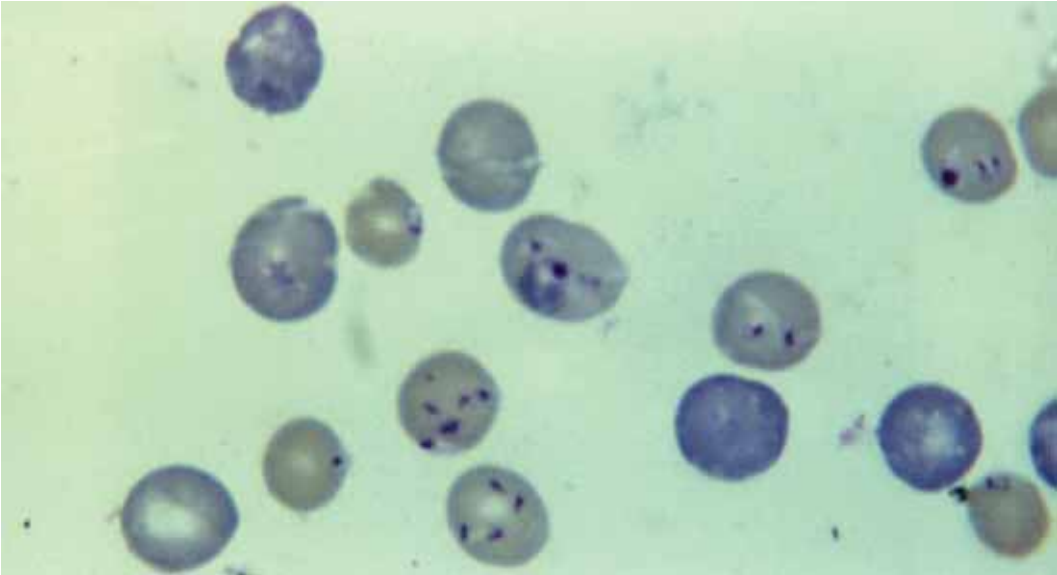
The arrow in the sample labeled “a” points to a **possible** free Babesia form outside of the RBCs. Because it is so markedly thin I doubt it is a platelet (but this is not a certain reading). The lower horizontal arrow marked as “b” is probably a Bartonella bacteria.



This slide shows a massive Babesia infection and Babesia in a vast number of forms.

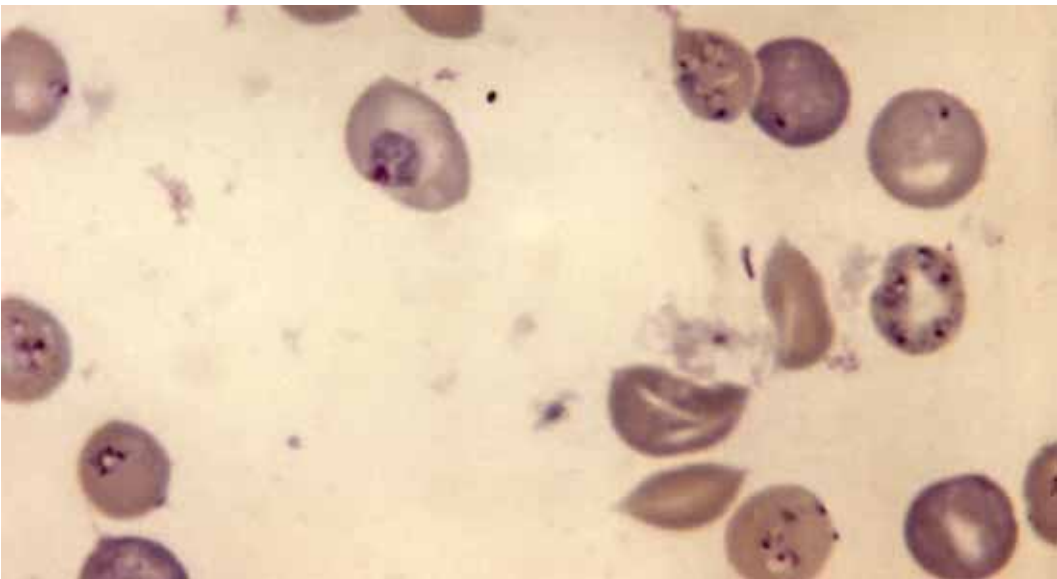
- a. Here are two large chromatin dots inside or on the outer edge of the RBC. I do not believe them to be Bartonella bacteria due to their enlargement when compared to other, much smaller dots attached to the outer edge of some red blood cells.
- b. I believe this is a double Babesia form linked together, so that it looks like a couple of dark pearls. The large and wide size of these paired dots, in my opinion, indicate Babesia. While it is possible this is a new red blood cell marking, i.e., a reticulocyte, I doubt this option because the cells on the slide appear to all be generally normal, and it is hard to see other clear and certain reticulocytes. Further, dark reticulocyte markings generally do not appear as perfectly oval dots side by side.
- c. This Babesia form has triple oval dots with **tiny top regions with clear cytoplasm**, and which together also look like a face, as well as possibly a fourth tear drop form at the 8 o'clock position. As

you can see, any book or article that only lists grossly obvious ring forms or the cross pattern is missing a great deal of Babesia case, and the fact is, these slides are from a conservative source, the CDC — hardly an experimental source.



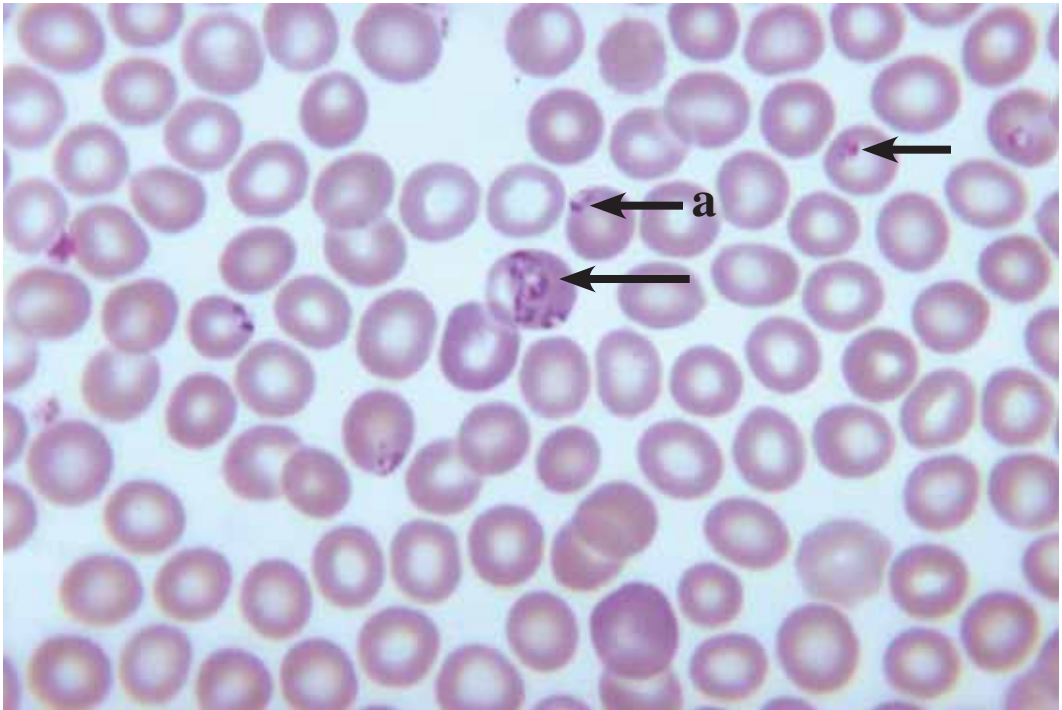
These Giemsa stained red blood cells, taken from a hamster, contain **both** *Babesia microti* and *Plasmodium* (malaria).

Babesia is easily and routinely confused with malaria. More than 100 *Babesia* species have been reported. **Most labs test for two species.**

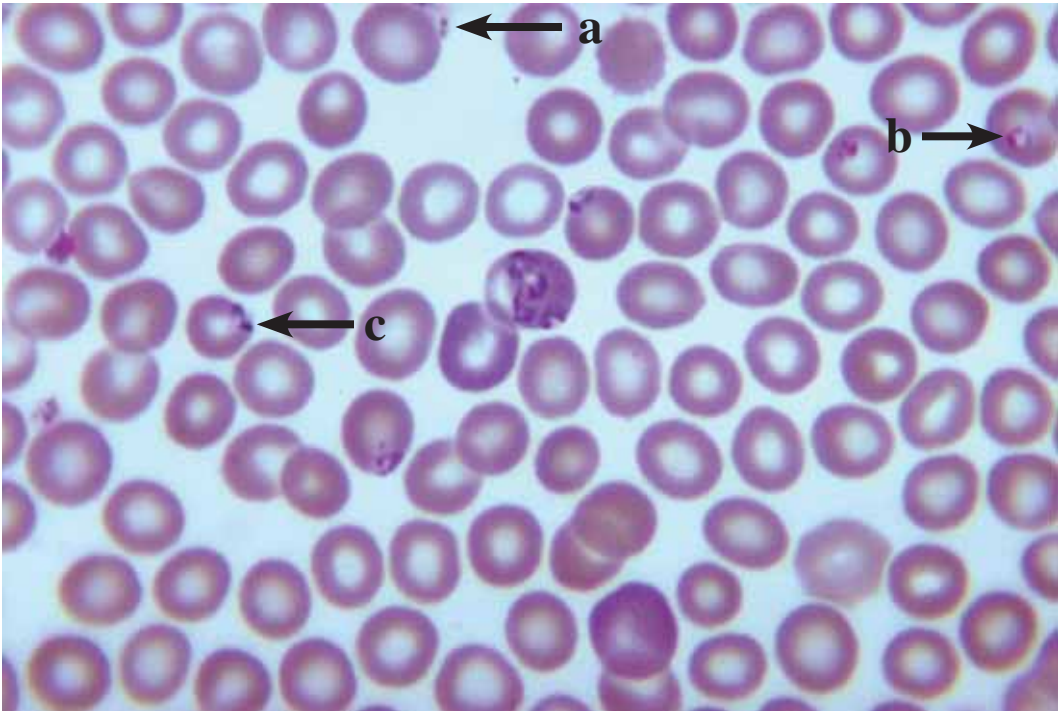


A final image with *Babesia* and malaria in the same animal. Young forms of malaria can sometimes look very similar to *Babesia*.

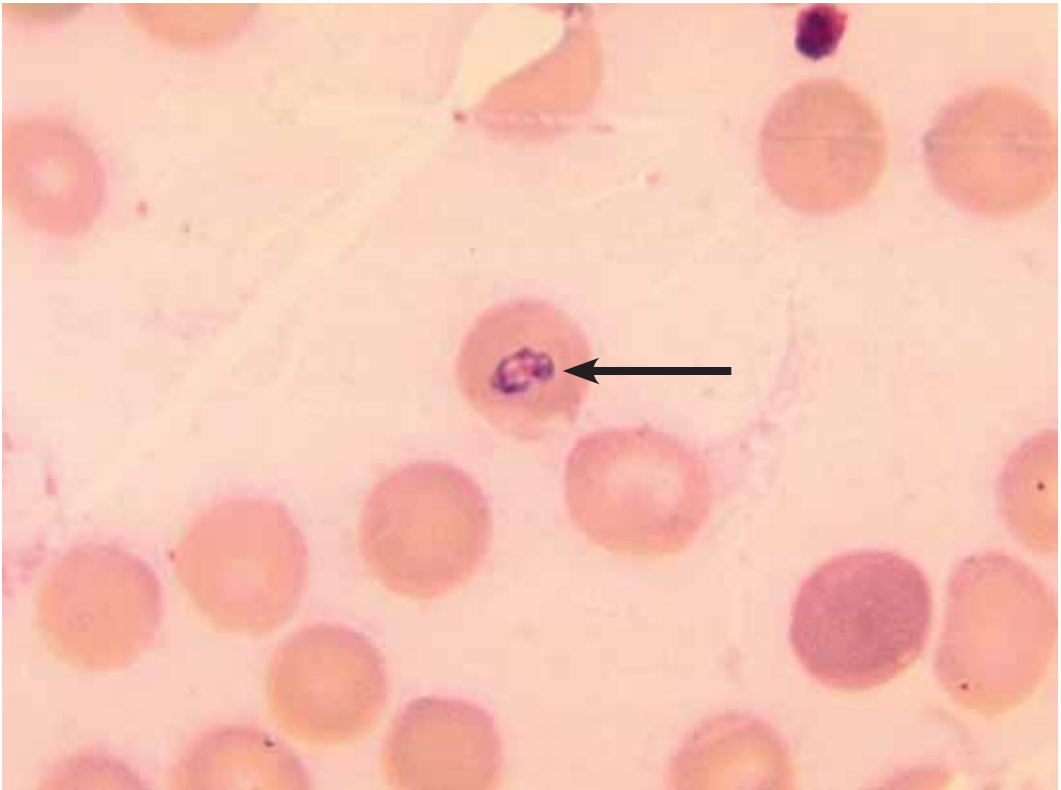
These RBCs are magnified 1125x.



Babesia rings and other forms within RBCs. Note the Babesia form marked with an a., which appears as a thick long worm-like clear shape with a dark end. This is, indeed, an important and unique Babesia presentation. It would easily be missed with low magnification, fair staining and a mere 120 second standard manual examination.



- a. Perhaps a clump of platelets.
- b. This is a basic small ring form. If the staining is too light, these can be missed.
- c. Two likely oval shaped Babesia forms with obvious cytoplasm around them.



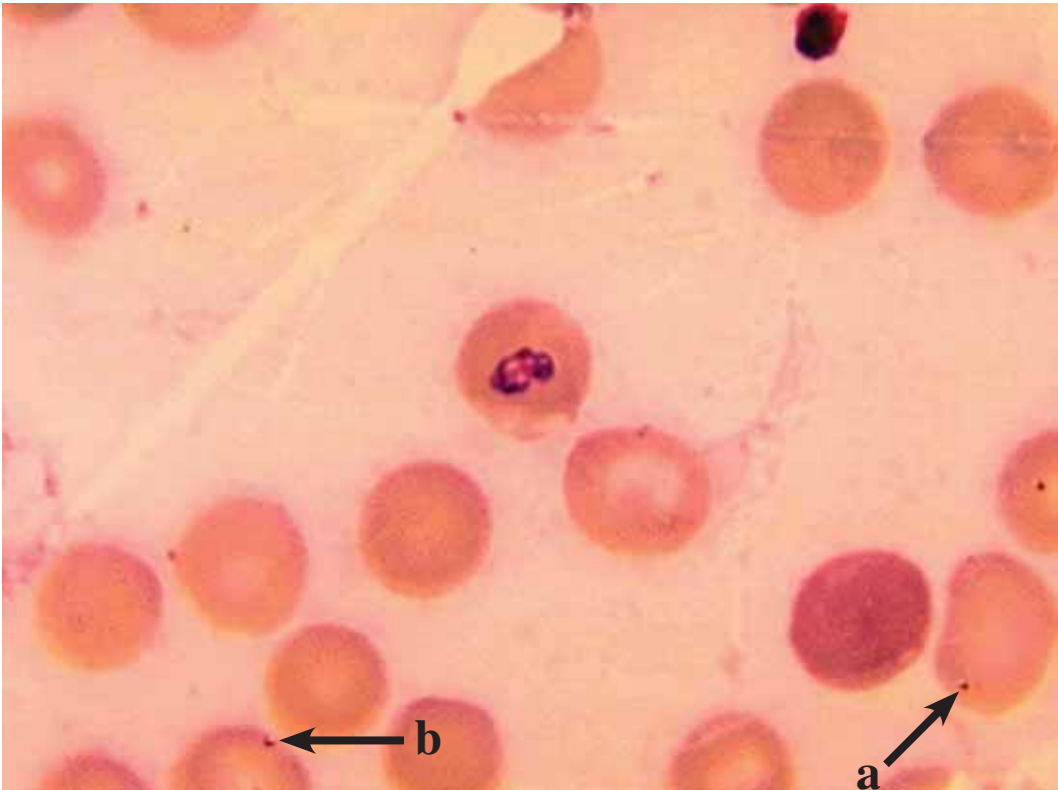
Blood smear showing larger trophic stage of *Babesia microti* in a red blood cell.

Babesia parasites look like **early** and immature malaria parasites. Perhaps that is why they are routinely missed. They do not have the highly dramatic forms found in maturing malaria infections.

Trophozoites in malaria are generally ring shaped and 1-2 microns in size, although other forms (ameboid and band) may also exist. Healthy red blood cells are usually about 6-9 microns in size.

The trophozoites are inside the RBCs and divide by **binary fission**, producing merozoites, which are sometimes outside the RBCs looking to infect additional erythrocytes and reinitiate the replicative cycle.

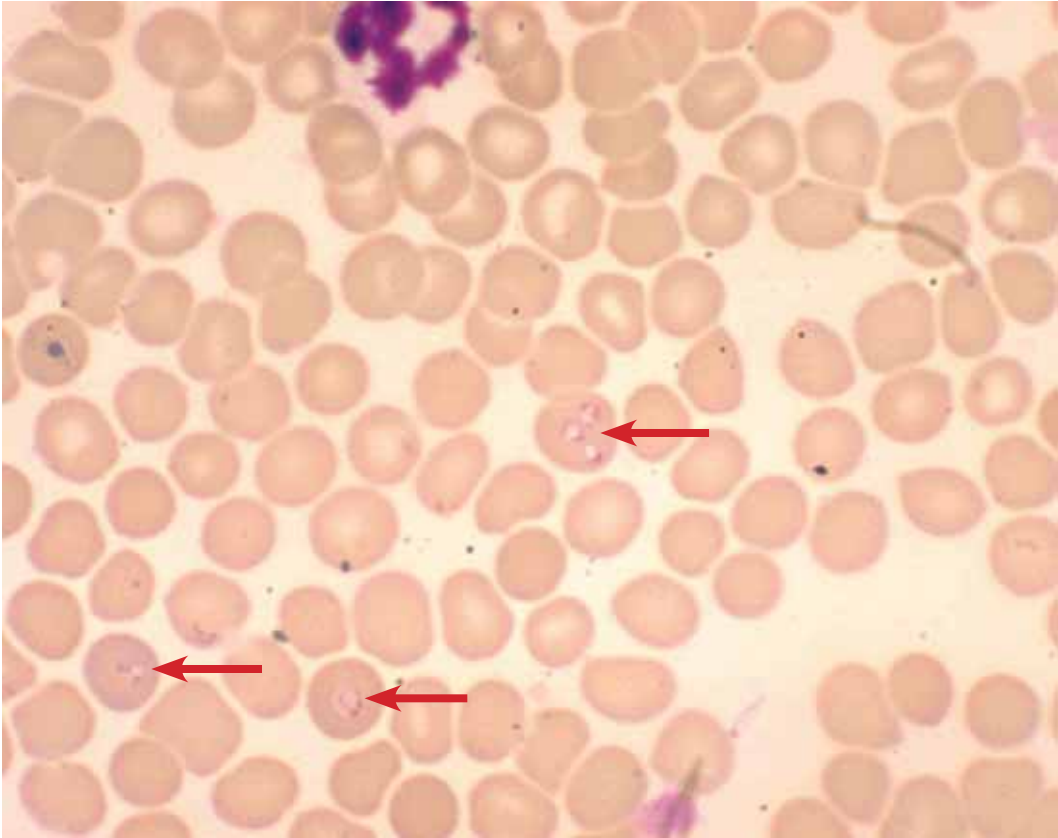
This sample looks like it is ready to split from a trophic form into two merozoites, which can then go out and infect other RBCs.



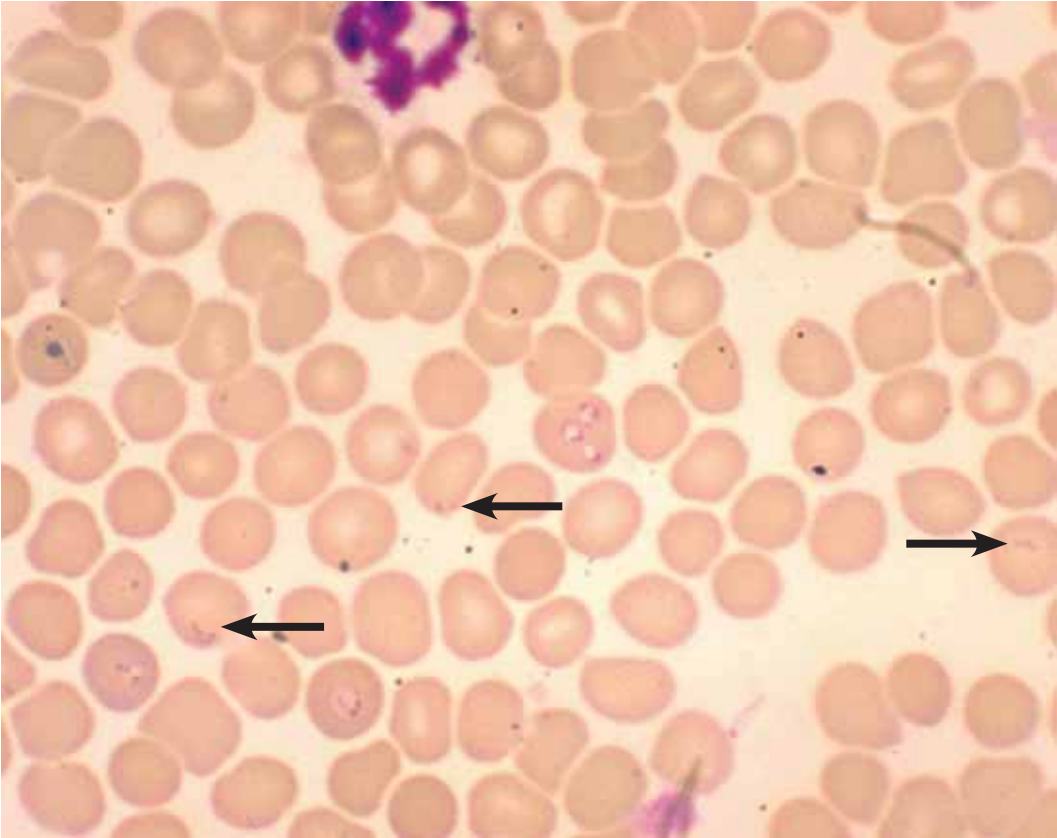
The addition of a little more stain allows for Babesia forms that were otherwise unnoticeable to jump out of the slide.

The additional “stain” in this sample was merely a slight photo darkening.

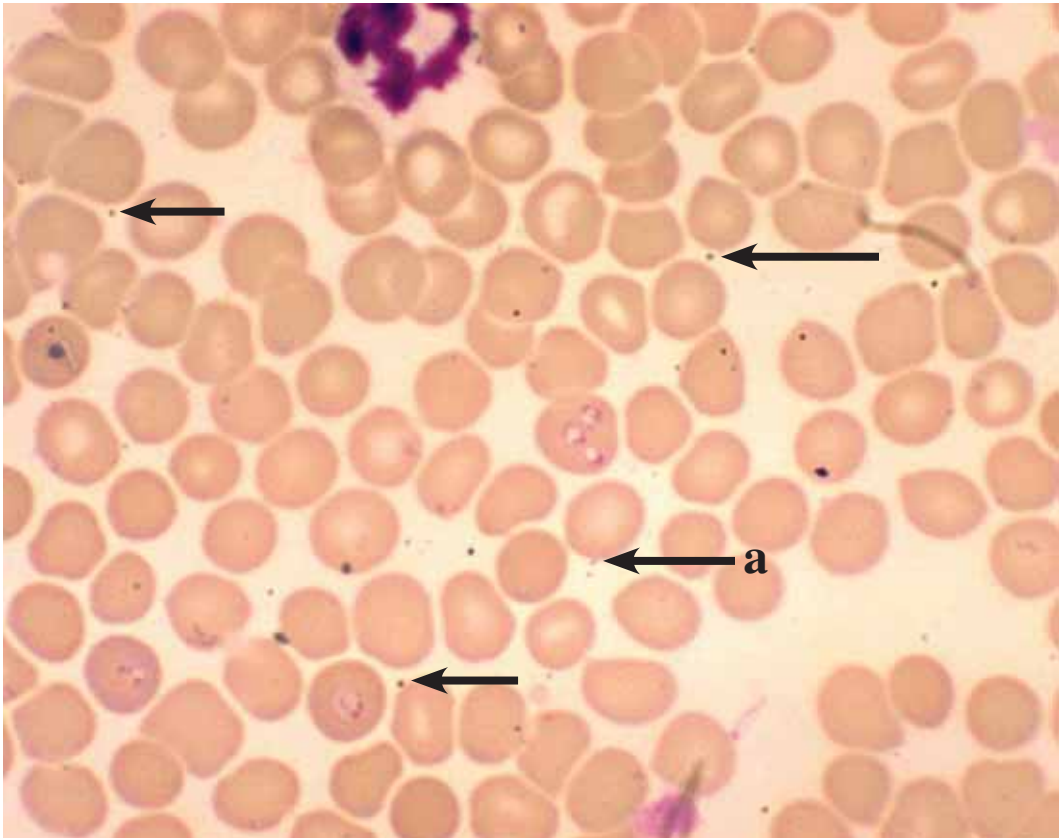
- a. This oval dark chromatin dot has tear drop shaped cytoplasm, which might be Babesia.
- b This possible tiny Babesia ring shape is half dark chromatin and half thin, white cytoplasm-filled ring.



Babesia ring forms have every imaginable form. Notice that no ring form looks the same.

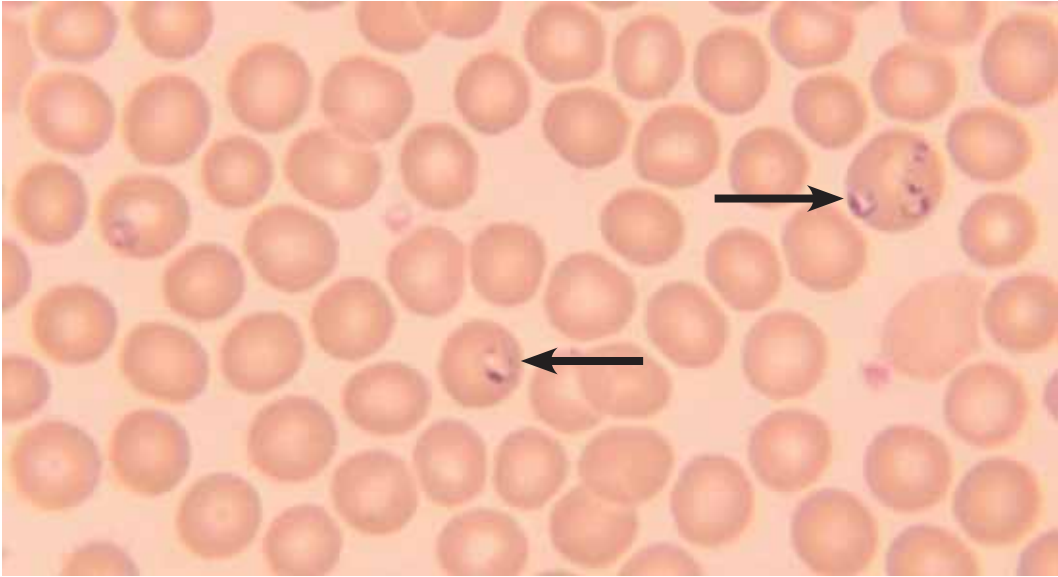


Additional possible Babesia forms or small platelets shown which are more than simple rings.

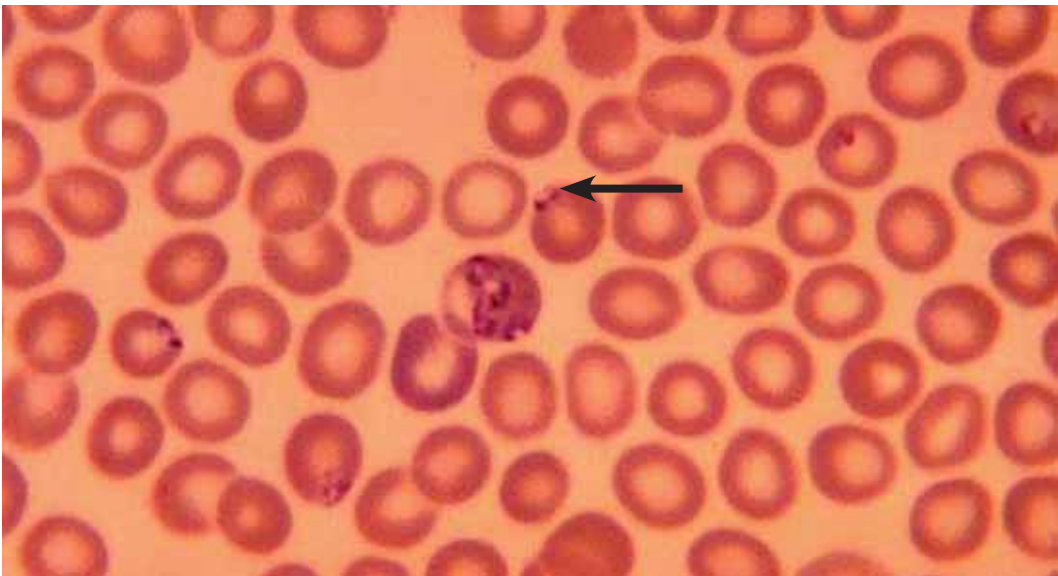


Possible Babesia forms **outside** red blood cells or merely touching the erythrocytes (RBCs).

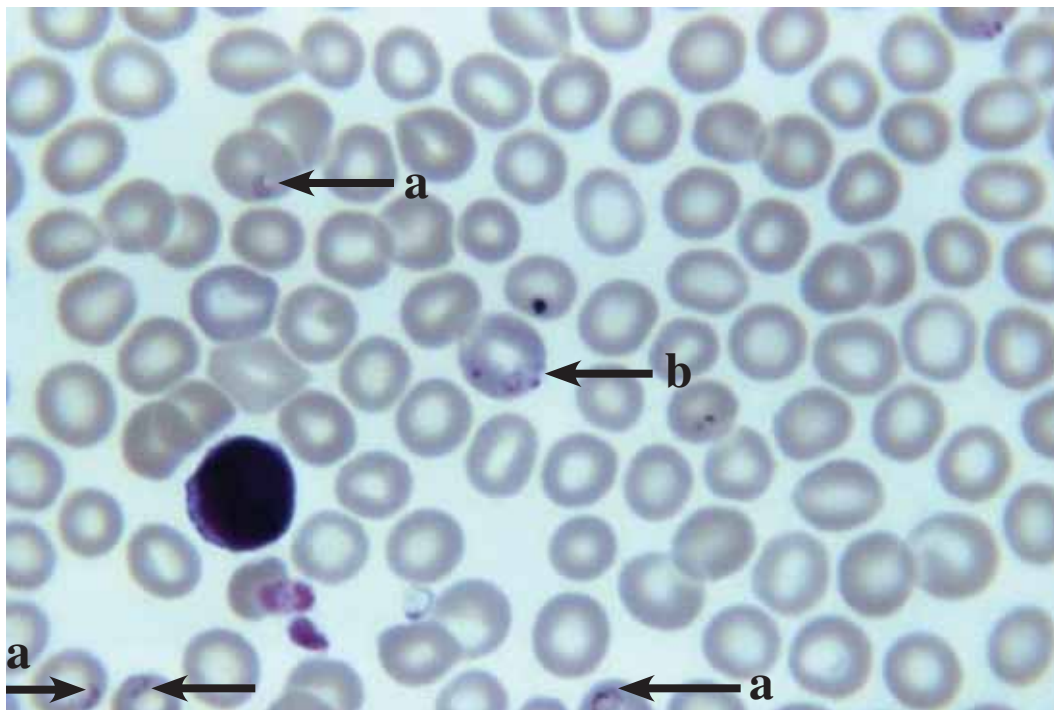
It is possible that some of these dots are Bartonella (see a.), while others may only be platelets. Certain Babesia forms can be used to help in examining the rest of the cell. For example, since **Babesia generally reduces platelets**, would it be reasonable to expect a Babesia infested slide to have a small number of free floating forms or to have a massive number of platelets bathing the RBCs as free floating dots?



Blood smear showing many moderate sized Babesia rings in erythrocytes.



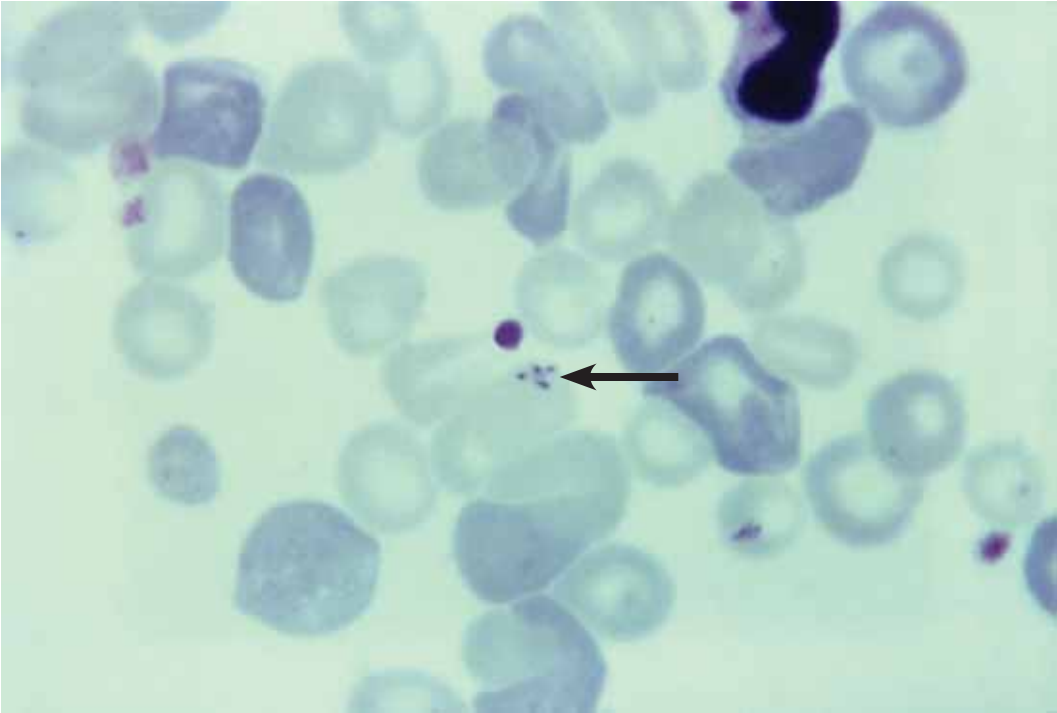
Babesia on the farthest outer edge of an RBC. If this cell was not enlarged and the stain was not dark, it would be missed.



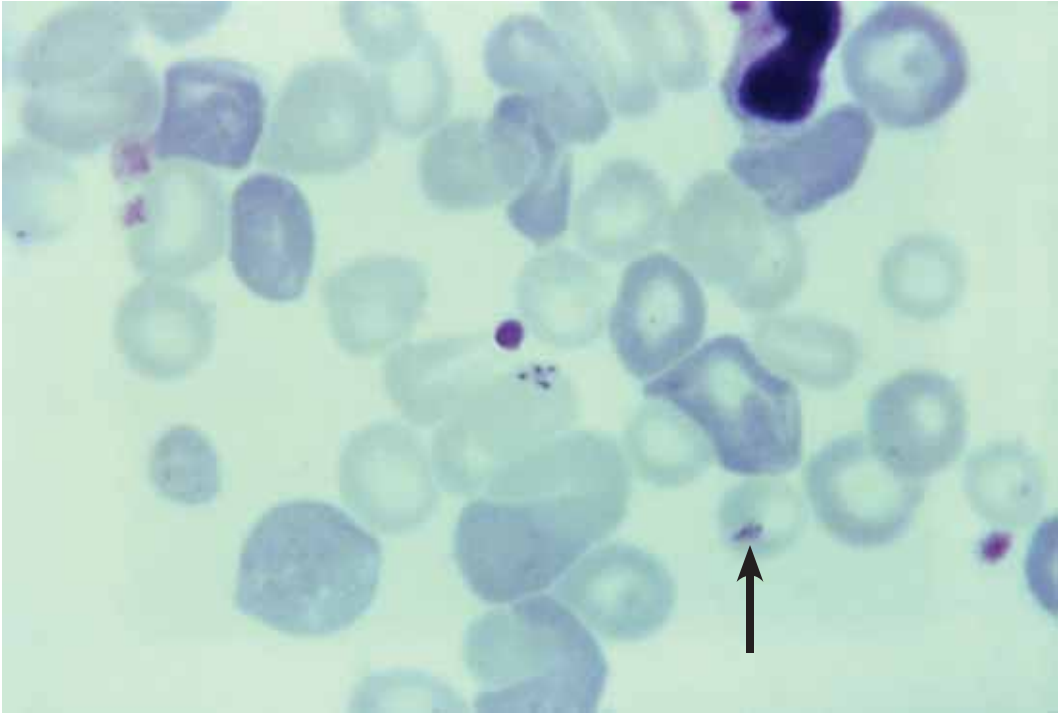
This blood smear reveals Babesia patterns inside erythrocytes. Note that no ring looks like another ring. This means the viewer has to be very careful. Three forms look like crescent forms (a).

The form marked as (b) has various names depending on the source. Are these single merozoites? Are they trophozoites? Are they sporozoites?

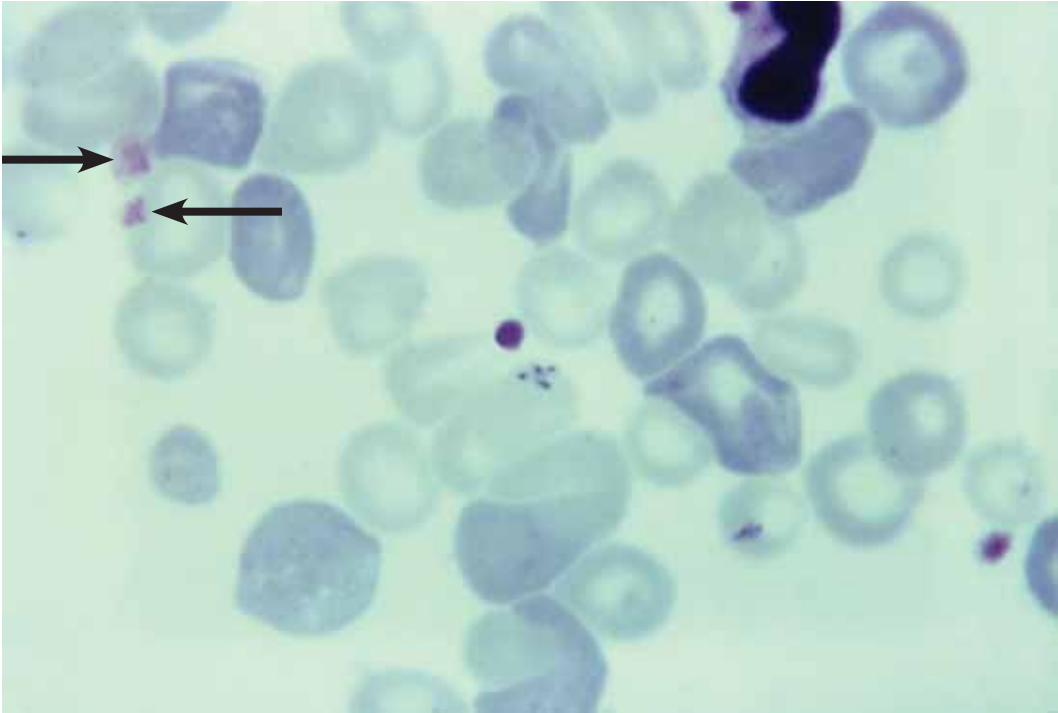
In the end, it **does not** matter to our purpose in this book. This is not a book about nomenclature. It is a book meant to cure the limited ability of most labs to identify Babesia. And these are clearly Babesia.



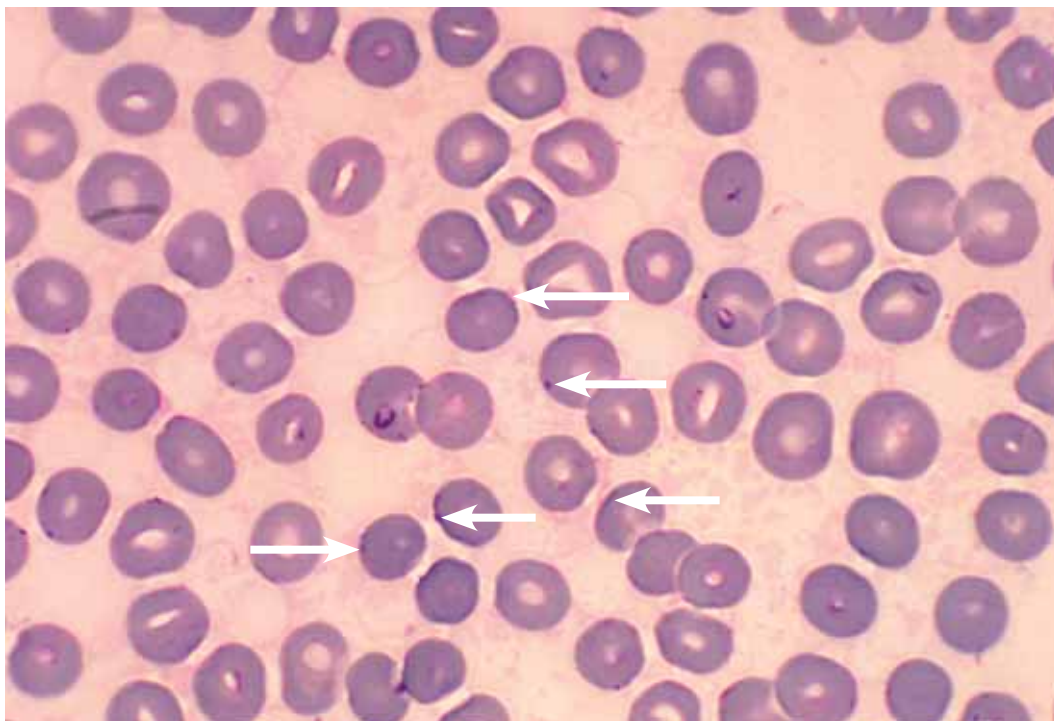
This blood smear reveals a Babesia tetrad formation which is also called a “maltese cross” pattern. It is rare and is hard to find on blood smears. It represents four Babesia infectious particles. I am not aware of any other infectious agent in the world that makes this pattern. **Yet, I am very concerned that some huge parasite or hematology books offer this form in their one to three sample Babesia slides as if it is common.**



This oval form has two chromatin dots and might be considered a flat ring form. Yet it also looks like an oval merozoite form. But again, the only final issue is that it is a Babesia parasite.

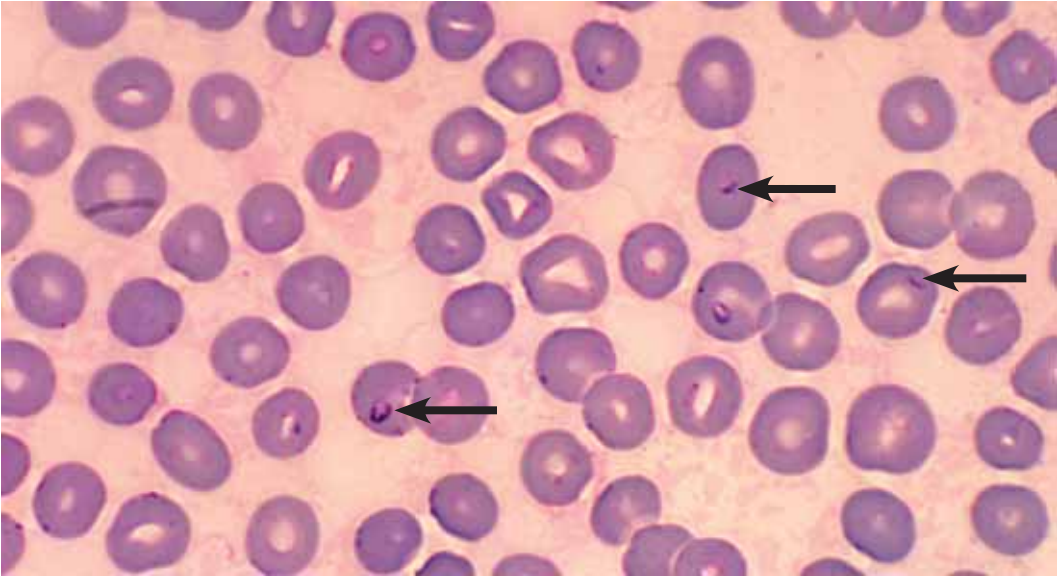


These two forms are very complex and might be called ‘grape clusters.’ They have a loosely rectangle shape or zigzag shape. Further, they also have a very irregular edge. It is also more likely they are a cluster of platelets, particularly because the Babesia forms in this slide do not look this way, and they are clumped outside of the RBCs.

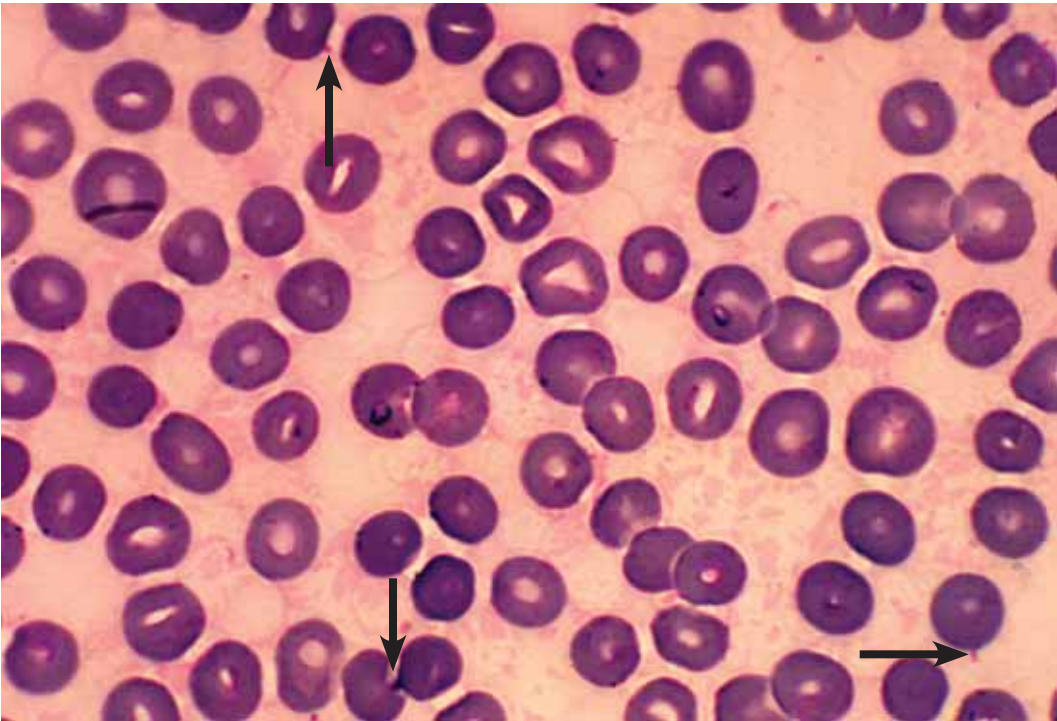


Babesia microti in blood smear. Giemsa stain. But which of these many forms are *Babesia*? The arrows are my insertion.

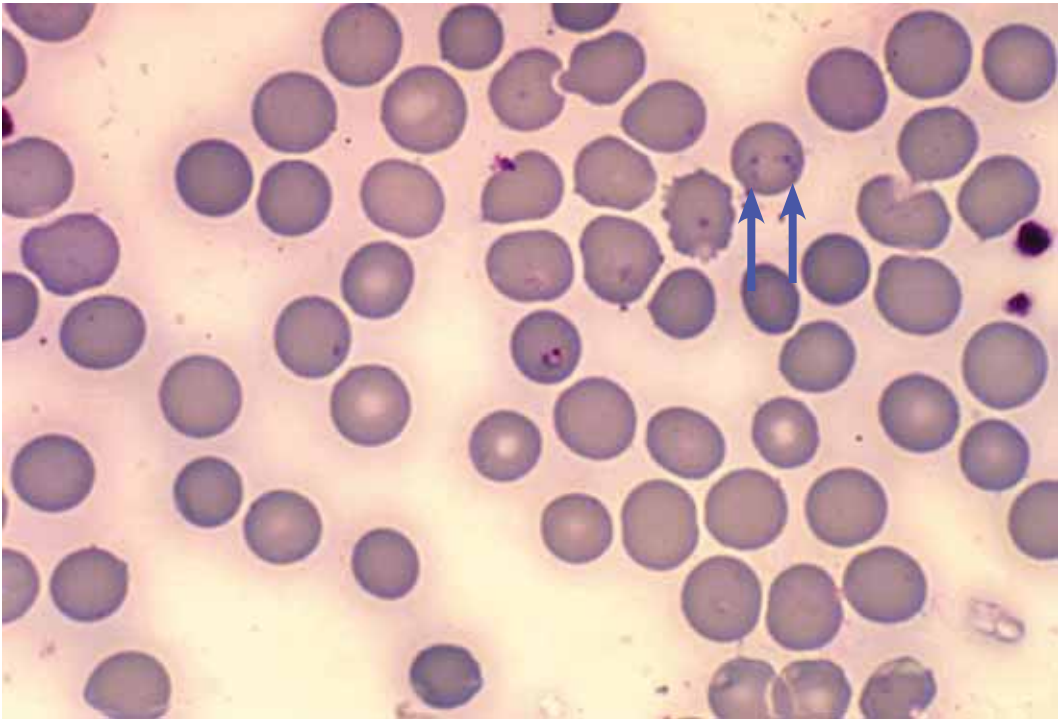
A large number of *Babesia* are marked along the outer edge of various red blood cells. Some have one or more chromatin dots and others appear as smooth lines. **I believe the lines with dots are certain *Babesia*.** However, one must be careful when examining the smoother oval forms, since *Bartonella* might also have this presentation.



A number of crescent forms with different locations in various RBCs.

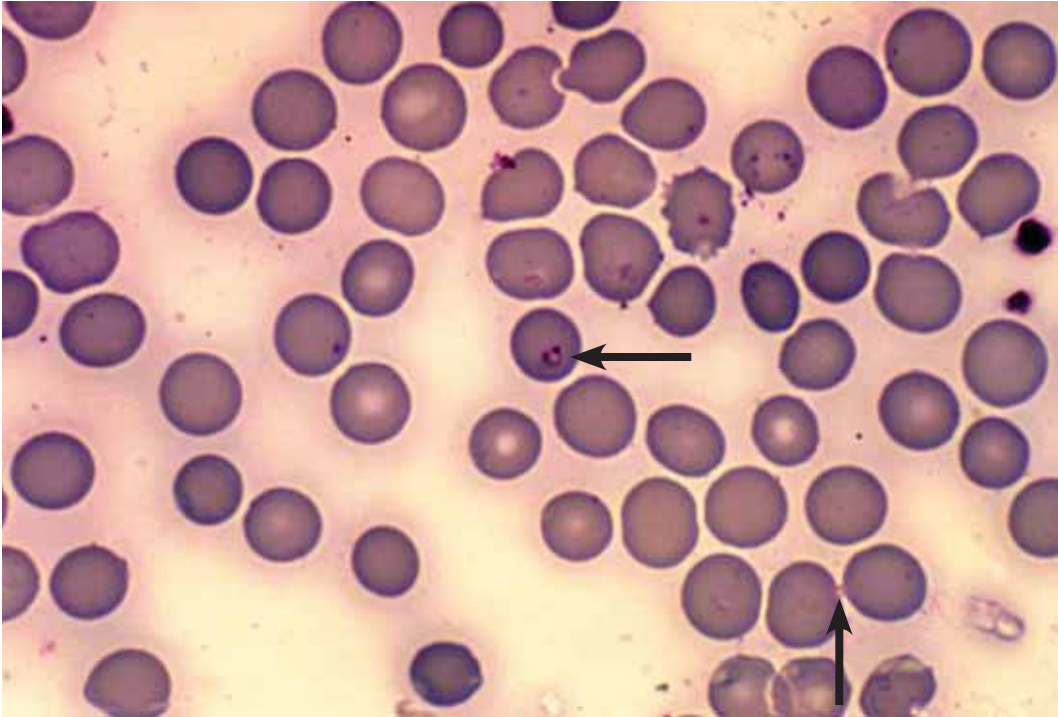

Three possible Babesia protrusions are marked with arrows. While these certainly could be normal RBC variations or platelets, I do not see many platelet forms in the slide that appear this way with these shapes.



Two vertical arrows point to two different appearing Babesia. The parasite on the right looks like a bead on a string. The floating platelets in this slide generally do not seem to have this appearance so I would say these are Babesia forms and not platelets.

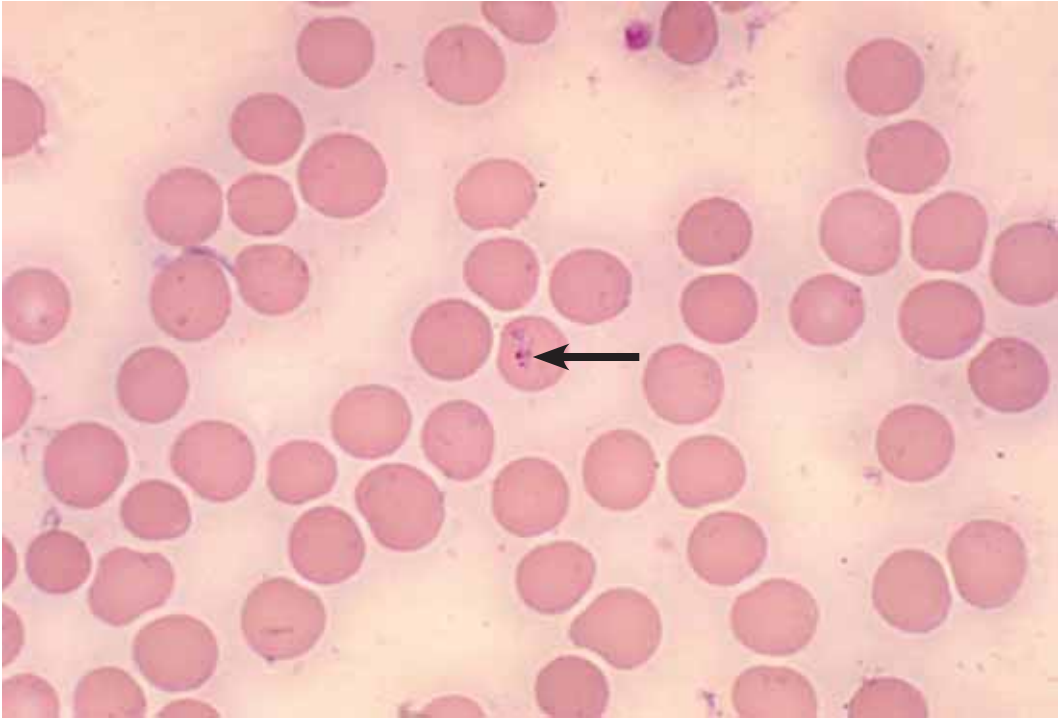
I do feel these forms marked with the arrows are not Howell-Jolly bodies because they have a winged component and are not tight dark circles associated with anemias, Thalassemia, or the removal of the spleen. In this context it is useful also to look at the red blood cells. Are they normal in shape? Pigment and size? These seem normal.



Head phone or earmuff Babesia pattern is marked with a **horizontal** arrow.

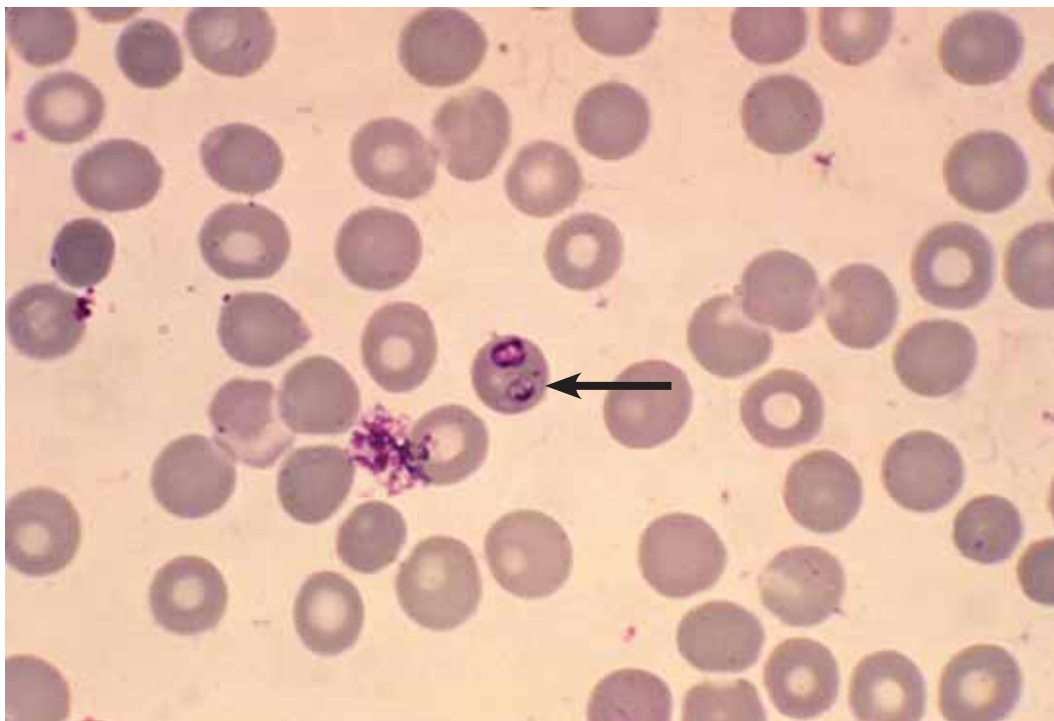
A **vertical** arrow points to a tiny Babesia form or platelet seen between two RBCs with a tiny chromatin dot at the top. This shows yet again that Babesia can be outside of RBCs. It has very sharp edges along the entire oval form which I believe is usually more consistent with Babesia.

This darker imaging or shading causes many possible Babesia forms to emerge.

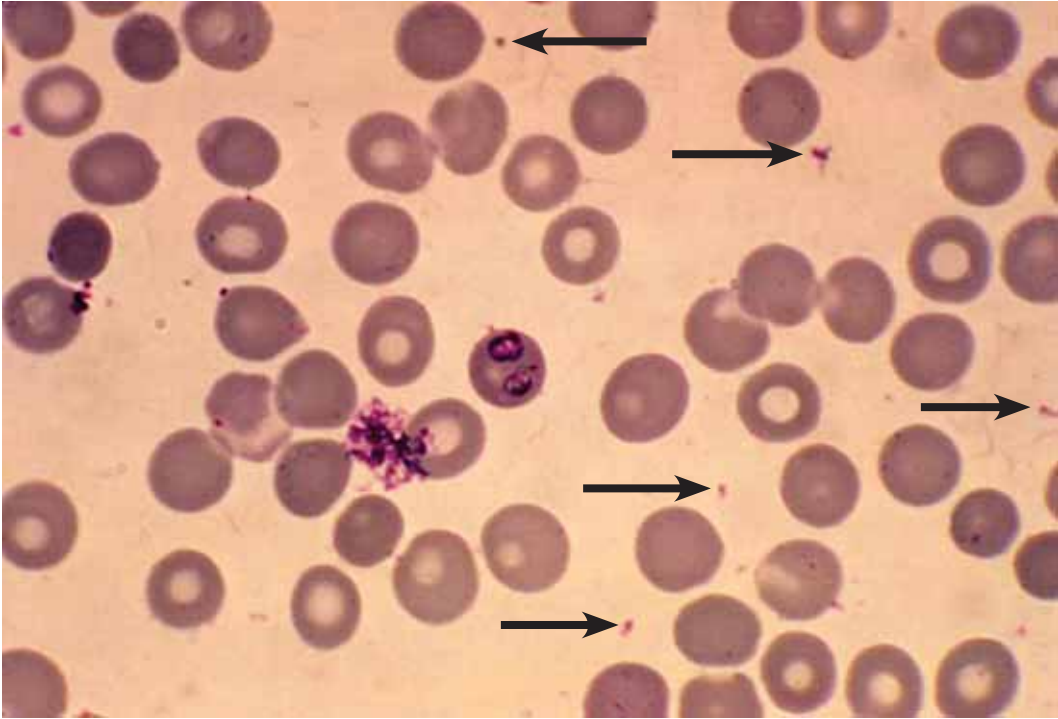


The CDC reports this is *Babesia microti* in a blood smear. Giemsa stain.

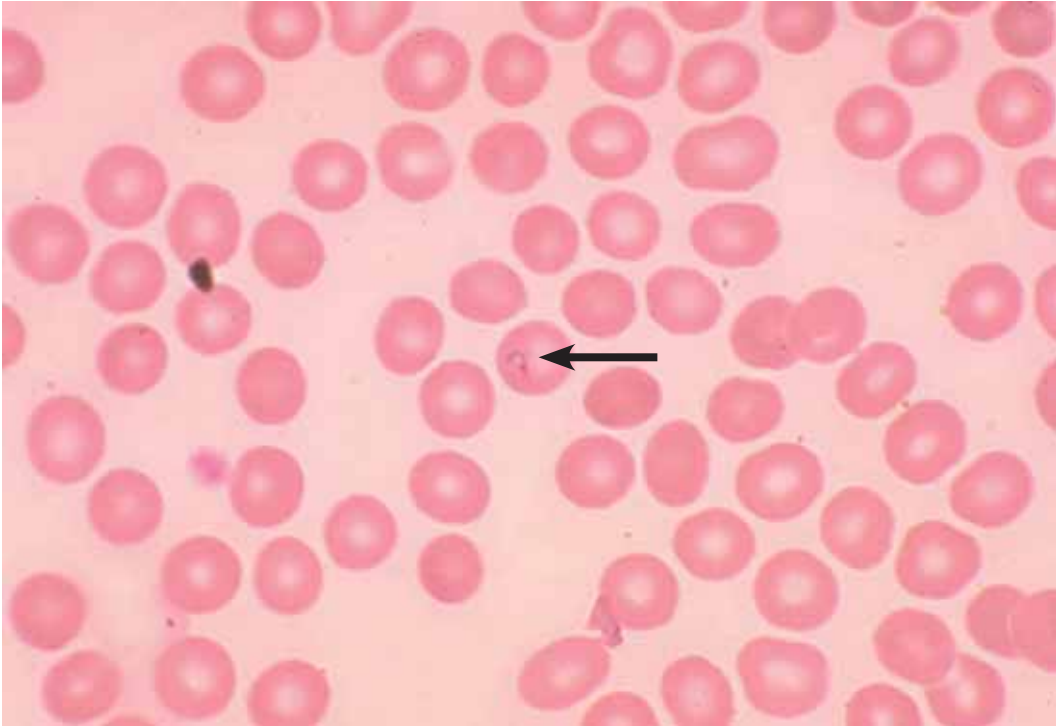
The central marked cell has three dots and a body going vertically upwards. I have not seen this CDC Babesia published form presented in any quality parasite or hematology textbook.



The arrow points to two sets of Babesia forms fused together. These have many possible names depending on the source, e.g. “zygote.”

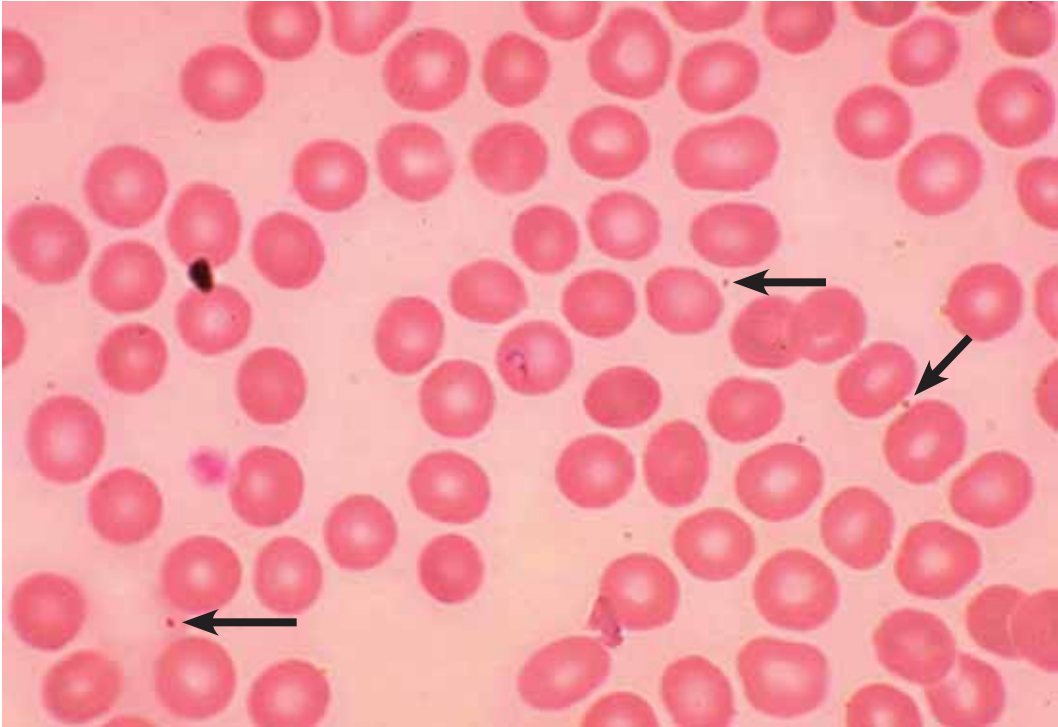


These arrows point to platelets or possible extra-cellular Babesia forms which float outside the RBCs. I would suggest that **both** Babesia forms and platelets might be present. I am not certain.

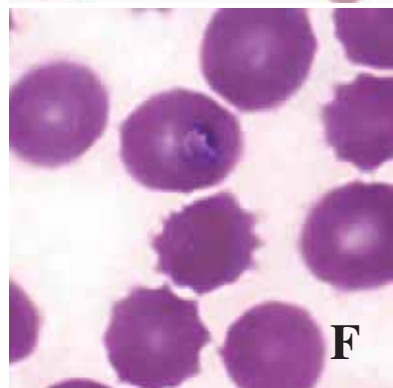
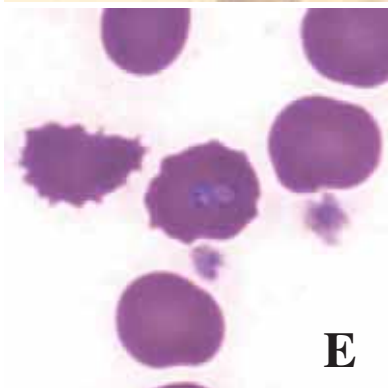
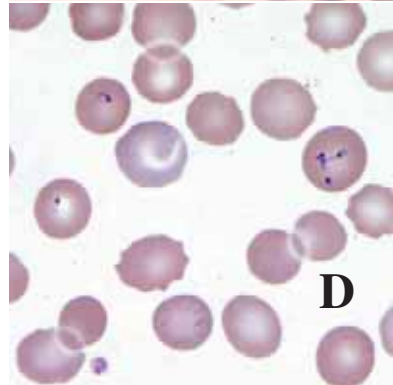
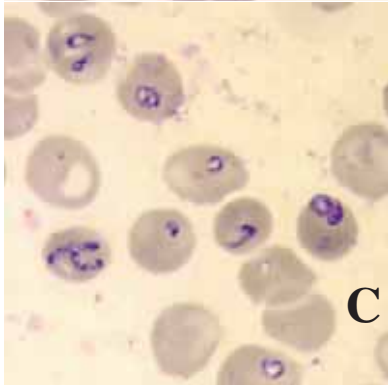
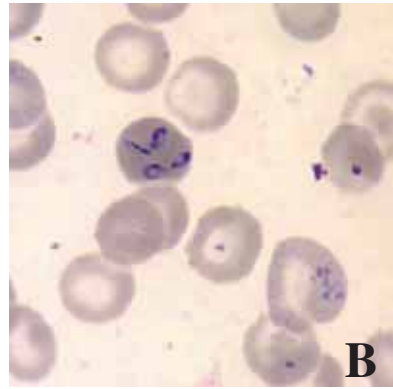
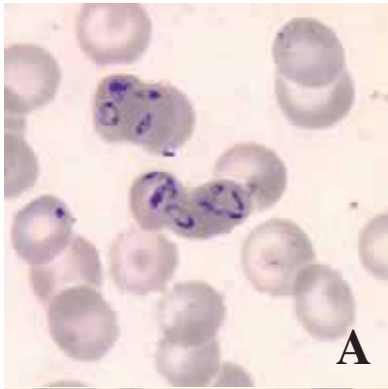

Babesia microti in blood smear. Giemsa stain.

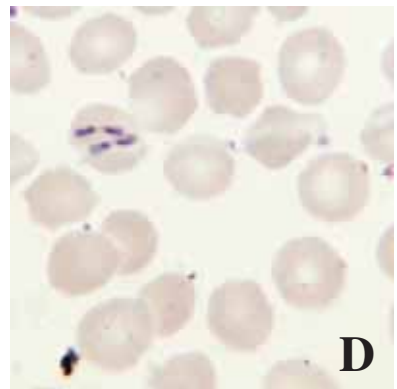
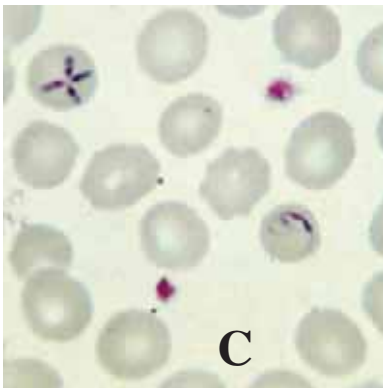
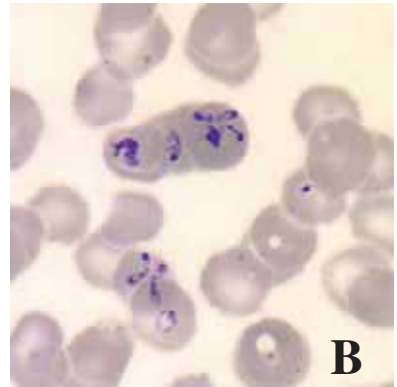
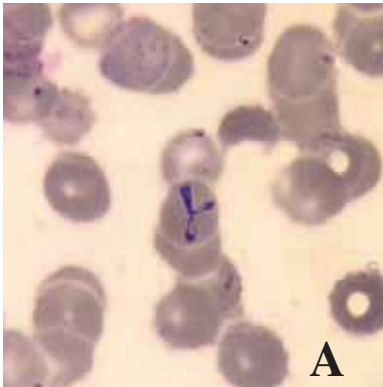
This is a loop shape with a tail attached to the loop.



Babesia forms or platelets attached or near the outside of RBCs.



A - F: Babesia species in thin blood smear stained with Giemsa.

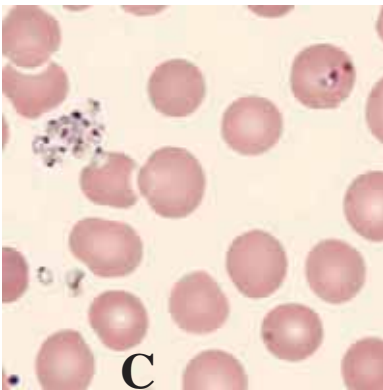
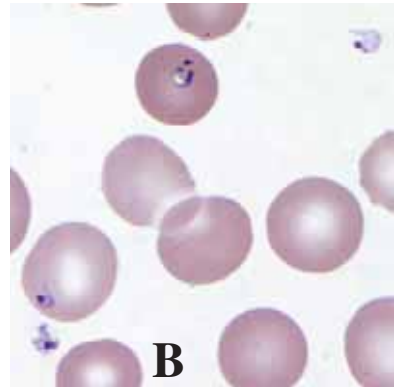
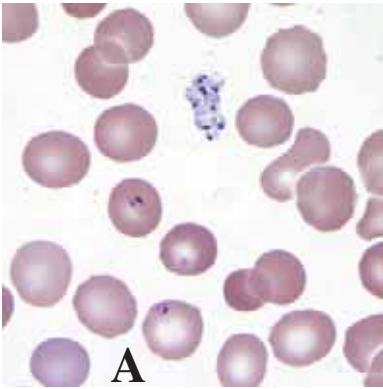


[*Babesia divergens*] [*Babesia microti*]

A, B: *Babesia* sp. in a thin blood smear stained with Giemsa. Note the tetrads, a dividing form pathognomonic for *Babesia*, in both images.

C: *Babesia* sp. in a thin blood smear; note the tetrad form and ameboid trophozoite.

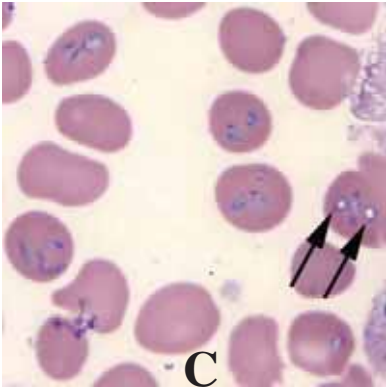
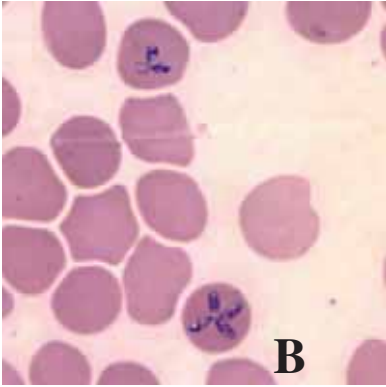
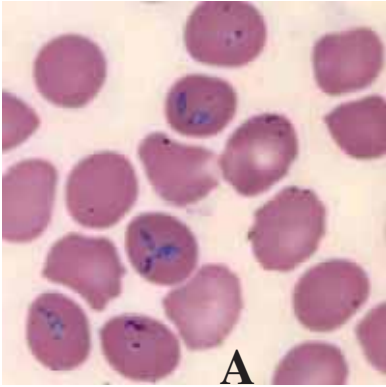
D: *Babesia* sp. in a thin blood smear; tetrad form, pairs aligned.



[*Babesia divergens*] [*Babesia microti*]

A, B: *Babesia* sp. in a thin blood smear stained with Giemsa. Note the clumped **extracellular** forms indicative of *Babesia* in A. B also has **extracellular** forms as well as intra-erythrocytic forms, one of which is vacuolated.

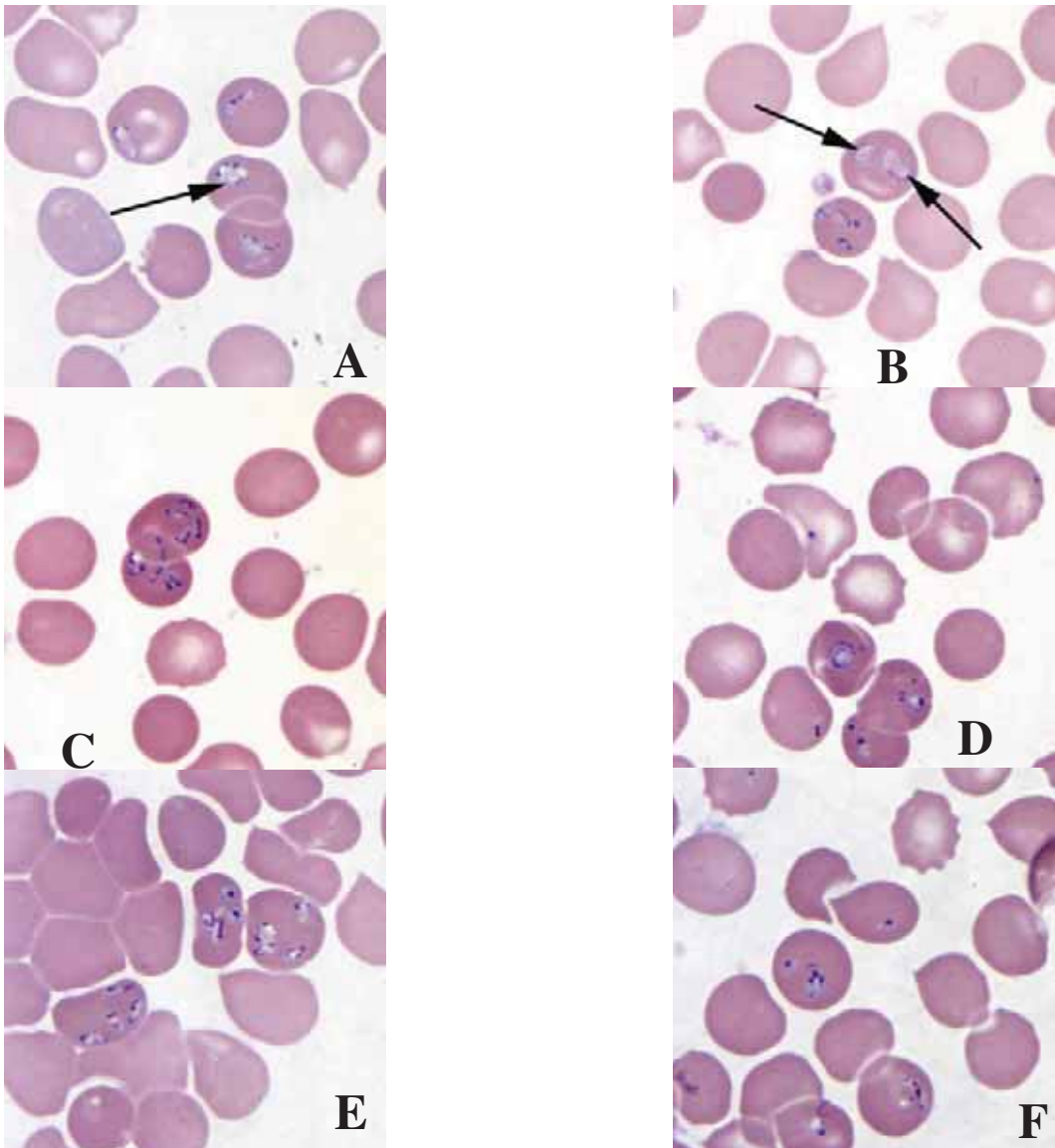
C: *Babesia* sp. in a thin blood smear stained with Giemsa — extracellular forms.



[*Babesia divergens*] [*Babesia microti*]

A, B: *Babesia microti* in a thin blood smear stained with Giemsa.

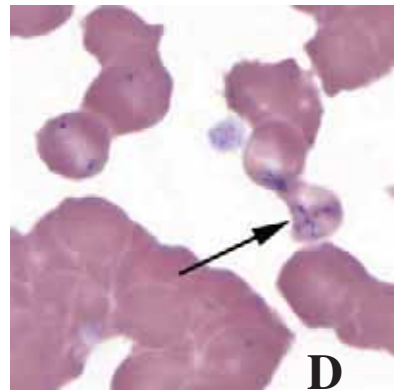
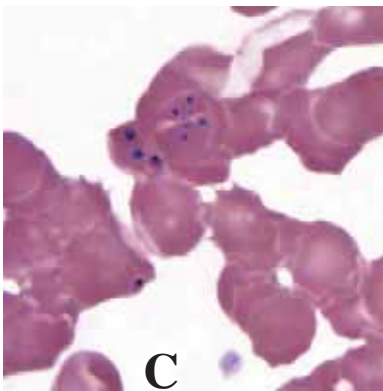
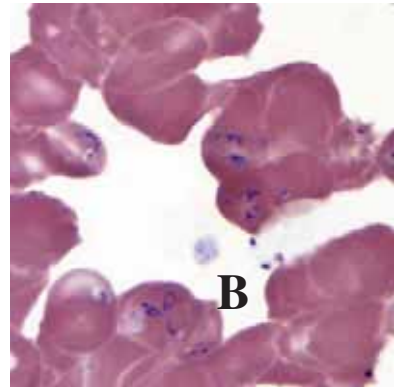
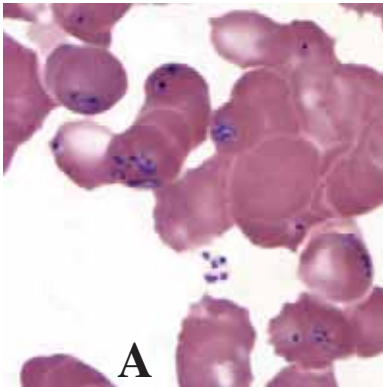
C: *Babesia microti* in a thin blood smear stained with Giemsa. Note the intra-erythrocytic vacuolated forms in C (black arrows).



MO-1 Babesia Forms

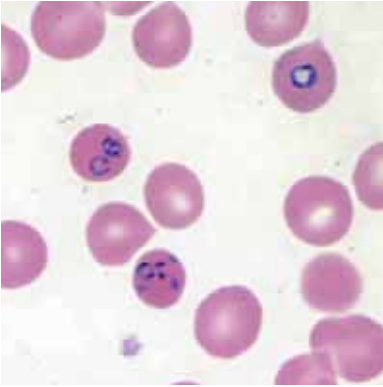
When this new species of Babesia was first found in Missouri the first patient was numbered “1” and the case was abbreviated as MO after the state it was discovered in. However, some researchers and clinicians are finding MO-1 in a wide range of states.

A - F: Babesia MO-1 in a thin blood smear stained with Giemsa. Note the vacuolated parasites (black arrows) in images A and B.



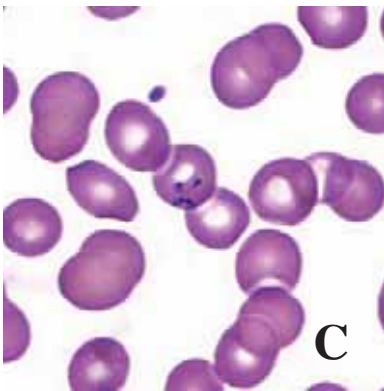
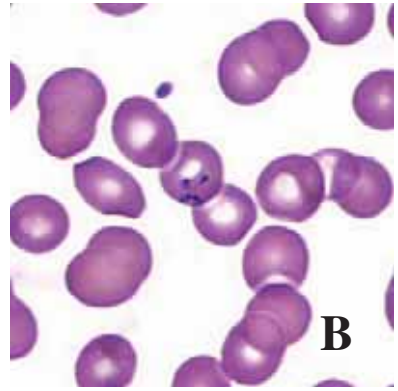
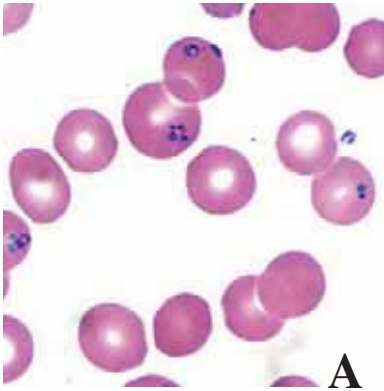
A - D: Babesia MO-1 in a thick blood smear stained with Giemsa. Parasite morphology can be difficult to visualize clearly when blood films are made too thick, or when images are taken from thick areas of a slide.

Do you see any extracellular Babesia forms in any of these slides?



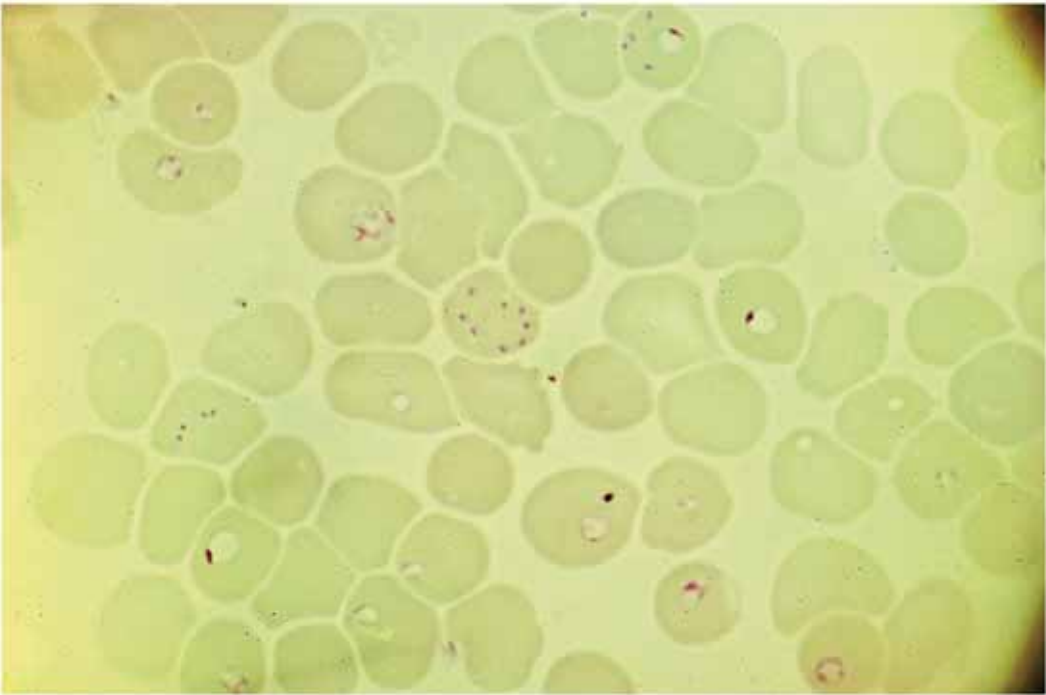
Babesia WA-1 in a thin blood smear stained with Giemsa. *Babesia* sp. cannot be reliably differentiated by blood slide morphology; additional testing is always recommended for speciation.

WA-1 represents a first patient found in Washington state. It is now called *Babesia duncani*. As of this writing, specialized testing has found cases of it all over North America.

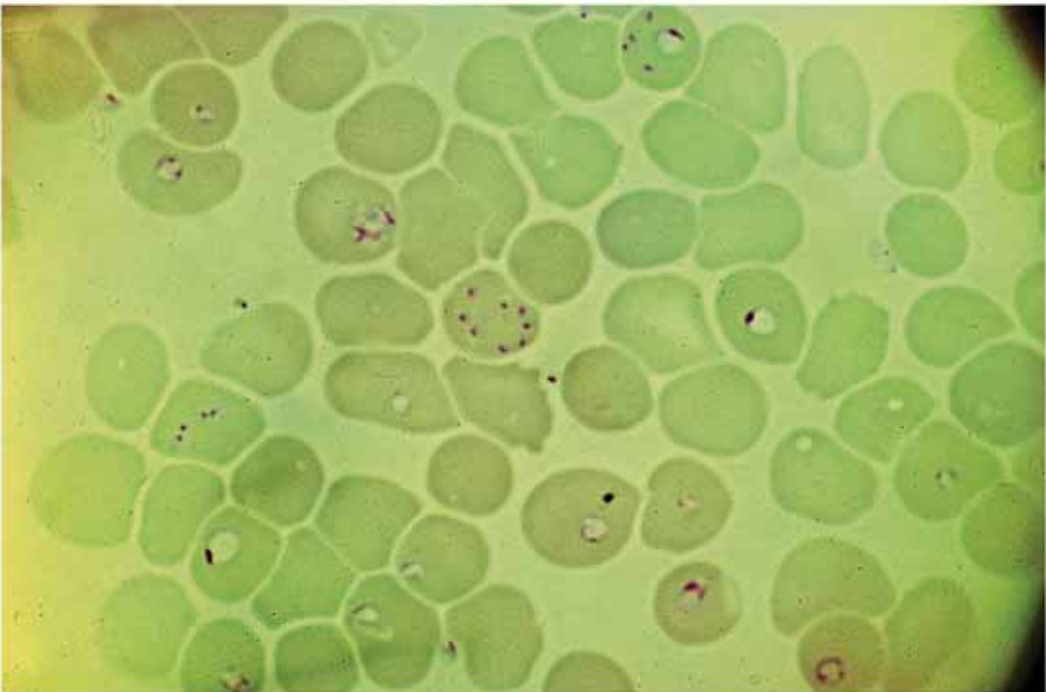


A, B: Babesia sp. in a thin blood smear stained with Wright-Giemsa.

C: Babesia sp., tetrad form in a thin blood smear stained with Wright-Giemsa.

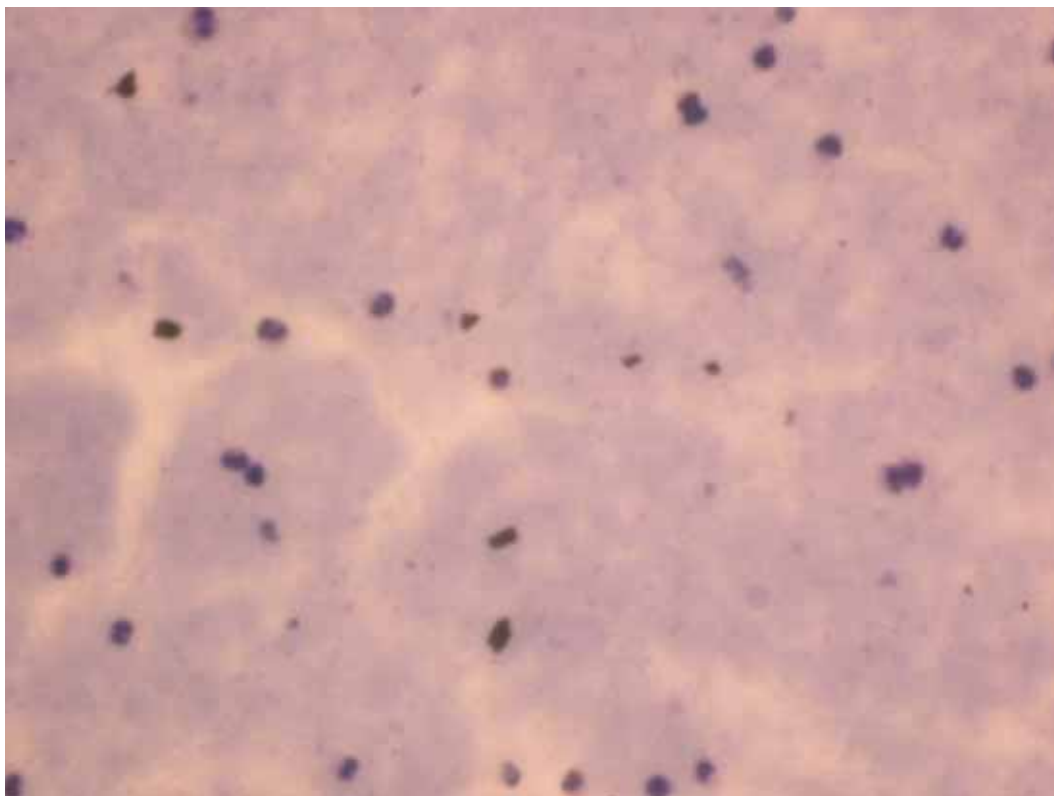


Since you have now seen a wide range of Babesia samples, how many Babesia patterns do you see in these lovely slides?



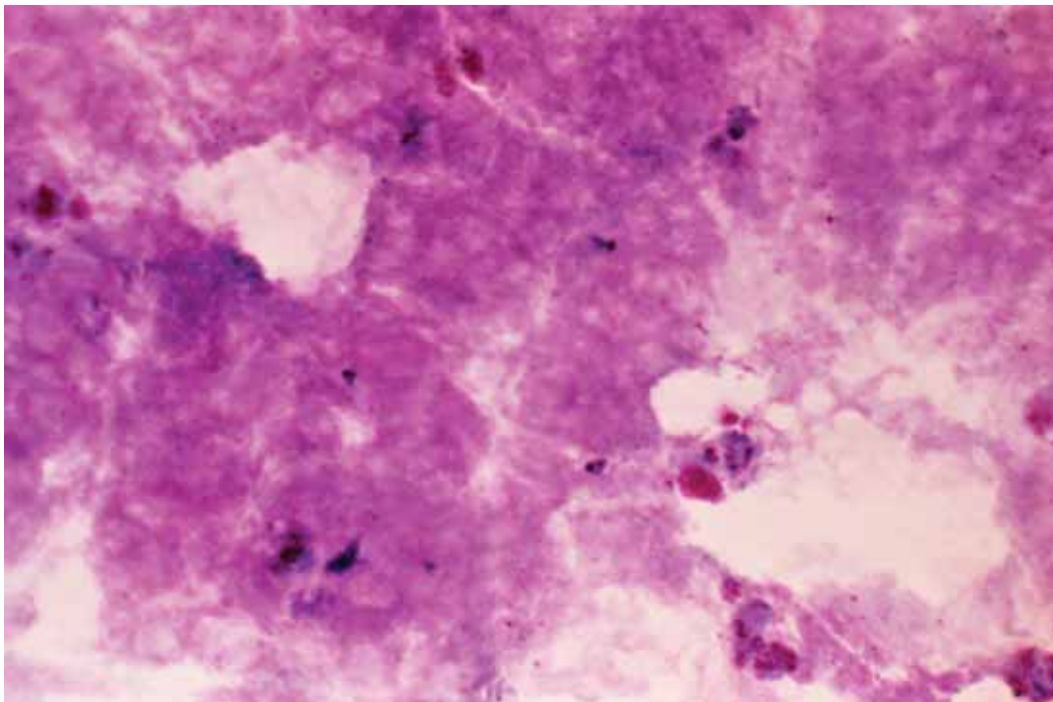
Courtesy of Edward J Bottone, Ph.D. and Daniel Caplivski, M.D., Mount Sinai School of Medicine.

Babesia in Thick Smears



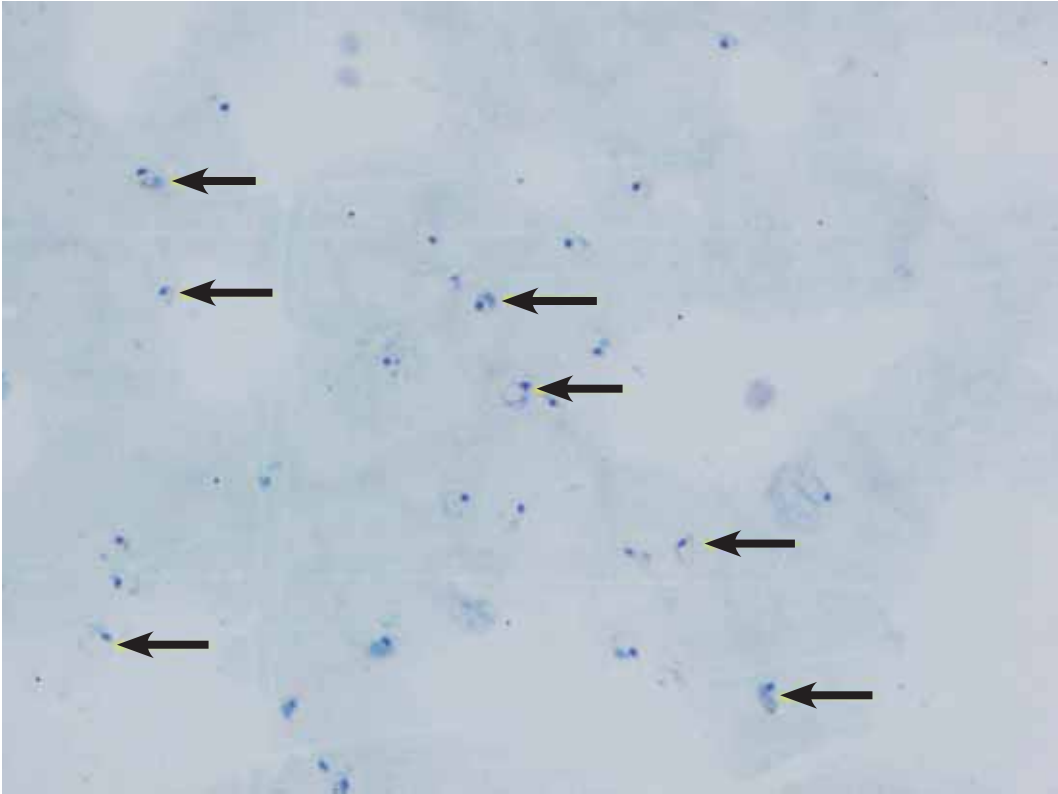
This is a thick smear made from twirling a drop of blood which breaks open red blood cells — it is a Babesia screen test.

You can look at a larger volume of cells with this technique.



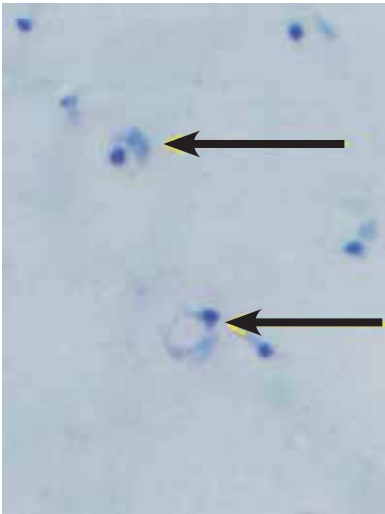
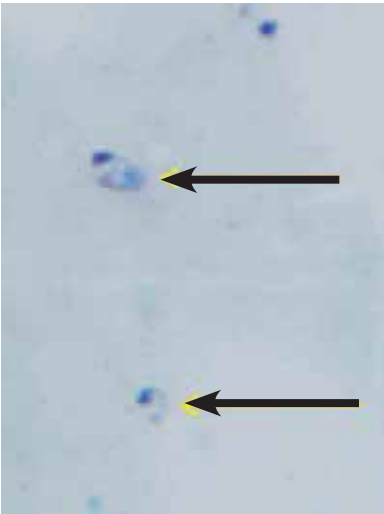
A Giemsa stain of a blood film from an infected human shows the parasite *Babesia microti*.

Do you see the the Babesia forms in this thick smear stain?

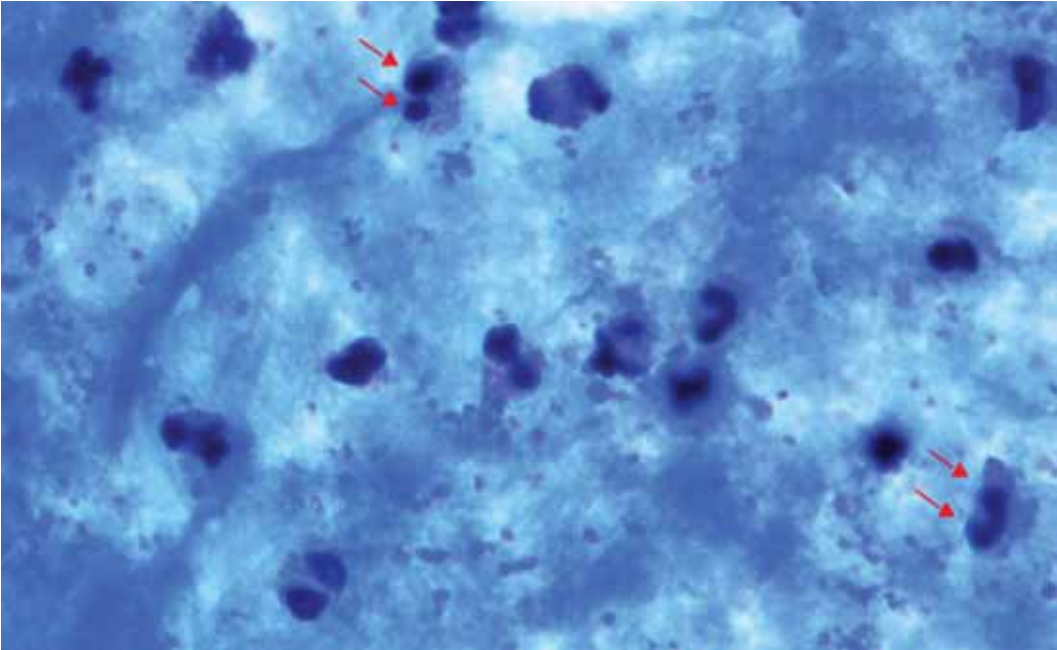


This thick smear in a Geimsa stain shows many clear and diverse types of Babesia ring forms with striking and obvious chromatin dots.

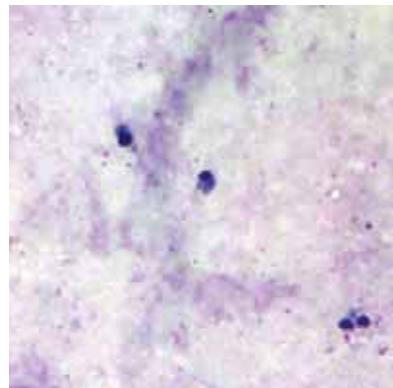
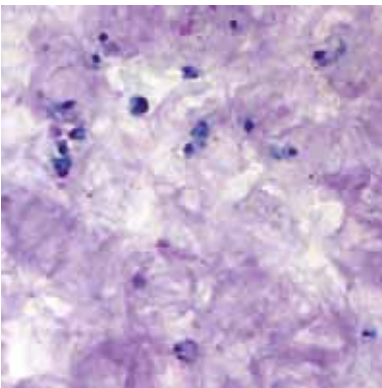
(Side courtesy of Jeremy Bresette CLS, NCA)



Two enlarged sections from this thick smear showing various Babesia forms.



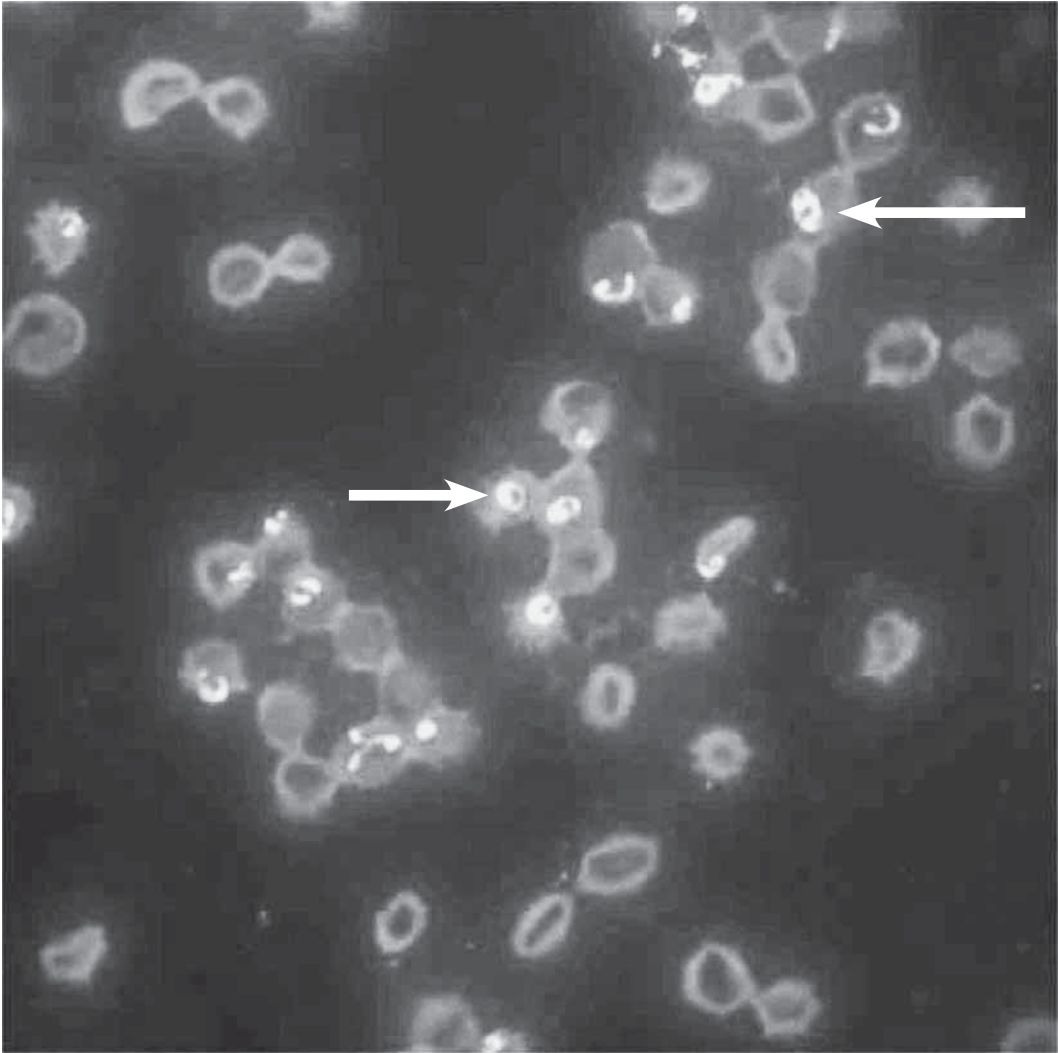
The arrows in the thick smear point to possible piroplasms inside the RBCs which are consistent with Babesia. They are called “piroplasms” because of the pear-shaped appearance of the dividing parasites.



Babesia sp. in thick blood smears stained with Giemsa.

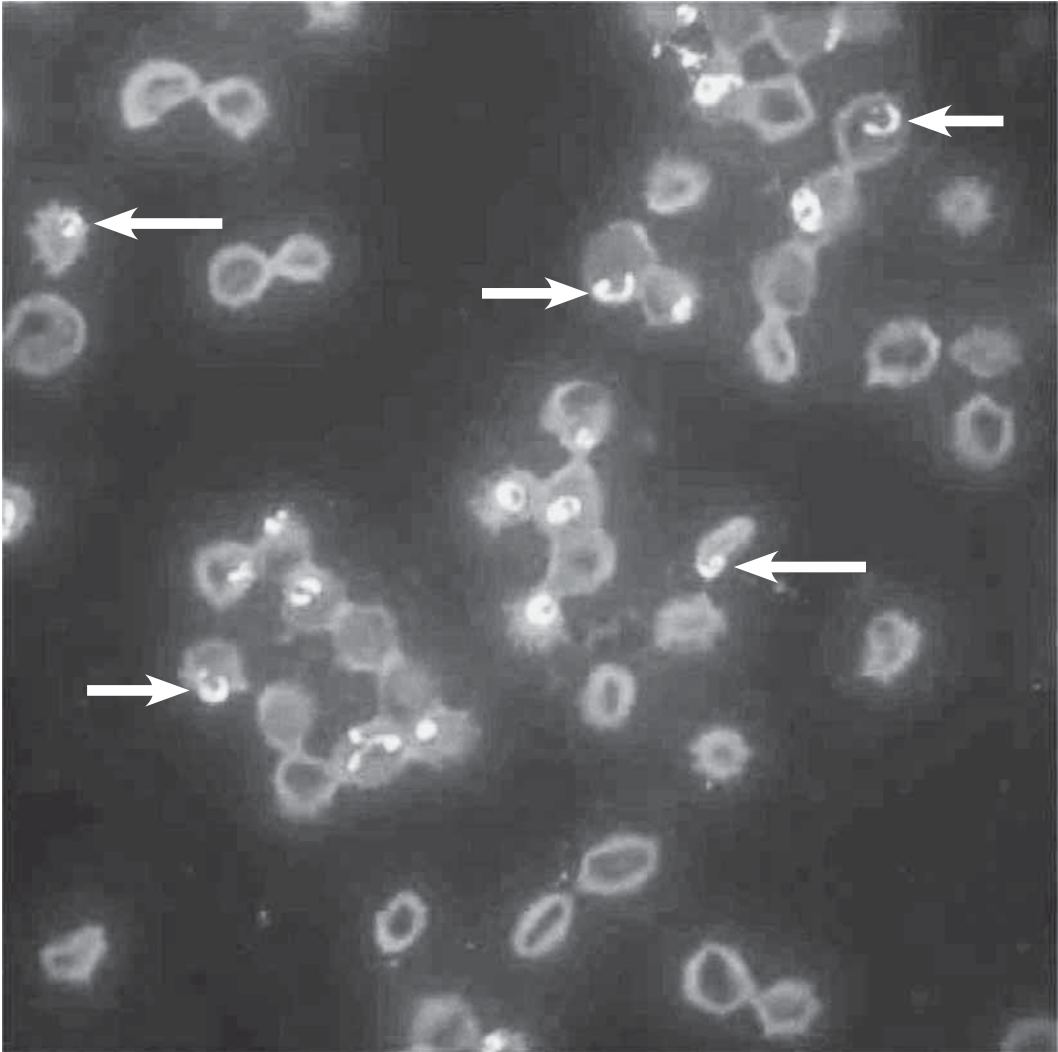
Top: Side and identification Courtesy of Medical Diagnostic Laboratories LLC
Bottom: Images provided courtesy of the CDC's Division of Parasitic Diseases.

Babesia FISH Samples

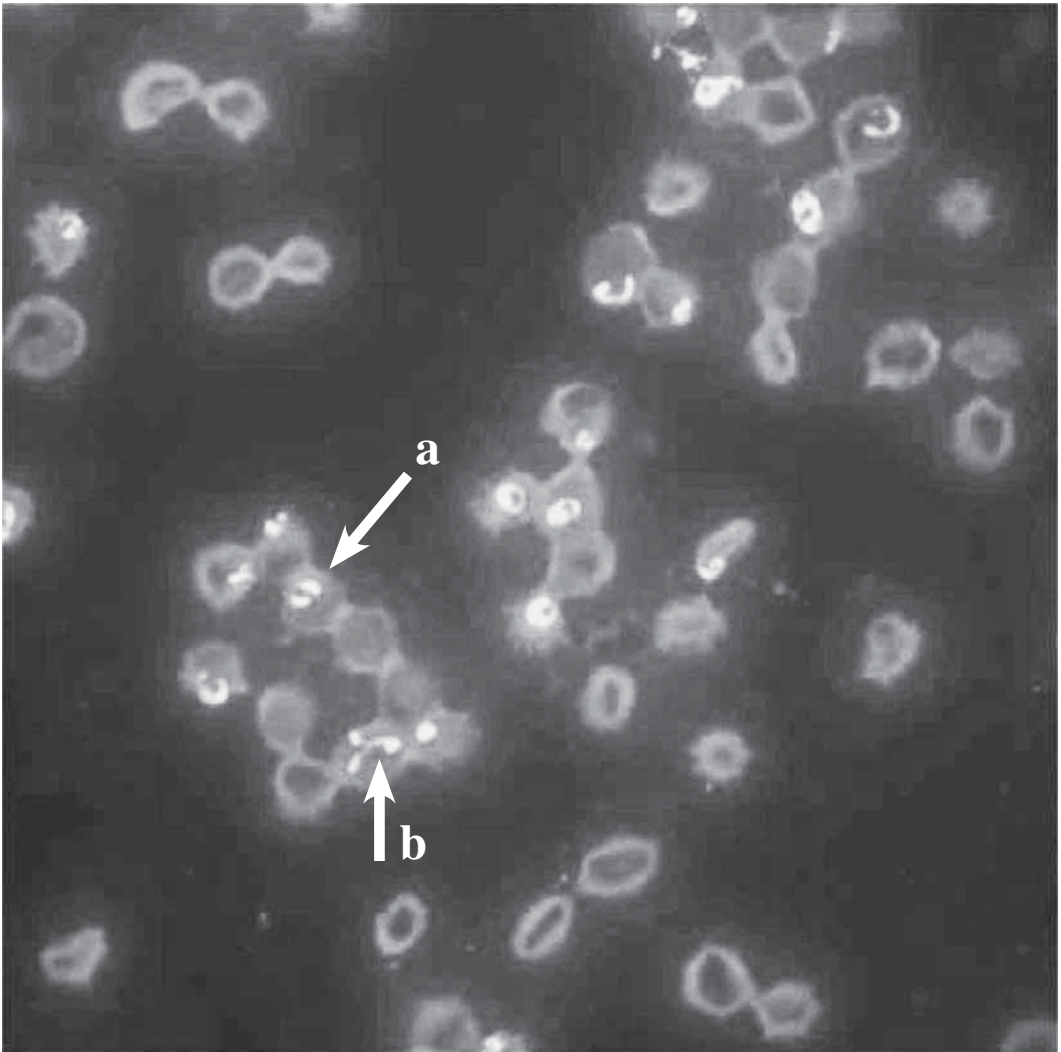


Above: Traditional Babesia ring forms.

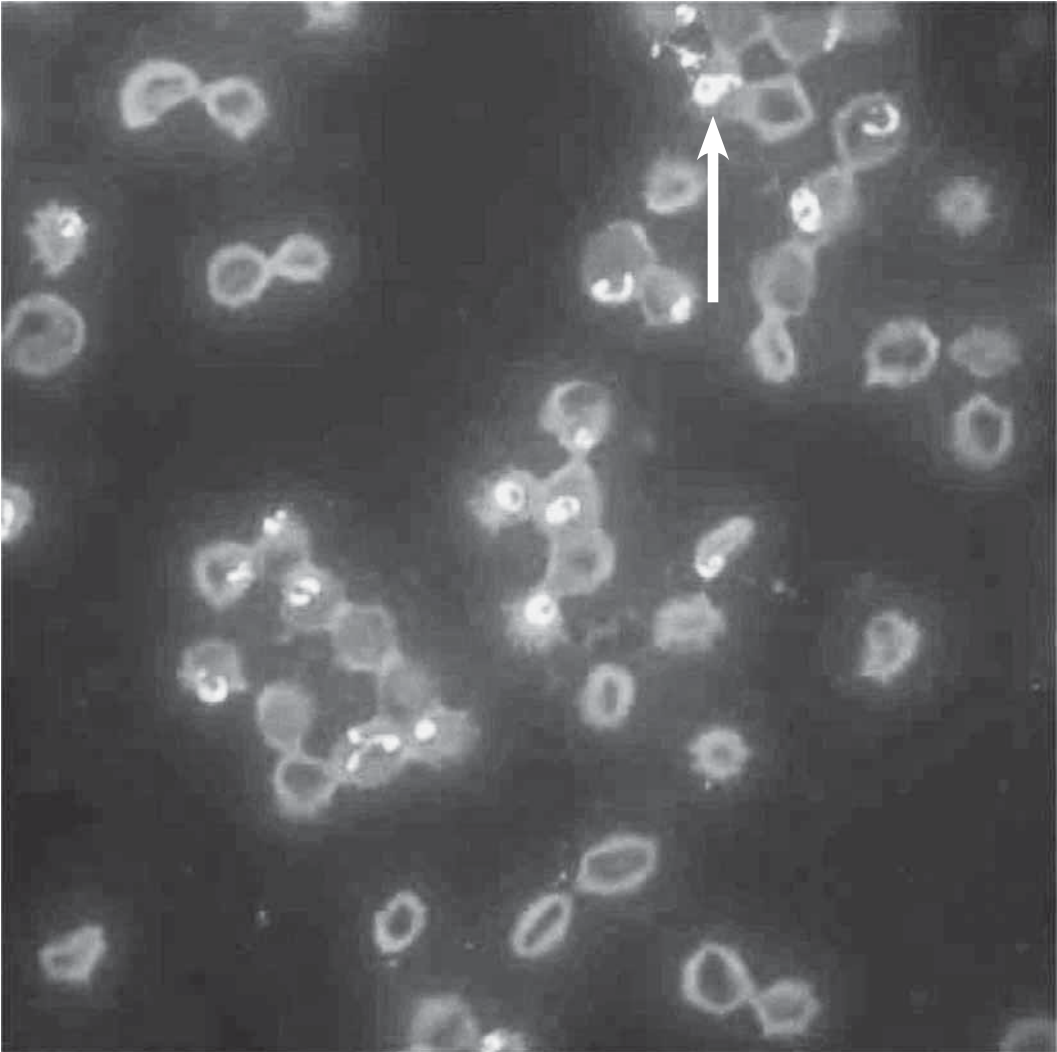
Left: Highly complex Babesia positive finding with various forms inside a RBC.



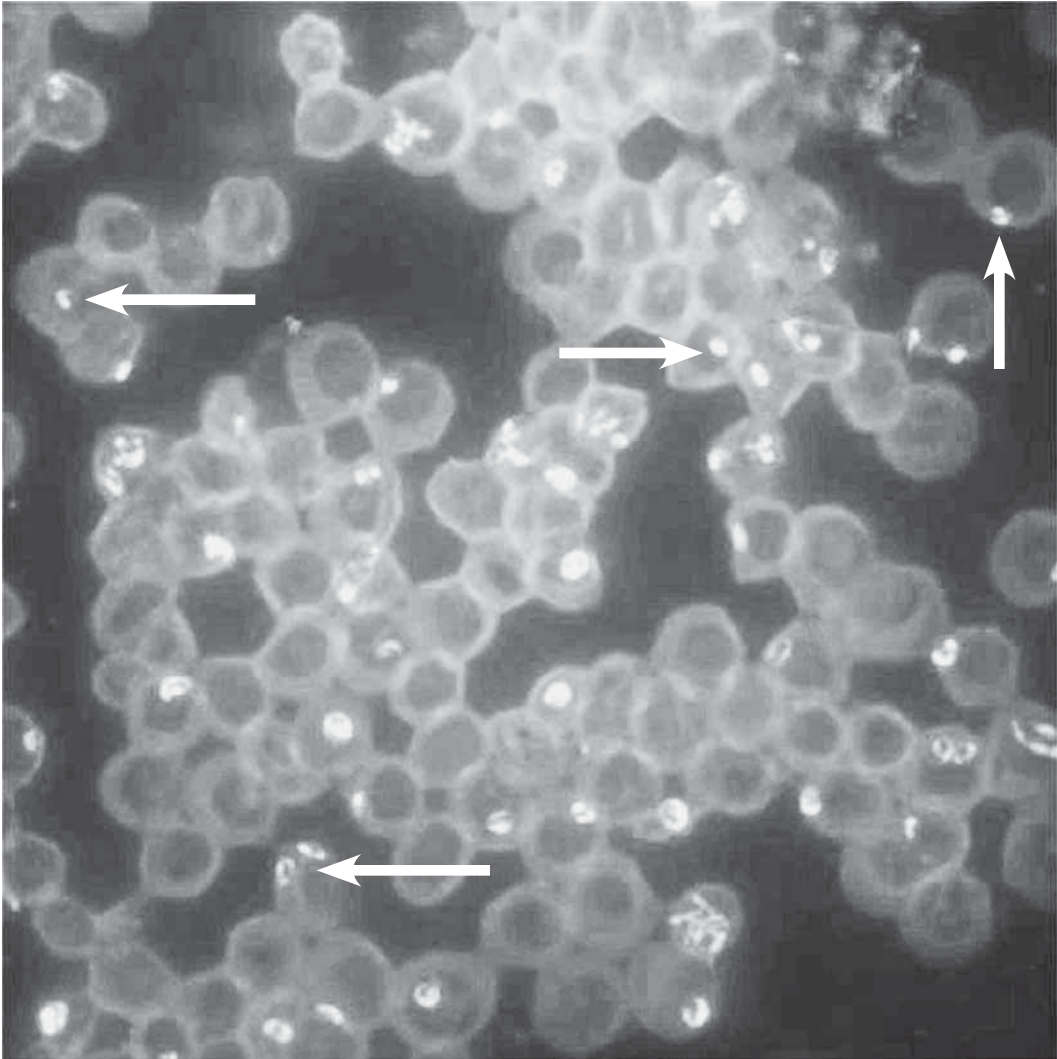
A vast array of crescent forms.



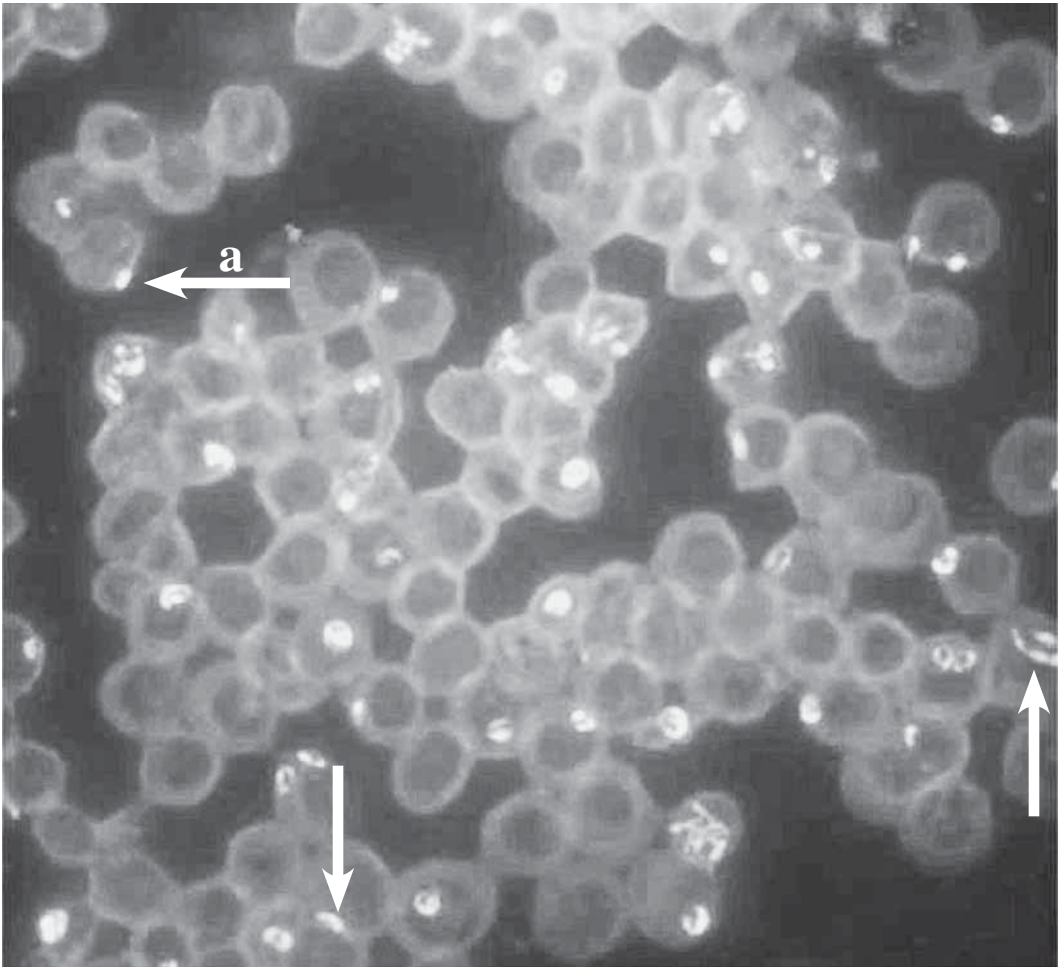
- a. Possibly two Babesia particles or one ring with a profound amount of DNA.
- b. Possibly a triple headed form with three Babesia parts — three merozoites.



A pattern with a tail.



A collection of micro rings. These are easily missed in manual blood evaluations.

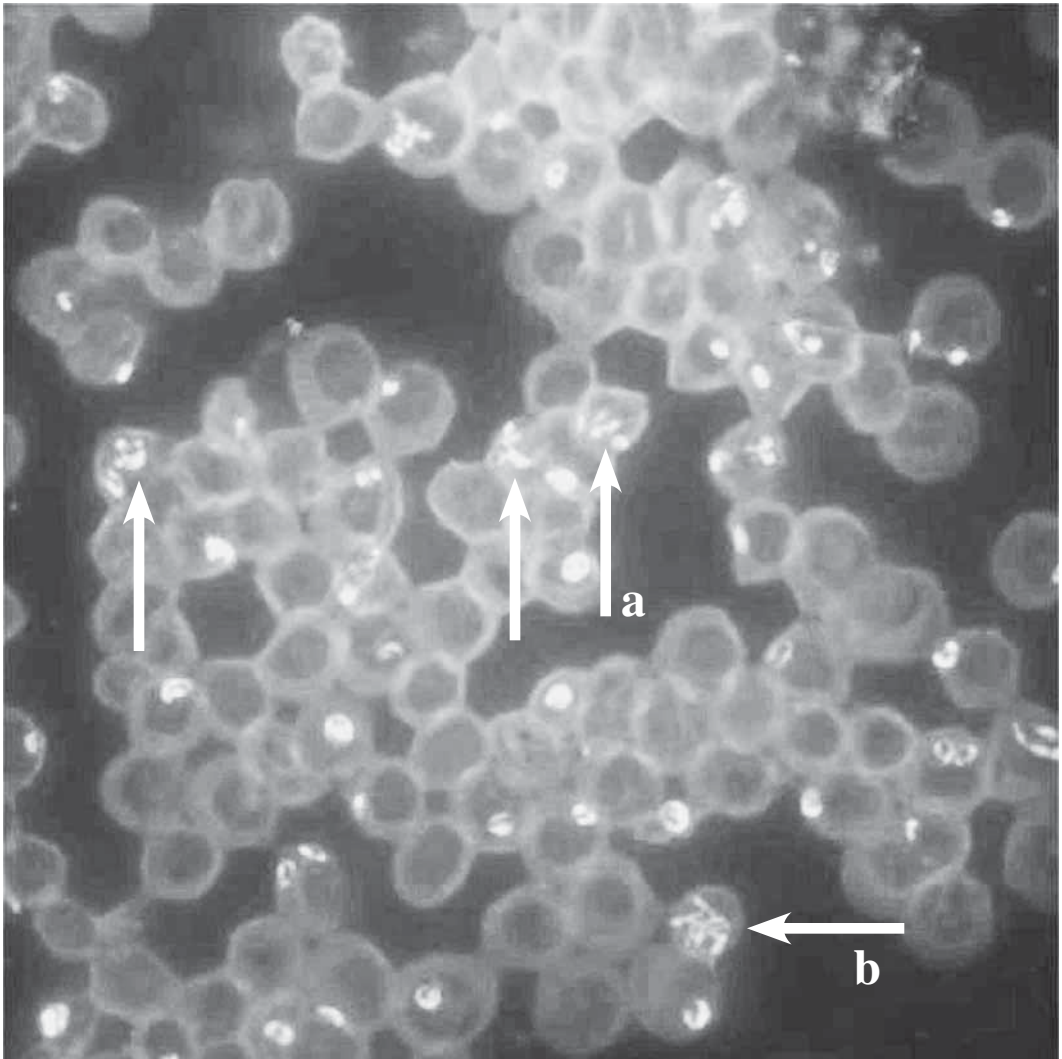


Short and long “hotdog” or “sausage” forms.

The form marked “a” is very tiny and on the outer edge of the RBC. It could be wrongly mistaken for a platelet. In previous slides I have gone out of my way to be tentative in labelling extracellular forms as Babesia, because they can look identical to some platelet forms. I suspect I was extra conservative in doing so.

The FISH in this sample only makes Babesia microti glow, a factor which eliminates the notion of it being a platelet or Bartonella. Nor is it a string of oval Bartonella.

In new pending technology, many Babesia species in humans and animals will be able to be tagged with new specific FISH enhancers.



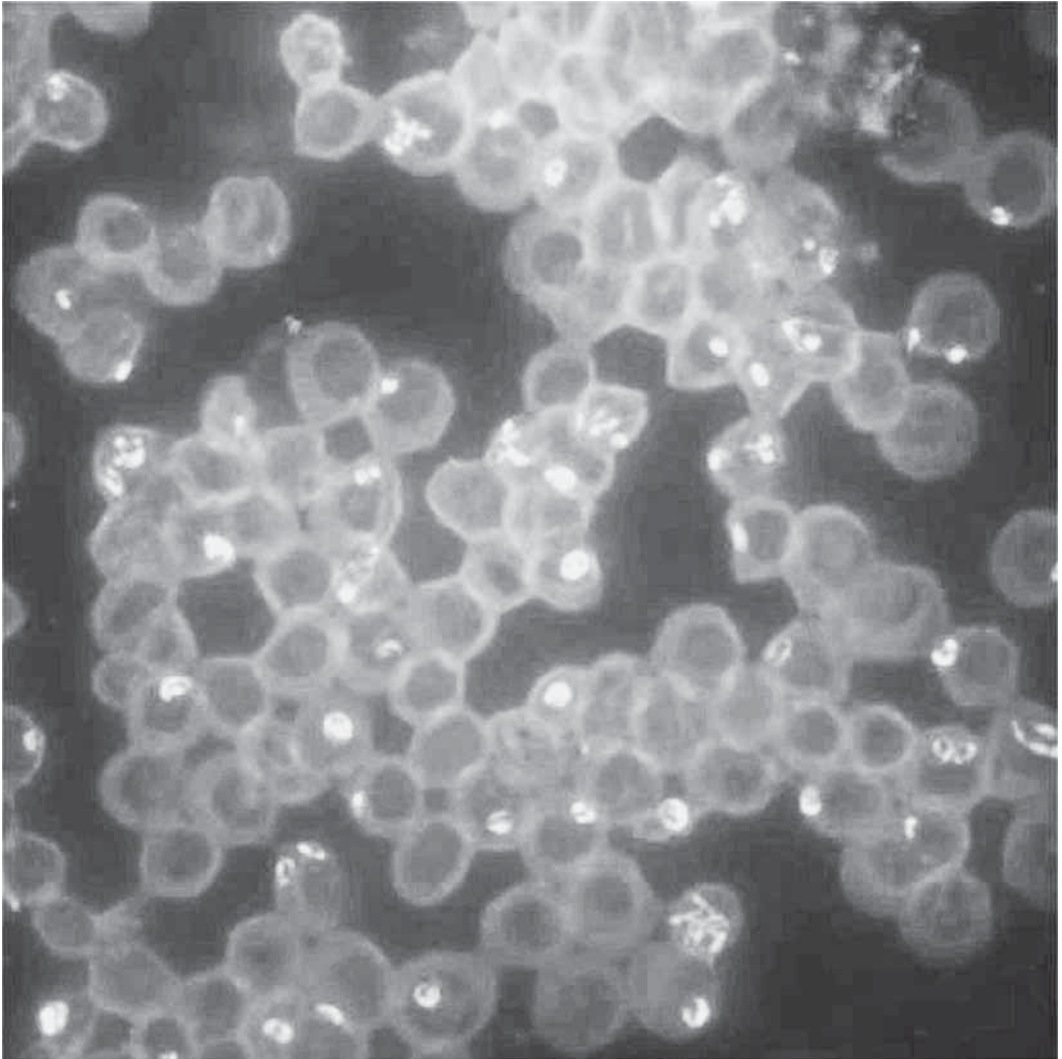
Pictured here are highly complex Babesia forms with multiple shapes in various RBCs. You will find no textbook on parasites or blood examination that shows any of these forms.

One challenge in the examination of some cells, is that even normal blood can have some young RBCs or reticulocytes. These cells can have beaded lines of dark material that can look like some of the material in a. and b. marked RBCs.

However, reticulocyte dark string material does **not** seem to have the width variation in the strings seen in the samples above.

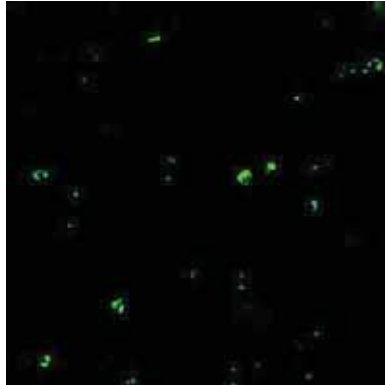
Further, in one article listed below, this form is seen as a “Babesia crisis” form which seems to indicate its association with possible serious illness.

Barbara L. Herwaldt, MD, MPH; David H. Persing, MD, PhD; Eric A. Precigout, PhD; W. L. Goff, PhD; Dane A. Mathiesen, BS; Philip W. Taylor, MD; M. L. Eberhard, PhD; and Andre F. Gorenflot, PhD., A Fatal Case of Babesiosis in Missouri: Identification of Another Piroplasm That Infects Humans. *Annals of Internal Medicine*. 1996; 124:643-650. Specifically, see figure 1. Giemsa-stained blood smear obtained on 2 July from a patient who acquired babesiosis in Missouri.



In summary, this slide and the other similar ones show about 15 patterns.

This collection of FISH smears is provided courtesy of J. Shah Ph.D. She can be reached (and the test ordered) by calling 800 832 3200. This scientist is currently designing new, expanded FISH tests to look for many species of Babesia.



Positive IFA result with *B. microti* antigen. A wide range of Babesia patterns and sizes are enhanced with this special technique.

IFA or Indirect immunofluorescence assay: A laboratory test used to detect antibodies in serum or other body fluid. The specific antibodies are labeled with a compound that makes them glow an apple-green color when observed microscopically under ultraviolet light. (www.medterms.com.)

The RBCs are invisible in this image.

Brightfield	Babesia YOYO1	
		Single Parasite
		Two Parasites
		Three Parasites

Description:
Spot Count is an integer corresponding to the number of connected components within a mask.

Applications:

- Enumerate the number of fluorescent particle inside a cell.
- FISHIS chromosomal polysomy.
- Parasitic protozoan enumeration.
- Counting phagocytosed particles.

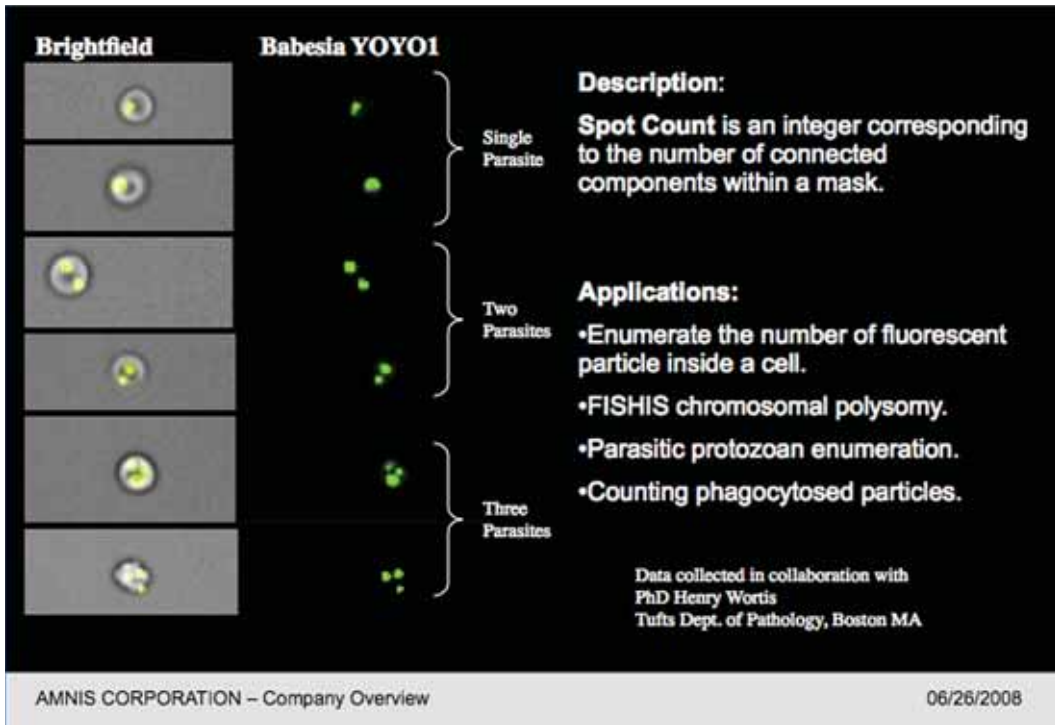
Data collected in collaboration with
 PhD Henry Wortis
 Tufts Dept. of Pathology, Boston MA

AMNIS CORPORATION – Company Overview 06/26/2008

This amazing slide shows two forms of staining. First, traditional brightfield, and the second is the YOYO1 staining process.

The Babesia parasites seen on the left of this table are in brightfield.

Brightfield is the term used to describe traditional microscopy performed with transmitted light. The background is a uniform bright field that either brightens or darkens the area where the light passes through structures within the cell and is refracted or absorbed on the way to your eye.



The YOYO1 stain is advanced and hard to find for regular clinical use. But it gives useful information about what Babesia looks like inside RBCs. It allows one the ability to count the number of Babesia parasites inside a RBC. In this set of cells, the researchers found one to three in each cell. While it is possible to see the Babesia inside the RBCs in brightfield, it is markedly easier to see them with the YOYO1 imaging.

(Babesia-infected murine erythrocytes imaged in flow using transmitted light and TOTO-1 fluorescence on the Amnis ImageStream system. Figure is courtesy of Amnis Corporation. Data acquired in collaboration with Dr. H. Wortis and Dr. R Berland, Tufts University.)

Babesia Sketches

In an effort to increase your ability to see Babesia forms, I have made obvious sketches based on a vast array of Babesia images. Specifically, I have tried to purchase every major parasite and hematology book, along with every article and link that offers Babesia images.


Then I took each cell with Babesia and copied any unique patterns of Babesia in the cell.

Simple sketches will enhance your ability to see the Babesia forms in the huge collection of Babesia blood smears contained in this book.

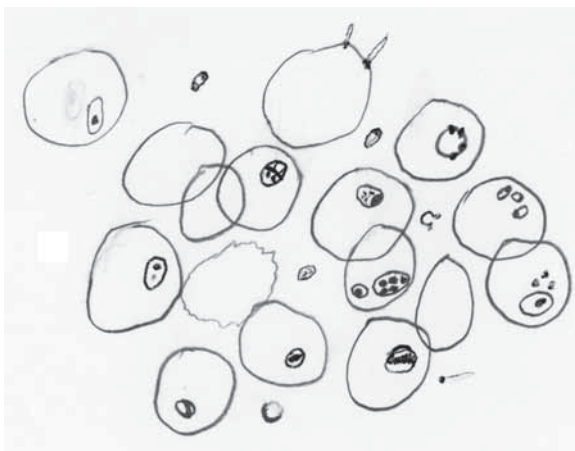
The slide smears you have already seen were a warm up, but they do not represent every form. Pattern recognition is further enhanced by viewing Babesia forms in many different presentations. I hope these rough sketches will enhance your Babesia blood smear diagnostic powers.

Image Names


Since some forms of Babesia discussed here are not clearly identifiable by pattern, I have taken the liberty of assigning some informal names, which are by no means authoritative.



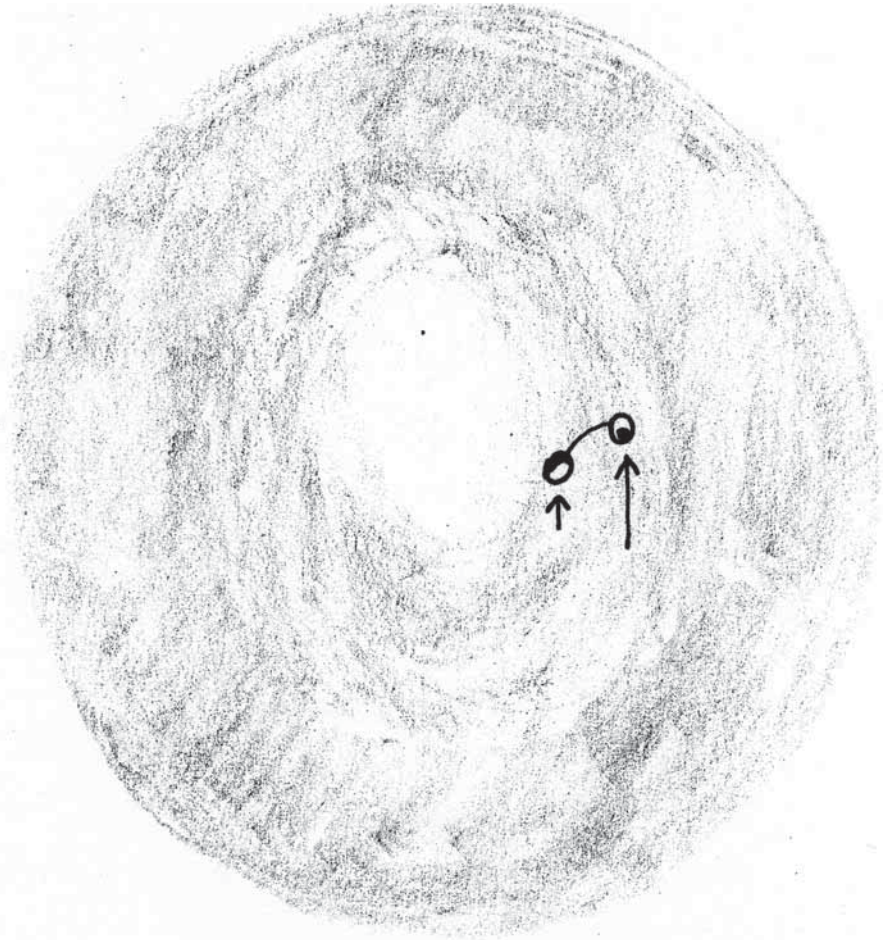
Most CBCs, or **Complete Blood Counts**, in the industrialized world are done by machines. These machines are not able to “see” Babesia. No machine is going to catch all these subtle small Babesia forms.



Rough sketches of *Babesia microti* images uncovered with a Wright stain.
(Source image: The Centers for Disease Control)

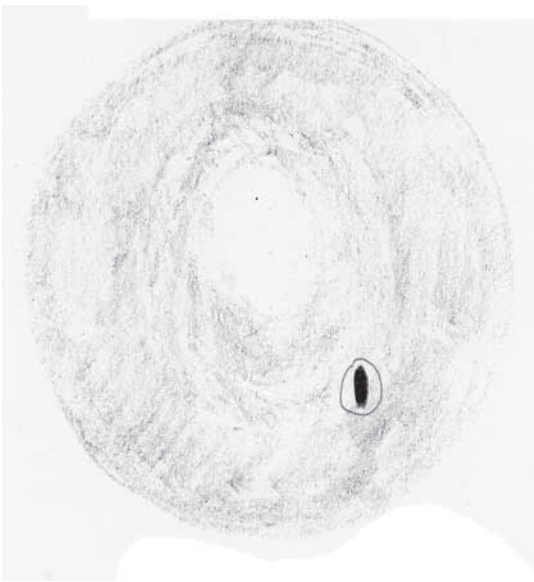


Bartonella inside the red blood cells of a cat. These bacteria can be fairly large and variable. They can present a challenge in some cases when a cell might have both *Bartonella* and *Babesia* or a single type of form that could be either. Some *Bartonella* can have a variable presentation based on species. However, most North American species infecting humans look similar. The dangerous and localized *Bartonella bacilliformis* is typically found in Peru, Ecuador, and Colombia, and is passed by a fly bite. This very unique *Bartonella* looks profoundly different in RBCs when compared to more common human forms.

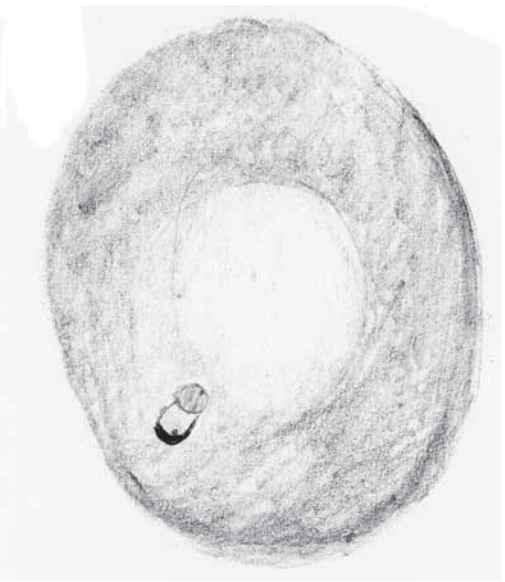


Variations in Babesia DNA or Chromatin Dots.

The short arrow shows Babesia chromatin can be bandlike or as a thickening of the ring. The large arrow shows an obvious chromatin dot.



Slit Form




Dangling Ear Form

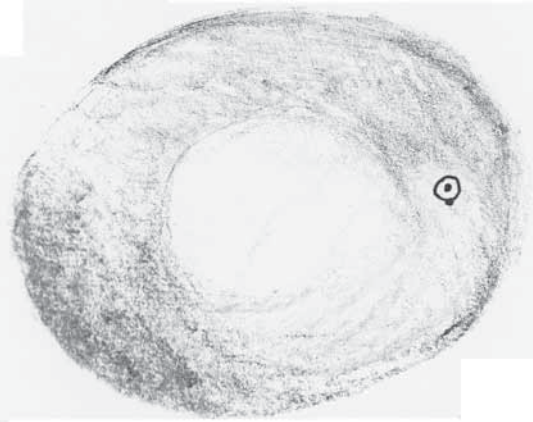


Crescent Forms

Some crescents show **slight** signs of a closing of the crescent. In many situations, it is not possible to see a closing of the crescent. It is likely some of these are a type of ring form since they disappear with high doses of Babesia treatments. For example, with doses of Mepron in **excess** of 1500 mg./day.



Triple Dot Ring Form



Eye and Dot Ring




Multi Dot Ring

Some red blood cells have rings called “Cabot’s Rings,” which are associated with marked anemia. It appears that anemia routinely alters the look of RBCs. Thus, when this type of ring is present with normal red blood cells, it is less likely to be a Cabot’s Ring and more likely to be Babesia.




Merozoites or Sperm Forms



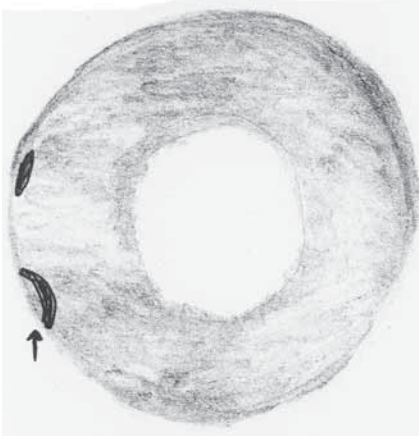Eye Ring Forms




Worm Form



Rabbit Ears




Crescent



Earring Form

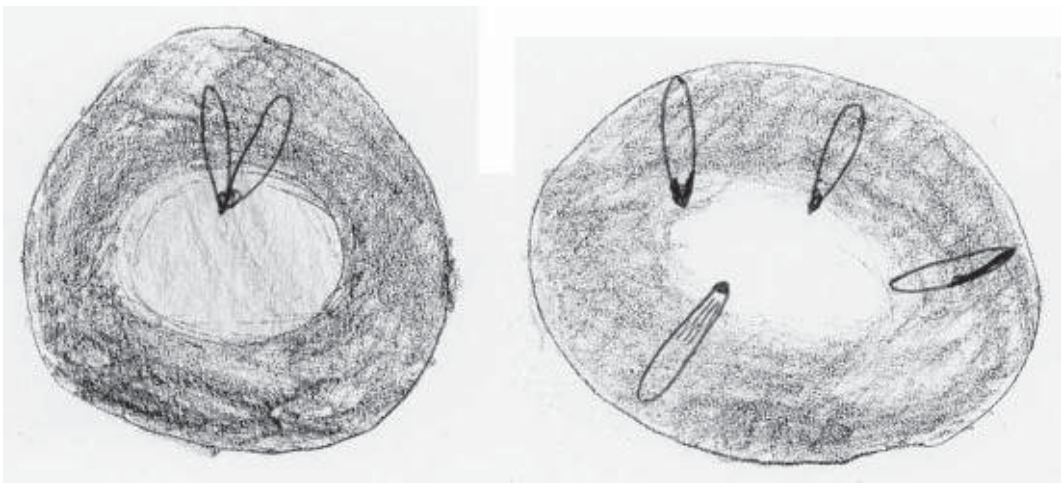
The “worm form” might be a reticulocyte with dark dots or strings; however Babesia sometimes has a similar presentation.

The crescent form marked with an arrow can be right at the edge of the cell and may also be flattened out.



Rabbit Ears Variations


Each of these rabbit ears are forms of individual Babesia parasites.



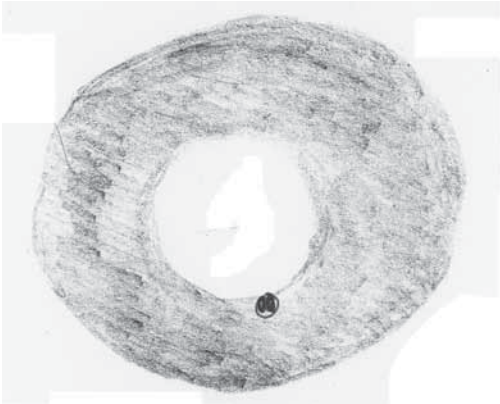
Rabbit Ears Pattern

Scattered Rabbit Ears Pattern


Some might think these are all Babesia merozoites in various presentations.




Many sources show a Babesia pattern in which individual forms are stacked or crammed together like sardines. One Babesia article calls this type of extensive Babesia forms in one cell, “polyparasitism.”




Big Eye Form



Eccentric Ring




Eye Cluster




Eccentric Rings

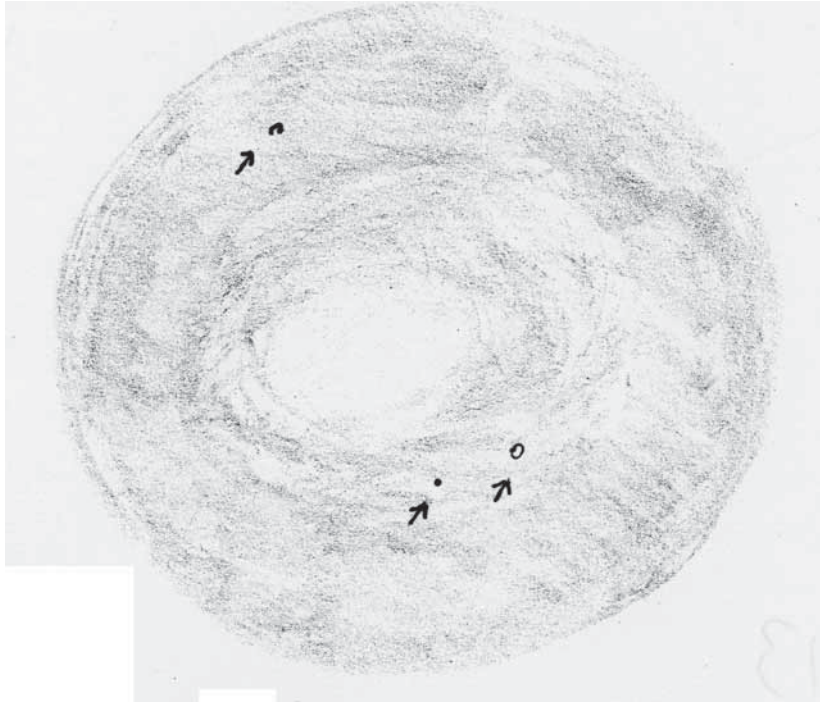
The black dots are DNA or chromatin. The **thickened** or darker areas of various loops or open-ended forms also are due to extra DNA.




Dot Cluster Forms



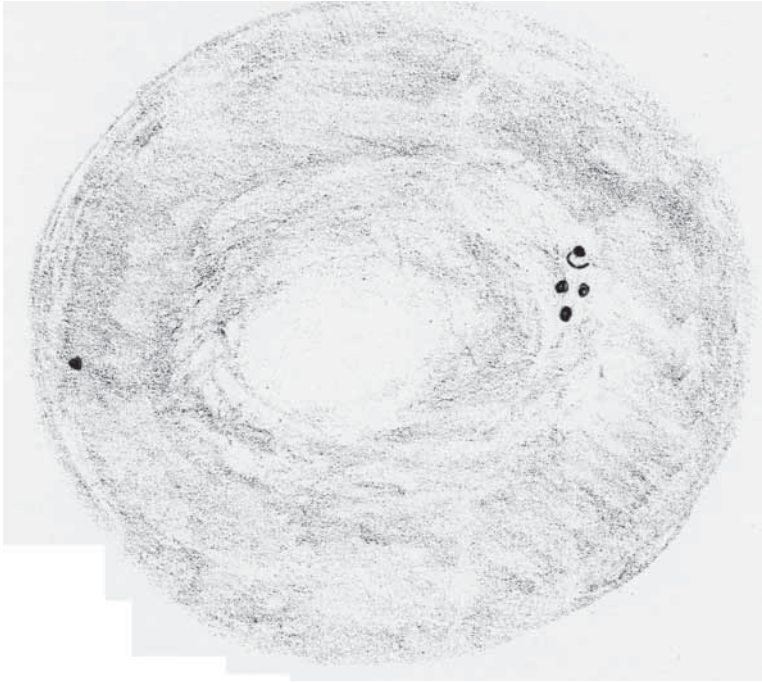
An RBC which has Babesia dots with no cytoplasm inside the RBC, next to tiny Bartonella bacteria dots on the outer edge of the RBC (marked with arrows). In this context it is the size which helps separate the parasite (Babesia) from the small bacteria.




In early Babesia development, there is very little cytoplasm. Further, the nucleus may also be very small and appear as a mere tiny dot (a chromatin or DNA dot).




Babesia Outside Red Blood Cells



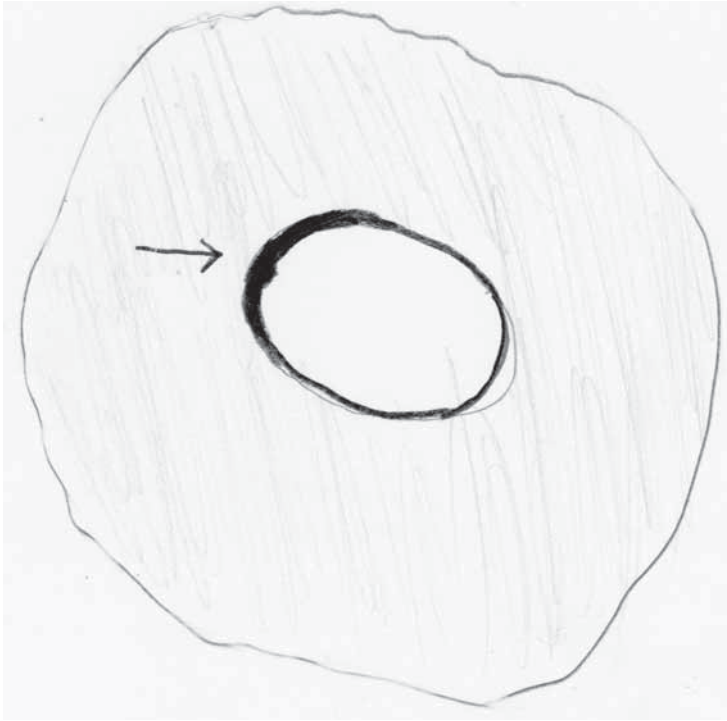
The open ring form above the three dots is classic Babesia. The open ring has a chromatin (DNA) dot. The three other dots are the same size. Therefore, it is likely this is Babesia with chromatin dots with no obvious cytoplasm around them. Bartonella bacteria, platelets or artifacts, would not have an open ring such as what is seen on the top right side.



Malaria clearly has enlarged rings which sit perfectly in the center of the red blood cells or which can be off center. I feel Babesia can do the same. If the surrounding cells do not show signs of anemia, these are more likely to be Babesia forms and not Cabot Rings.

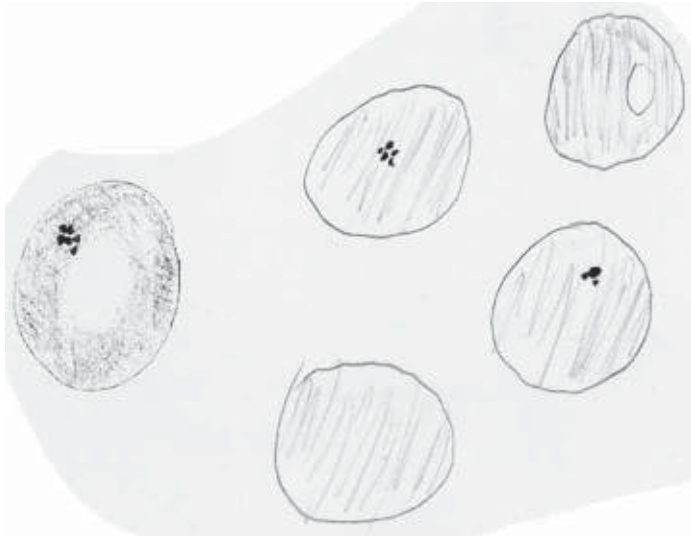


Babesia small ring forms or trophozoites alone or in pairs. This stage is often considered a high movement stage with feeding and reproduction.



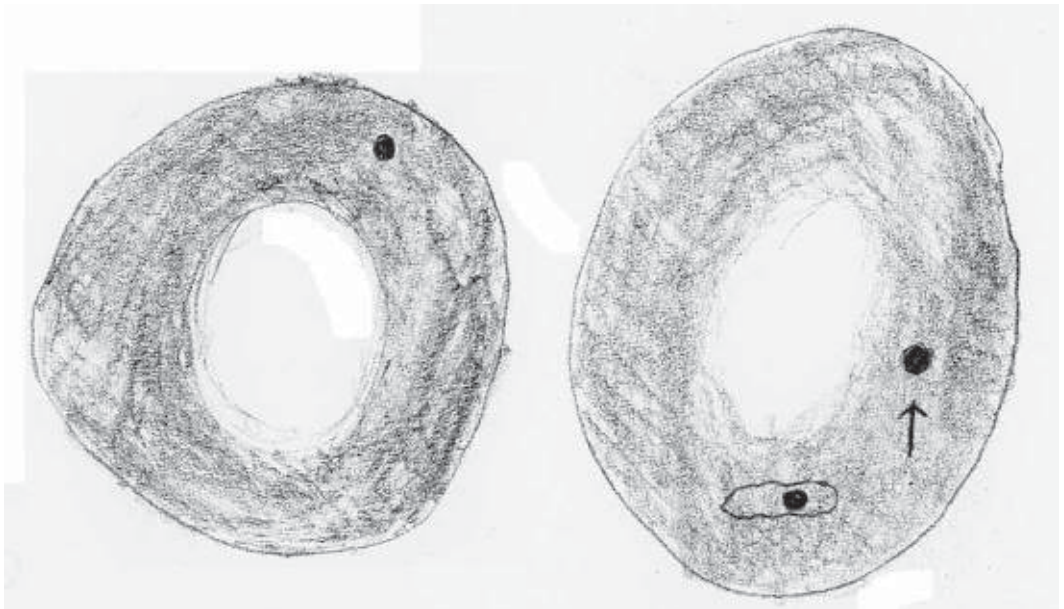
Possible Babesia

Dr. J. Whitaker is a multi-specialist physician with years of experience and many publications relating to the pathology of blood cells. It is her opinion that the large ring pattern pictured above is a form of Babesia in an active feeding stage (trophozoite) with a peripheral nuclear band.



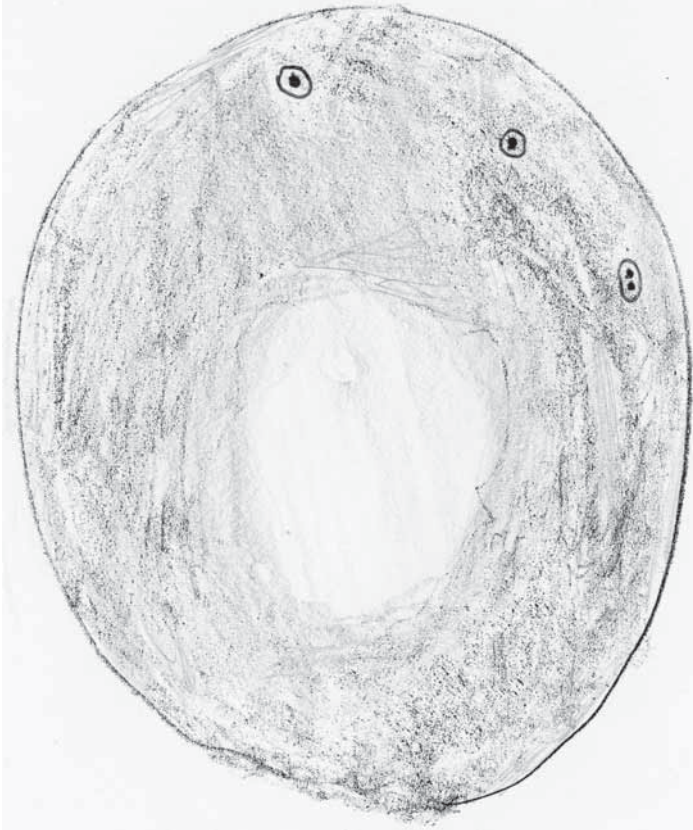
Pappenheimer Bodies

Irregular granules of iron in clusters caused by some anemias and the absence of a spleen. In a single text, in one image, some **angled** dark lines were called Pappenheimer Bodies. I hope the author could tell the difference between Babesia and these forms.



Howell—Jolly Bodies

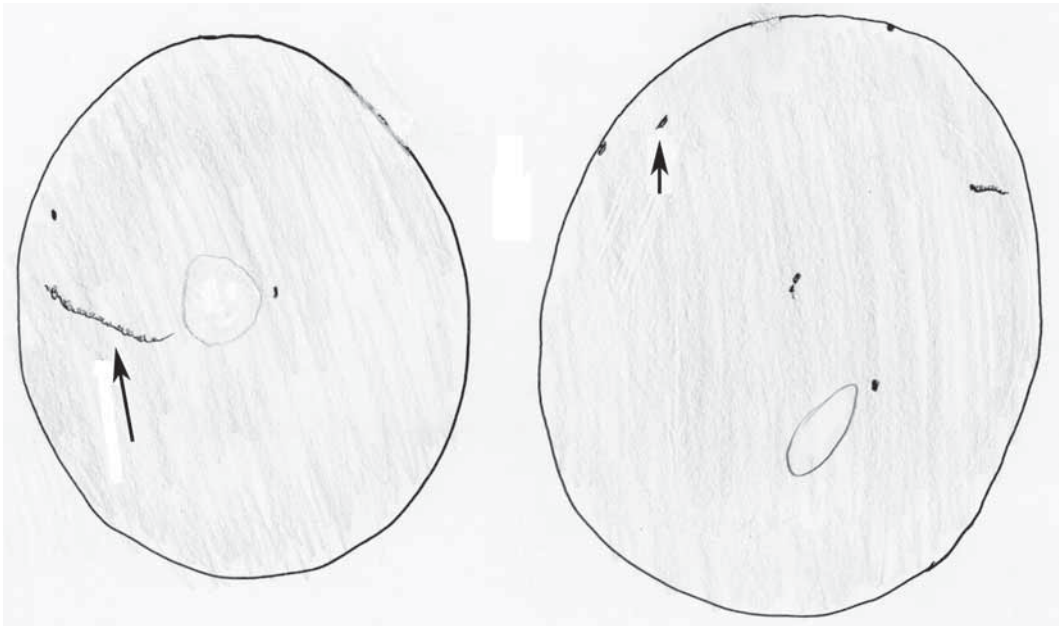
Ignore these in any exam that is looking for Babesia. They are left over signs of nuclear decay of young RBCs found in some anemias and spleen illnesses.



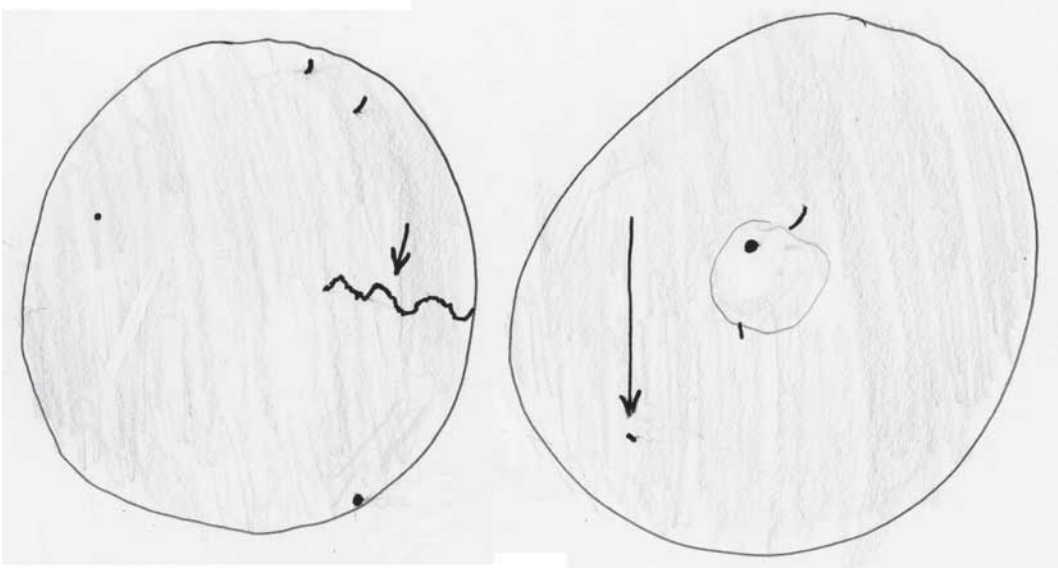
Eye and Double Eye Babesia Patterns

These forms may also be referred to as “Fried Egg” Patterns. Please keep in mind that these names have been unofficially assigned to identify patterns as we examine them, and are in no way meant to be authoritative. The sole purpose for sharing these findings is to help to put an end to the increasing number of false negative Babesia findings in routine manual blood smears. If formations appear to look like a single eye it is possible they are only platelets. (Further, **one image** in print seems to suggest that they also might be Bartonella, but the contributing authors show little awareness of Babesia).

Proposed Bartonella in Cat RBCs




The long arrow points to a “string of pearls” in a RBC with Bartonella bacteria near it in the same cell. The small arrow points to a sample oval Bartonella bacteria. I have no opinion as to whether the “string of pearls” is Bartonella attached in a line or Babesia open and in a line or a combination of both infections. **The stunning lack of international intra-cellular Bartonella images strongly urges cautious examination.**



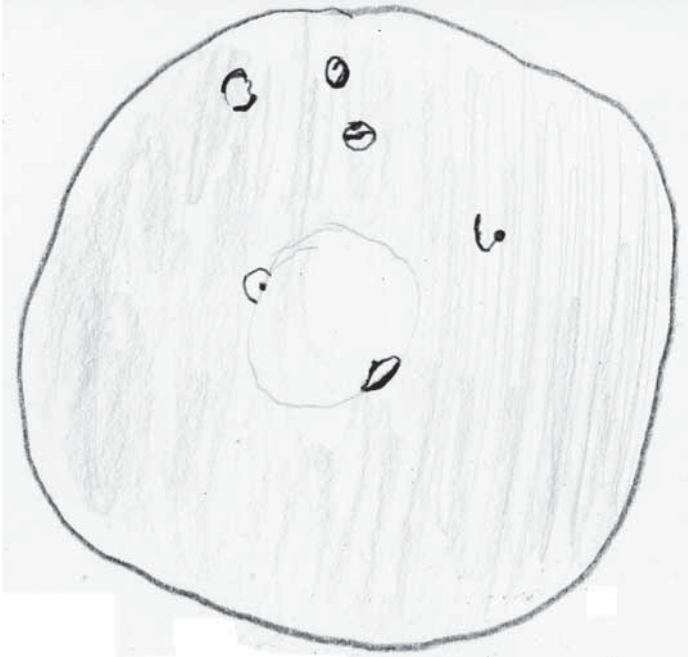
Canine Bartonella Inside Red Blood Cells

Perhaps one way to distinguish between the “string of pearls” Babesia and Bartonella bacteria is to look at the size of the bacteria. Are the small round or oval shapes attached to other materials like a ring? The long arrow points to an oval bacteria with no clear cytoplasm around it. The short arrow points to an unknown organism. The **genus PCR** procedure, a first-line diagnostic PCR screening from Fry Laboratories, may be available as early as December of 2008. This is great news for patients, their families and treating physicians, since it has the ability to distinguish between patterns (such as those noted in the example above) and identify with certainty if Babesia, Bartonella or both exists in the slide — regardless of species.

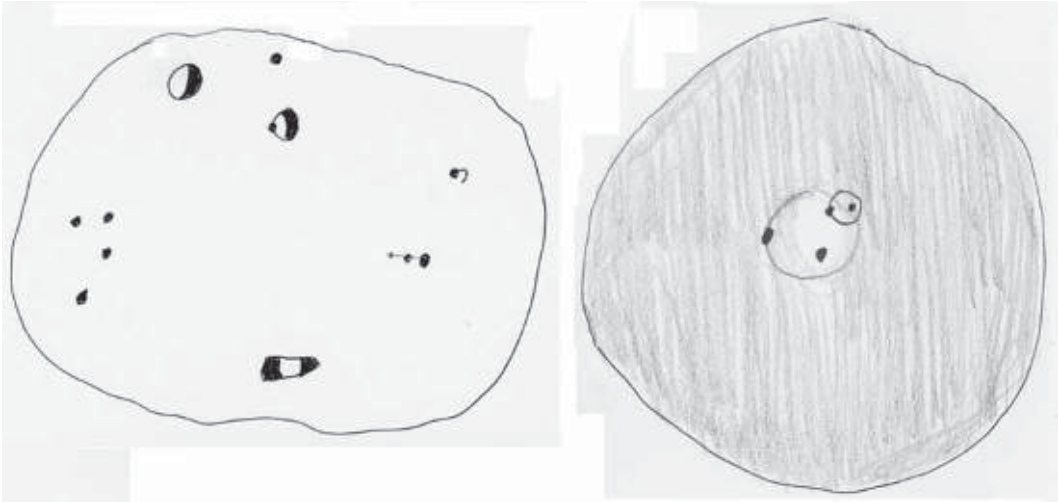
Reticulocytes or young RBCs can have these strings also. So one single finding, such as a dark, thin string, might not be 100% diagnostic of Babesia.



String of Pearls (*Babesia gibsoni*)

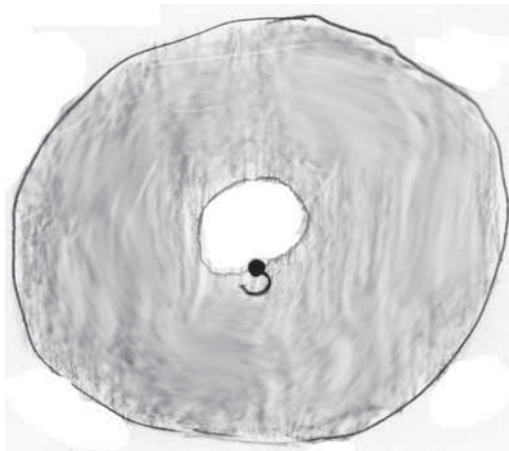


Again, Babesia ring forms are profoundly variable in contrast to malaria ring forms. Here is another set showing significant variation.

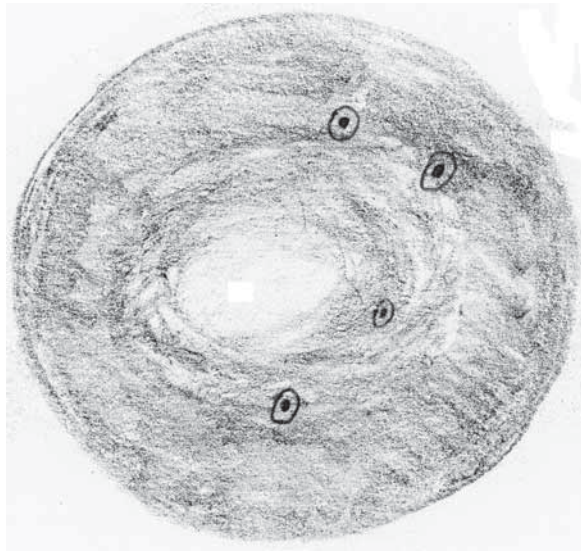


More Irregular Forms

Some are Rings and Others are Simply Eccentric Patterns

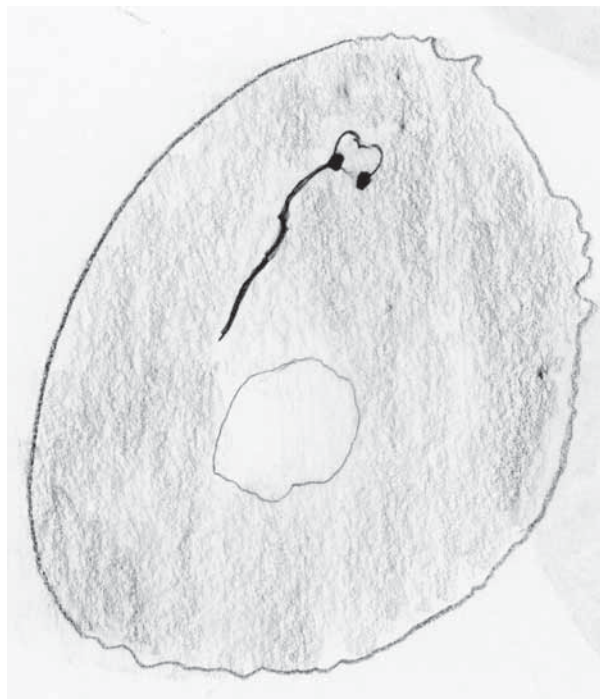


Earring Form




Eye or "Fried Egg" Cluster

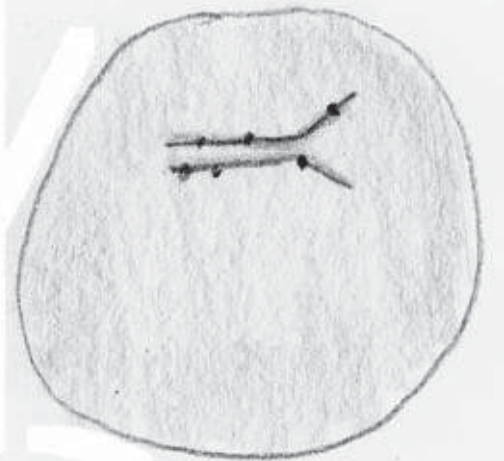
While these could be platelets, if they are **not** seen out in the blood and are only seen **inside** the RBCs, perhaps they are not platelets, but forms of Babesia clearly published in top parasite textbooks.

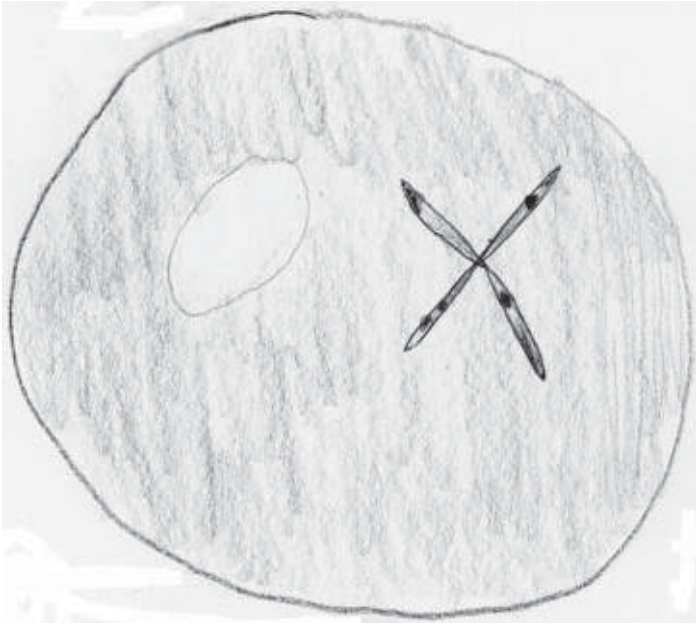


Tail Form



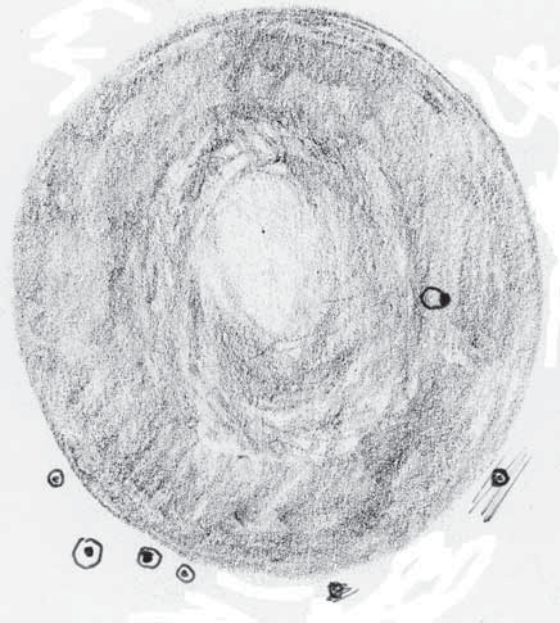
Irregular "Maltese Cross" Forms



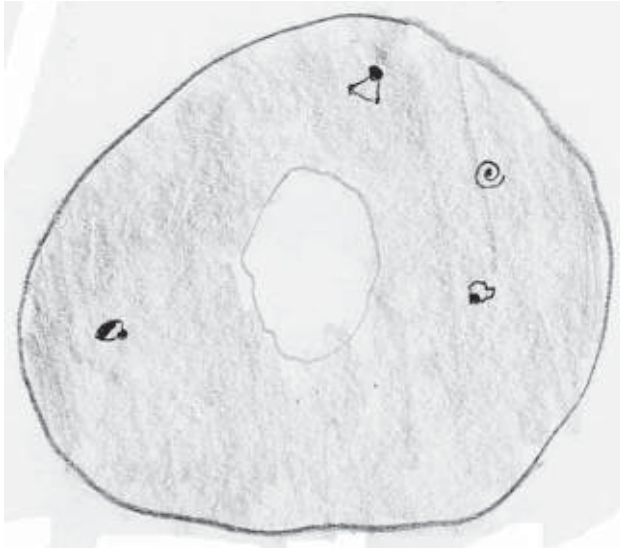


Maltese Cross Formation

This four part Babesia form is rare and should never be a primary diagnostic form.



Babesia Floating in Blood

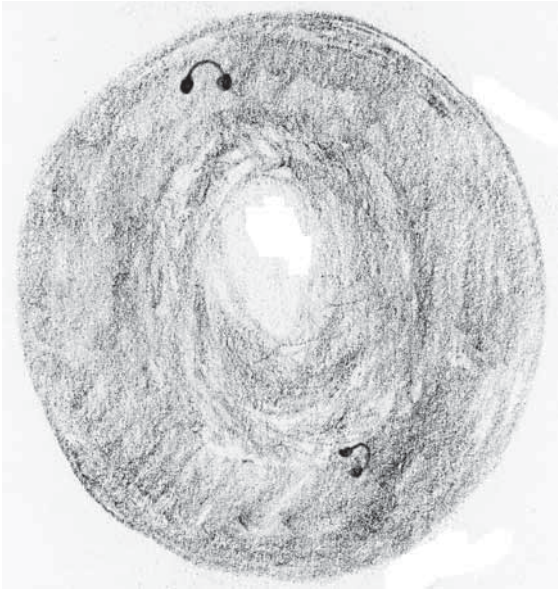


More Babesia Ring Variations


Malaria rings are highly uniform while Babesia rings vary a great deal.




Shoe Form with Chromatin Dot



Earmuff or Headphones Form

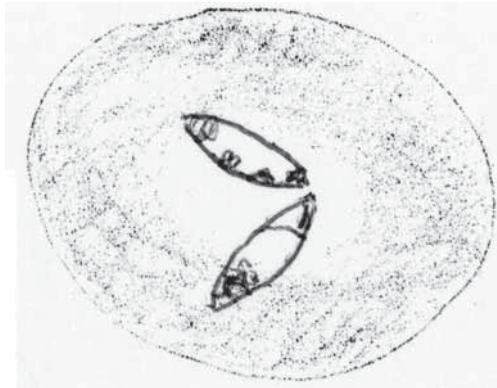


Broken Ring Pattern




Sharp Center Circle

This has an unknown significance and can simply be a routine RBC. Yet one should look carefully if a RBC center has a very sharp edge.



Mouth Form


This is typically an animal form of Babesia — at least at this time in our exploration. Some call this a “piroplasm,” perhaps because it looks crudely like a pear.




Thick Uniform Rings



Irregular Rings or Ovals



Polar Ring Form

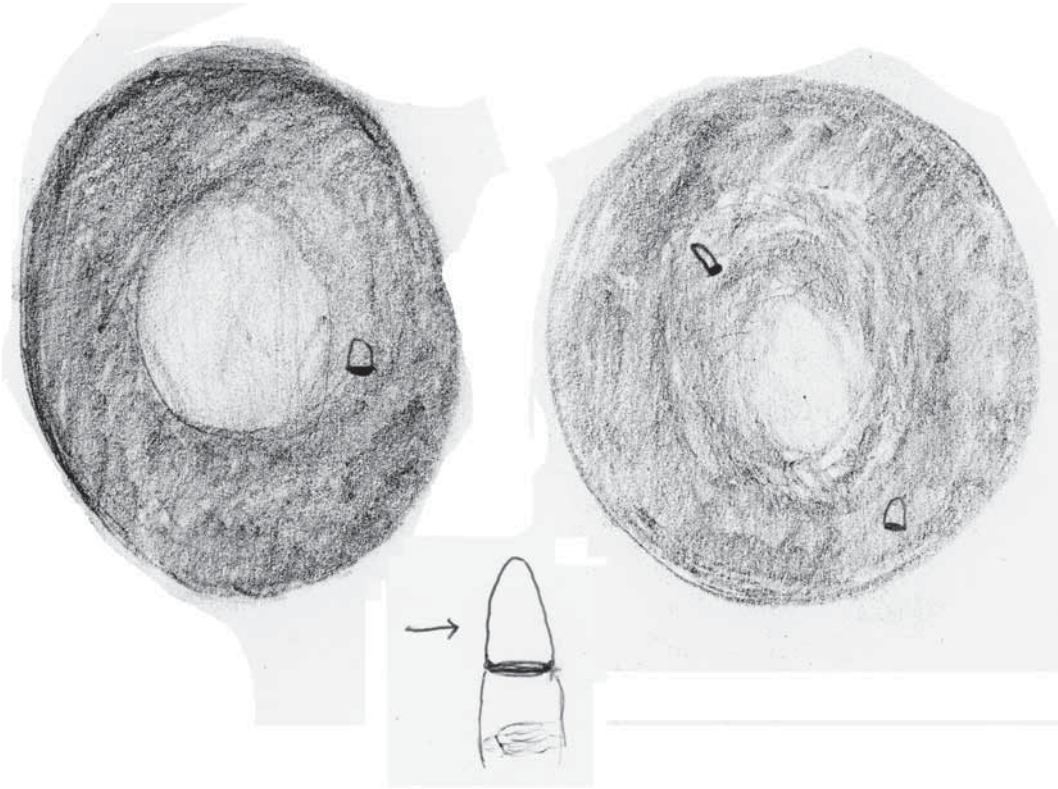


Fragmented Complex Form


Polar Oval Form



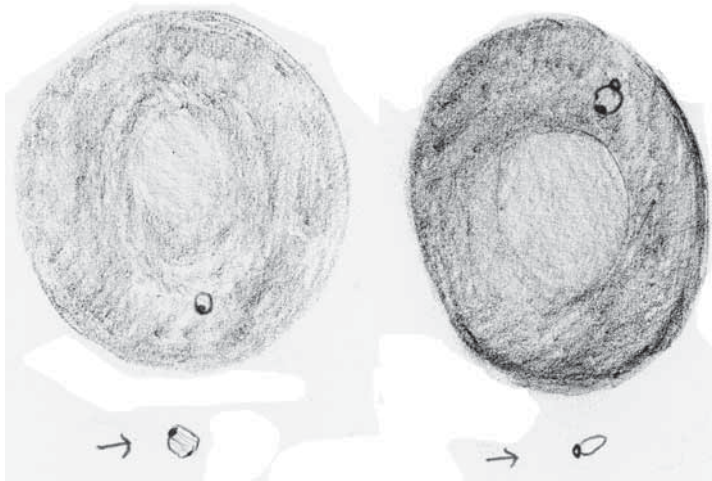
Fingernail Form



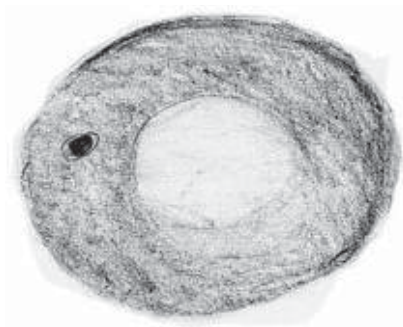
Fingernail Pattern



Free Floating Babesia Forms




More Free Floating Babesia Forms

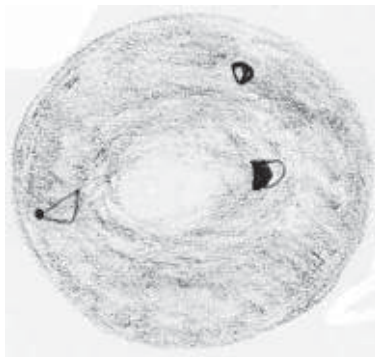


Big Eye Form

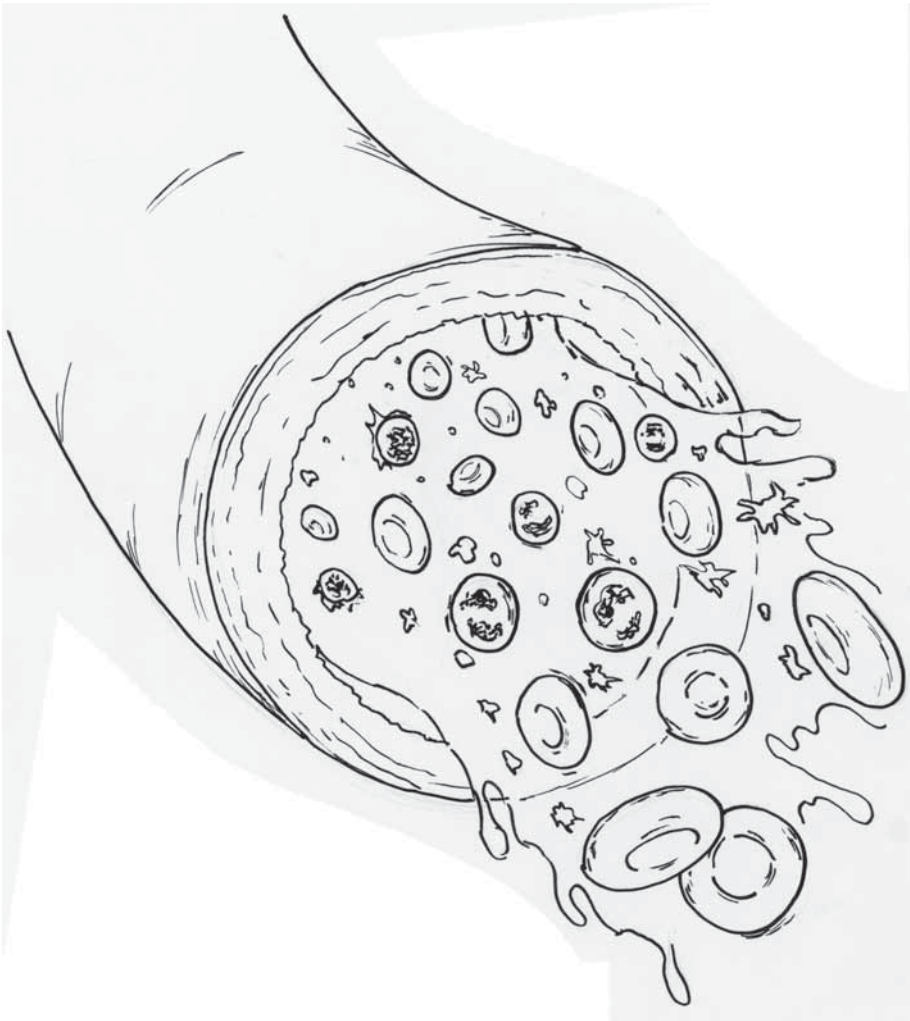If you did not see a circle around this 'eye,' it could just be an artifact.



Double Eye Form

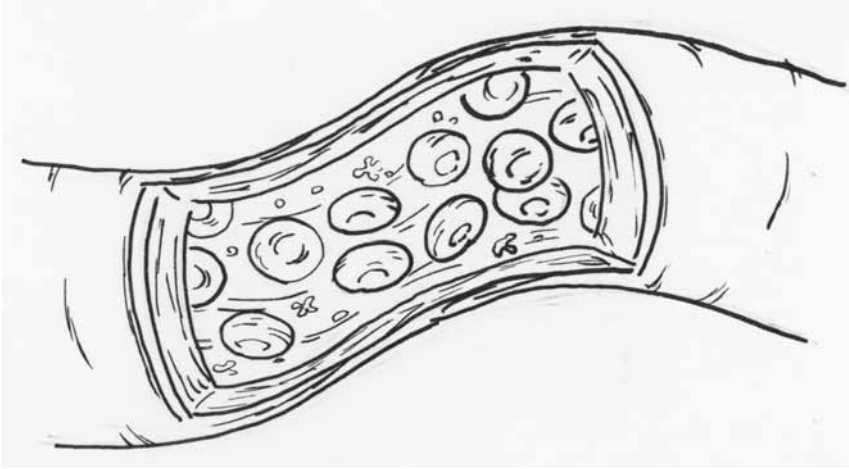


Harp Forms



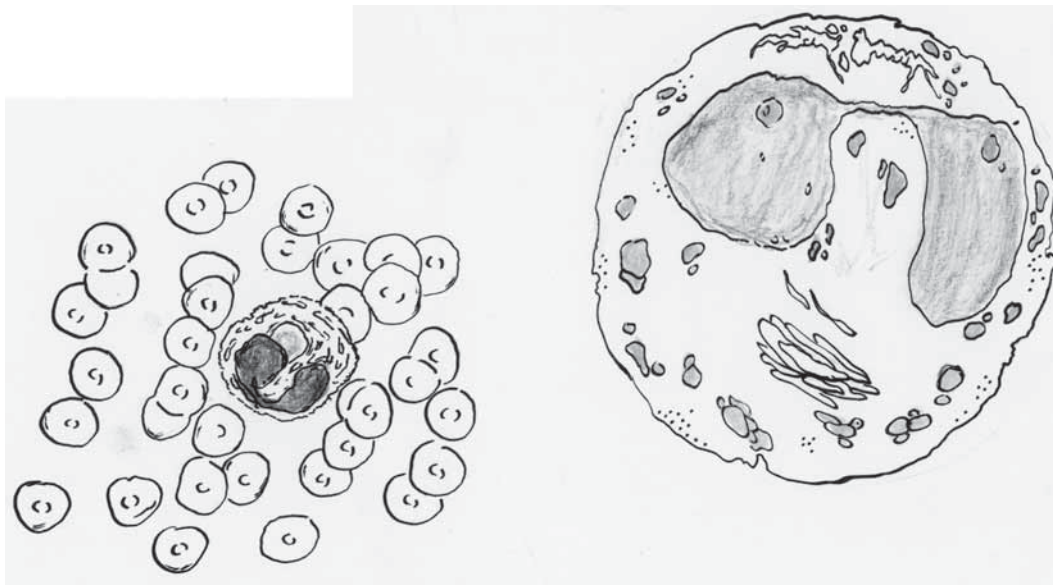
Babesia Clots

I believe that Babesia increases clotting and is therefore an underlying cause of death that remains almost completely overlooked.



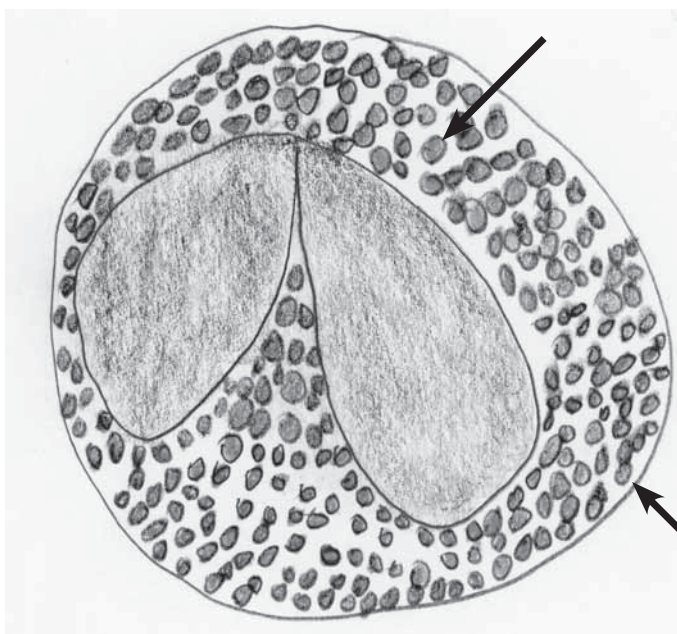
Babesia Clots— Point Two

Coronary arteries are narrowed by fat on the artery walls in virtually all Americans. Babesia can potentially worsen poor or abnormal blood flow in the coronary arteries and can also cause micro clots in the capillaries of the brain, kidneys, retina and other organs.



Eosinophil Images

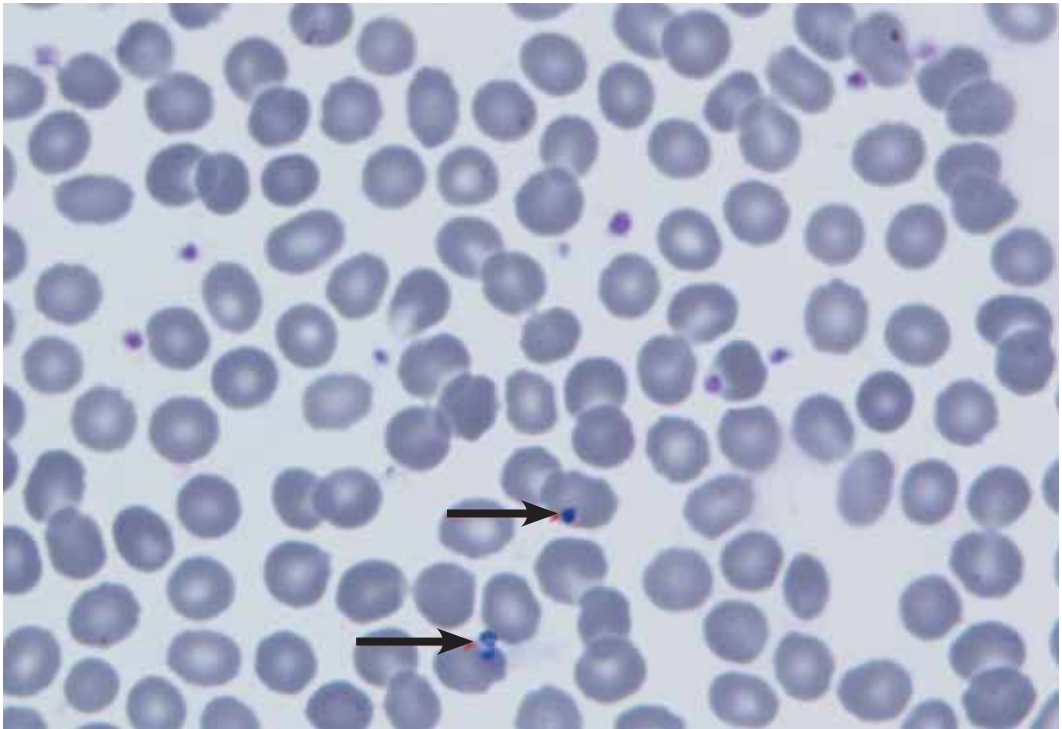These specialized white blood cells are designed to kill parasites like Babesia in the body.



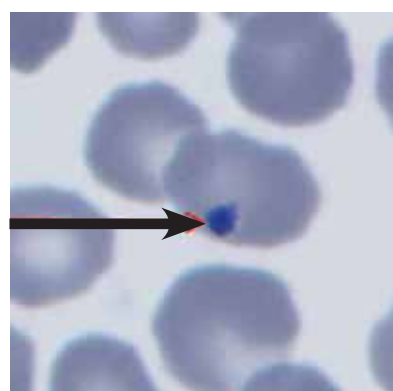
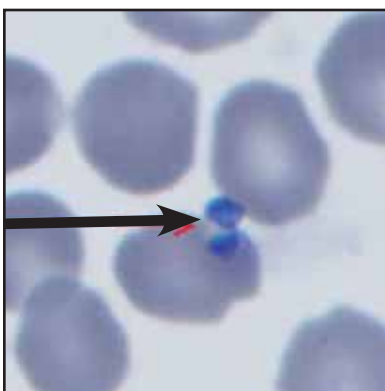
ECP or Eosinophil Cationic Protein

Eosinophil Granules contain powerful chemicals like ECP designed to kill parasites. One can use certain anti-Babesia medications to ignite their release to test for the presence of very low levels of Babesia.

Babesia Images with Commentary

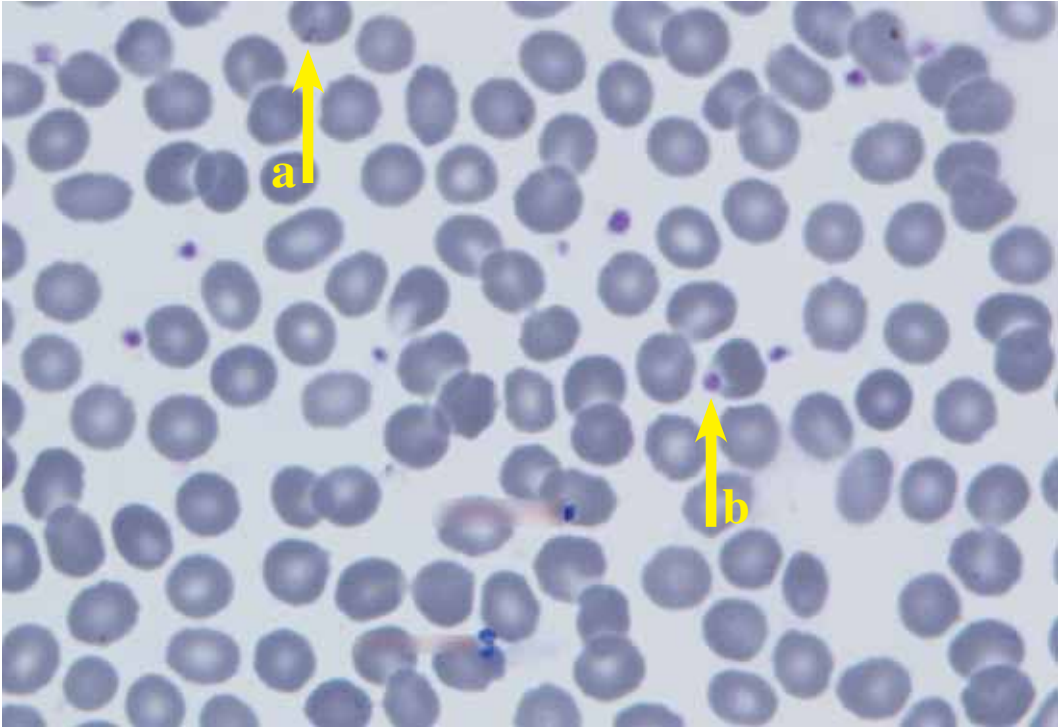


A blood smear derived from a patent pending Fry stain. The arrows point to two highly pigmented items.

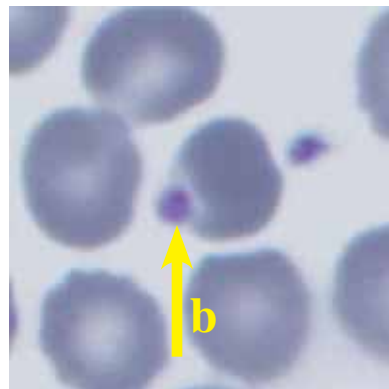
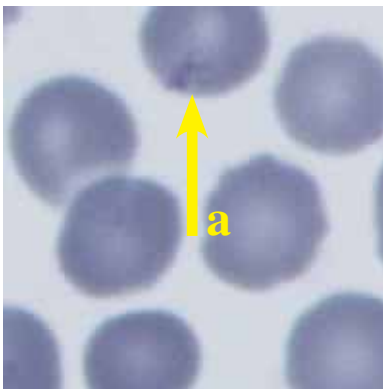


These are not clear Babesia forms.

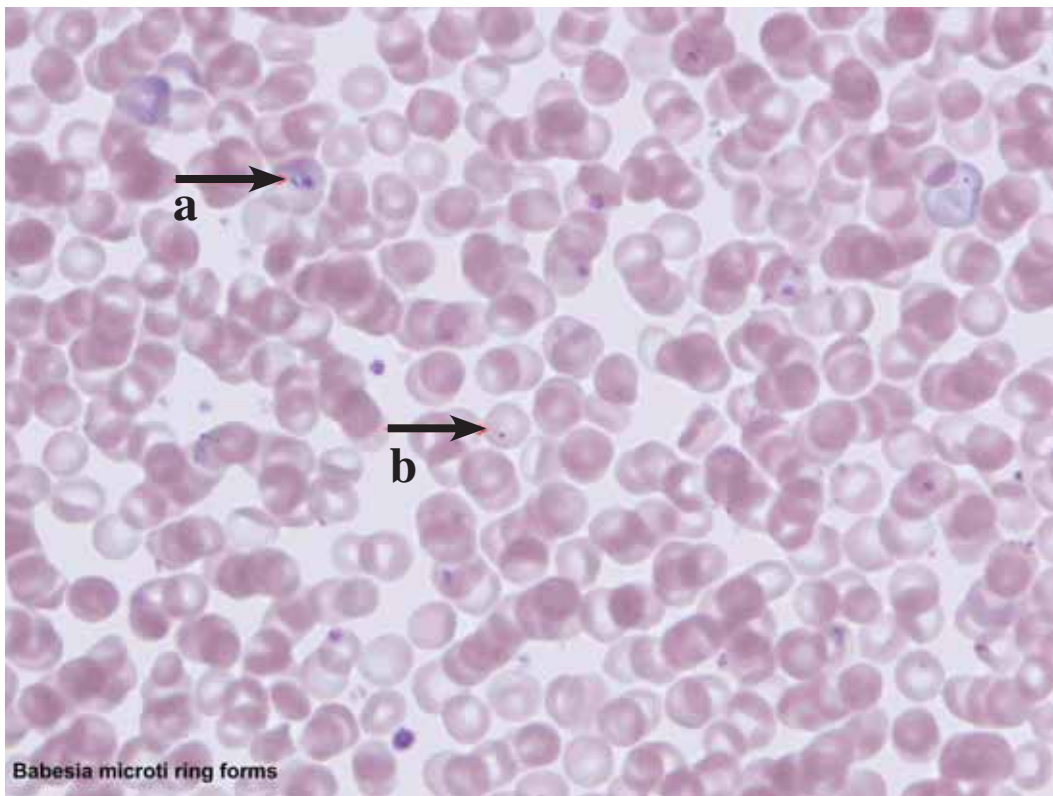
The individuals who provided the following slides, unless marked otherwise, were Jeremy Bresette, John Voss and Stephen Fry, M.S., M.D..



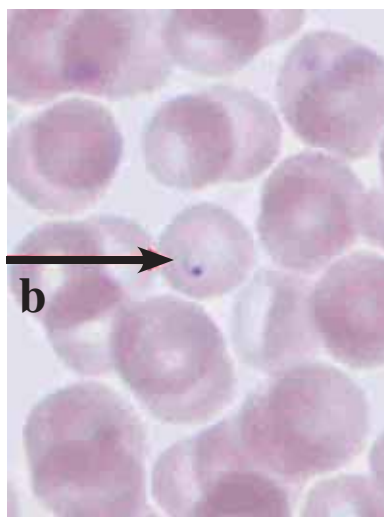
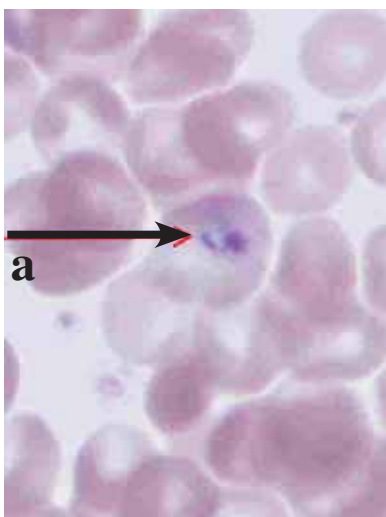
Here is a complex slide. Is Babesia present?



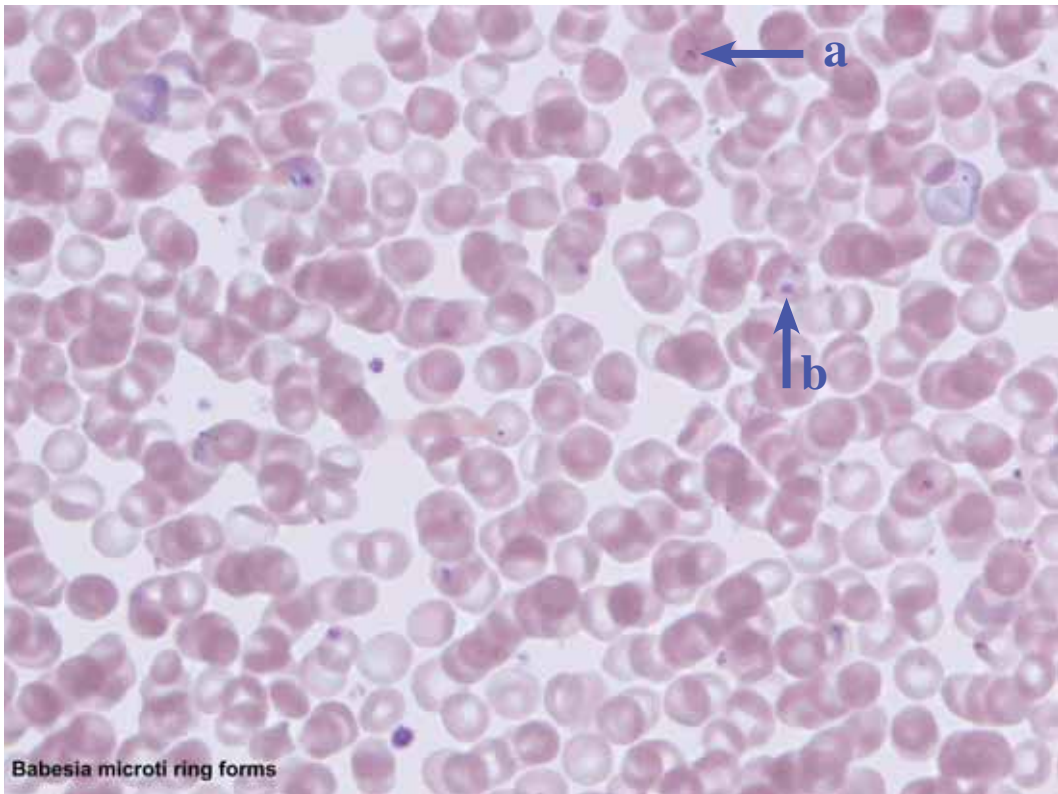
- a. This complex, dark twisting pattern, similar to the second to last FISH image, might be a Babesia form. Some might say these strands are the same size throughout, and that this is an immature RBC or reticulocyte.
- b. This is probably a platelet. It has a dark spot but the general shape is box-like. I have not seen this shape in Babesia images.



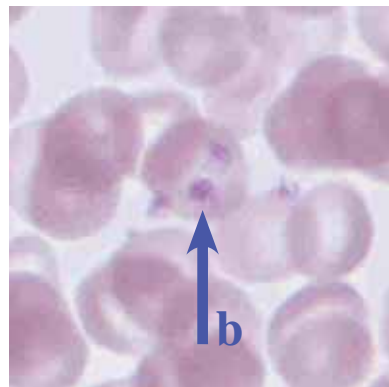
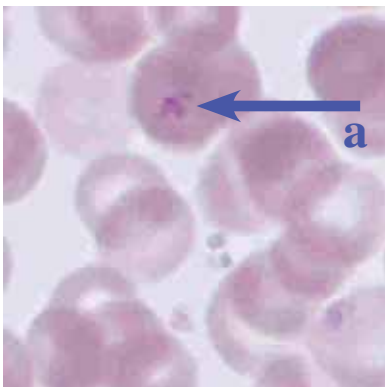
Fry Clinical Labs believes this slide shows Babesia.



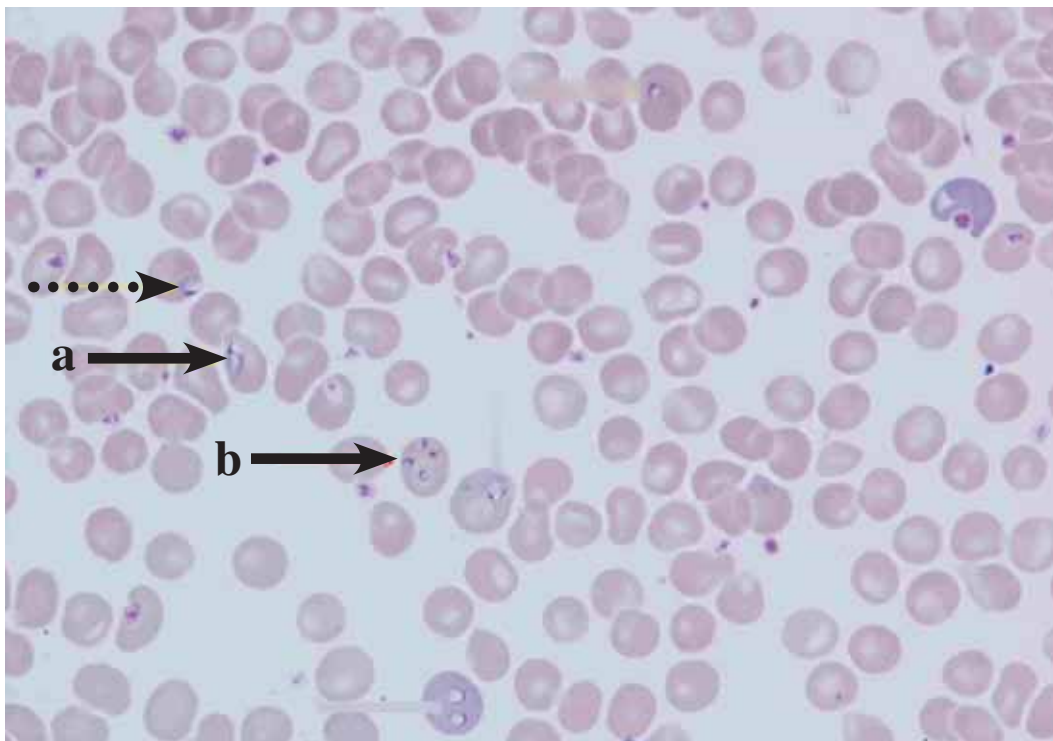
- a. Clear ring. In our sketches we have called this a dangling ear form.
- b. A classic and obvious ring form in a child who was told she had no Babesia based on a smear read “manually” by a local hospital lab.



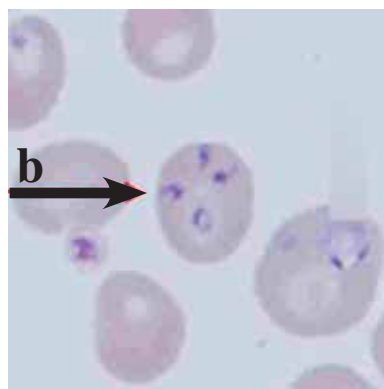
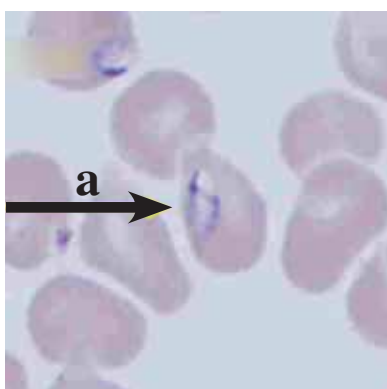
Many borderline Babesia forms.



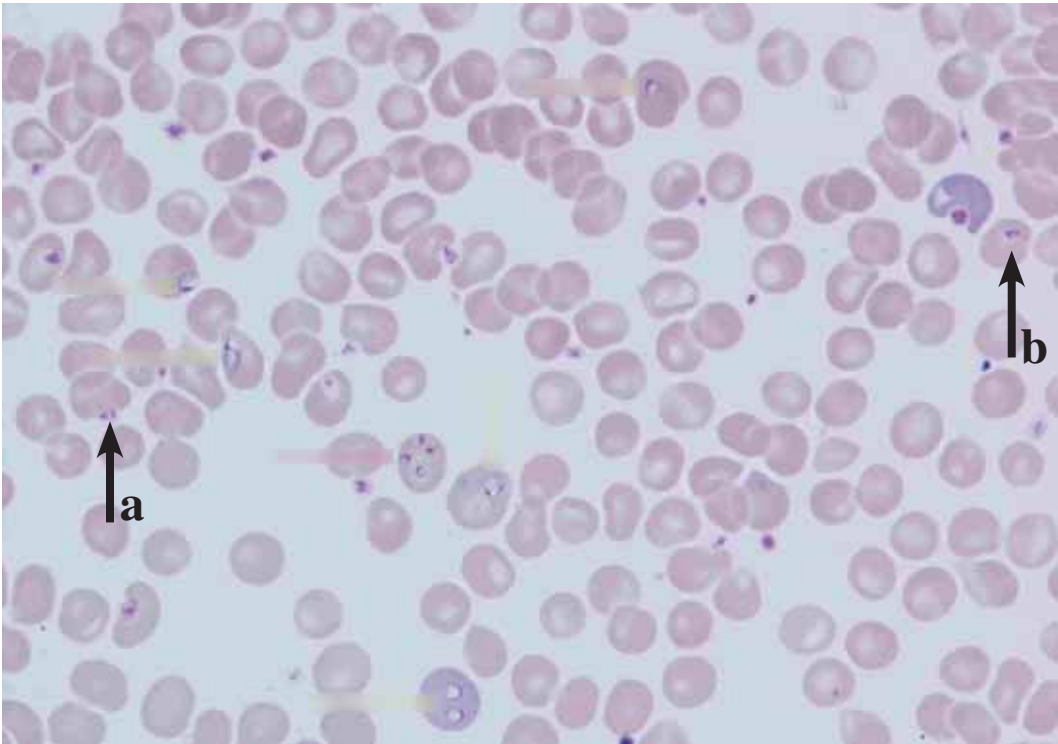
- a. One encyclopedia has a Babesia form that looks exactly like this form and it is called a “zygote” form. It might also be a platelet.
- b. A platelet, a RBC fragment or a “zygote” form.



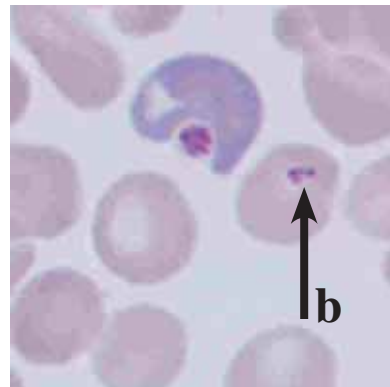
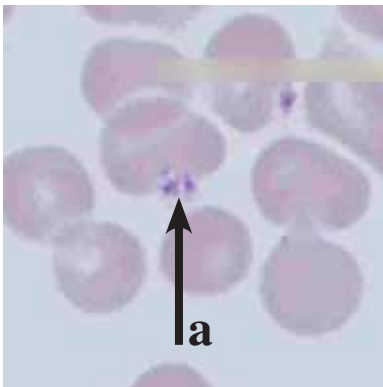
A slide with many Babesia findings, all of which were missed by a major large national laboratory, who were asked to look for “malaria or Babesia.” They missed all of these findings. The arrow with a spotted tail is pointing to a classic Babesia ring form.



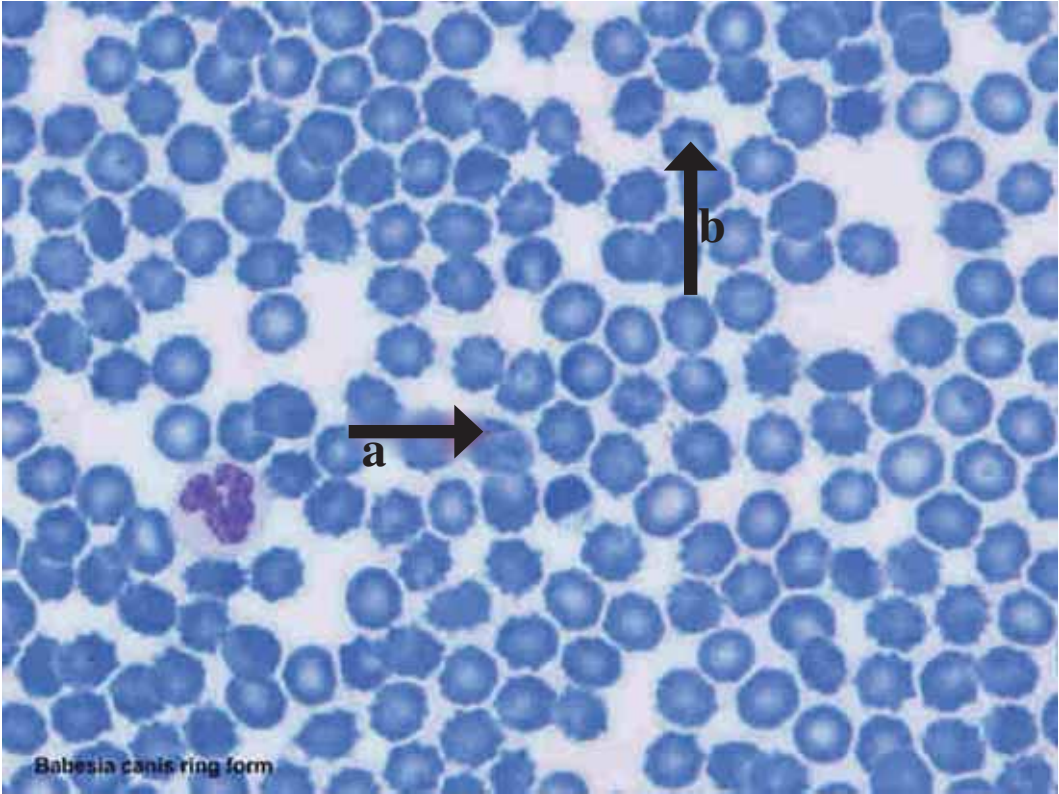
- a. It is unclear how many Babesia particles are in this complex form. I would propose it is two Babesia particles which are fused, but it is not clear.
- b. This example, shown in past sketches from many parasite textbooks and respected web sites, is actually four Babesia forms.



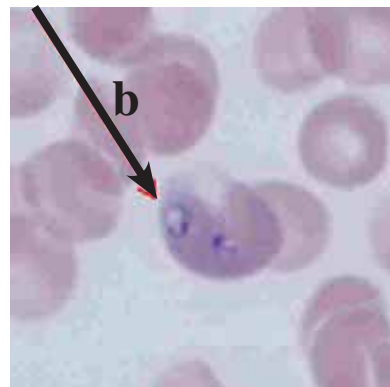
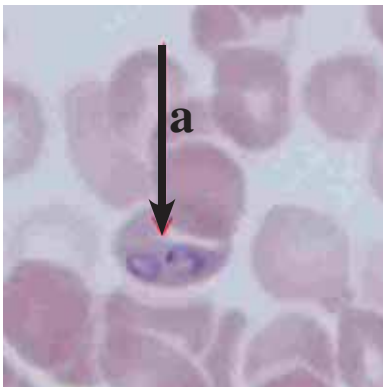
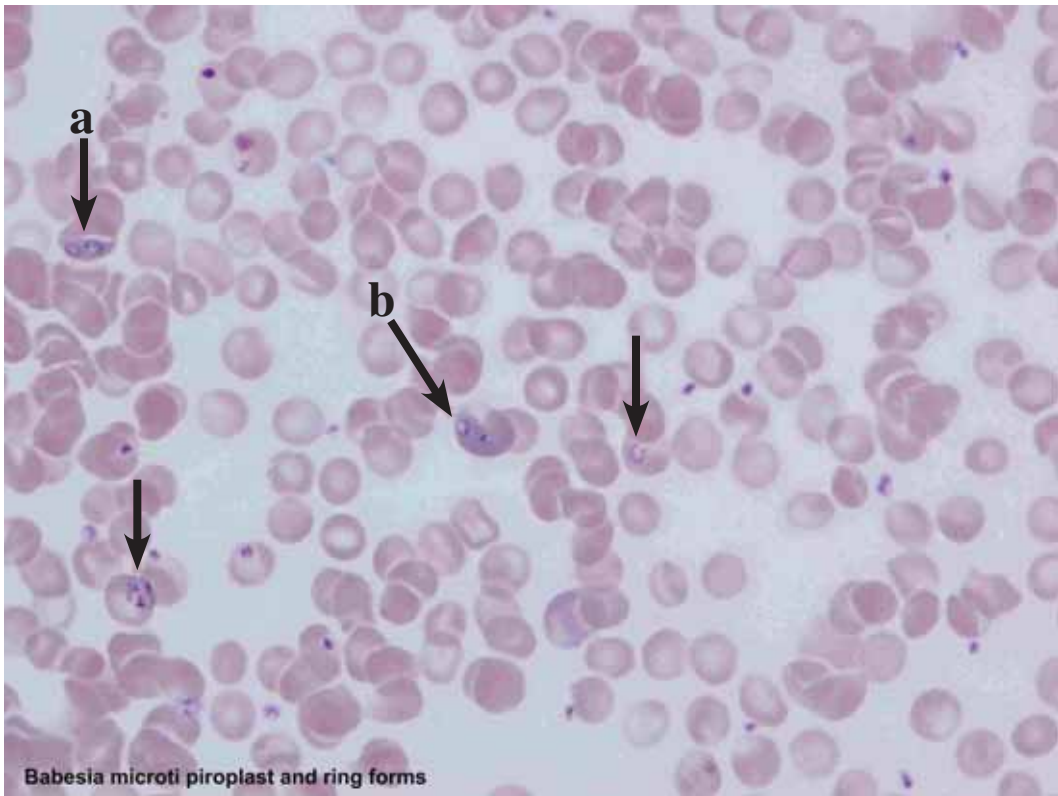
Again, this is a very complex slide. Some particles are certain Babesia and others are unclear.



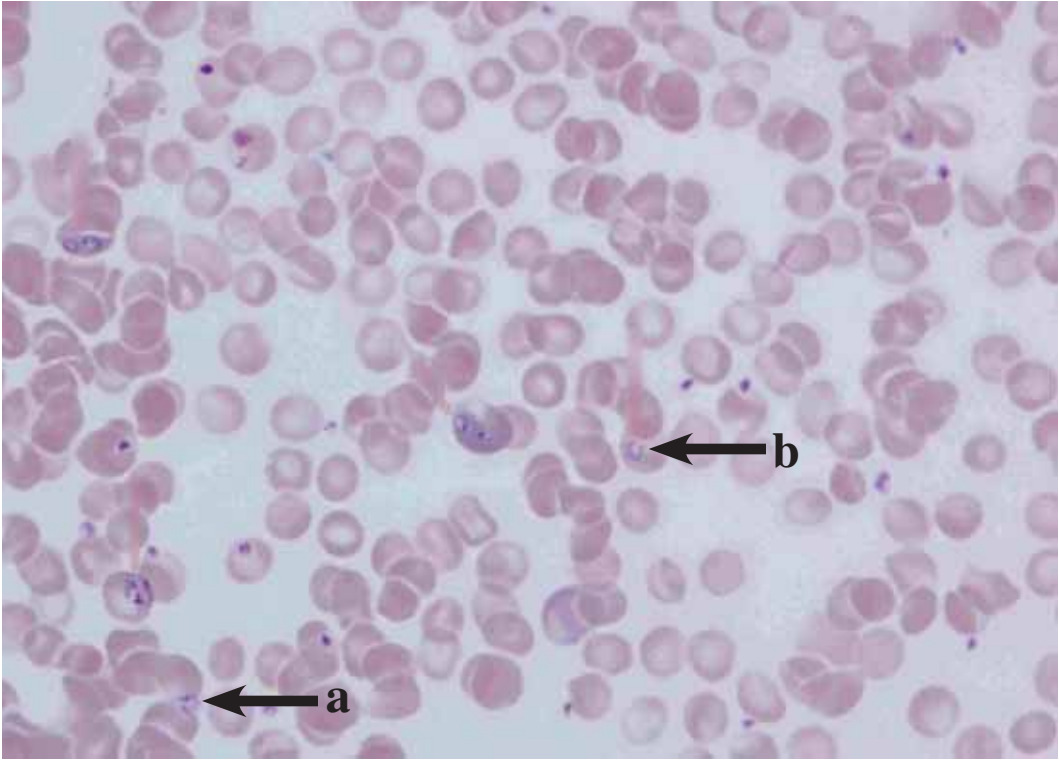
- a. I propose that these are two to three piroplasms.
- b. A triangle form or a ring shown in past sketches from many parasite textbooks and respected web sites.



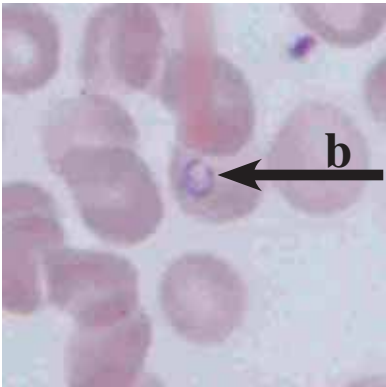
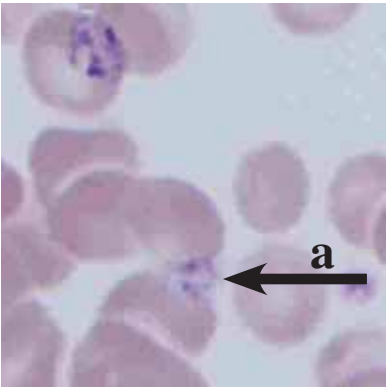
Can you see the ring forms in this routine blood smear? Try using your magnifying glass.



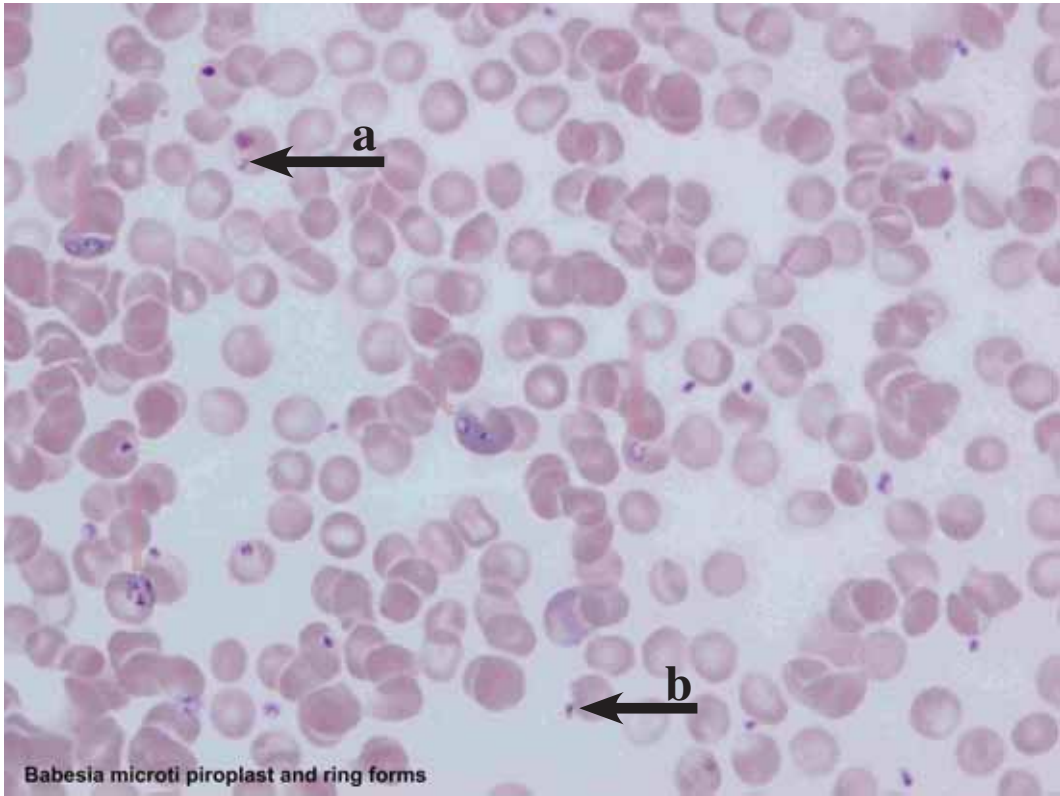
- a. Piroplasm forms which look like pears.
- b. Ring and piroplasm forms.



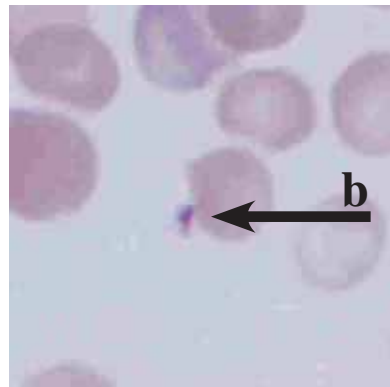
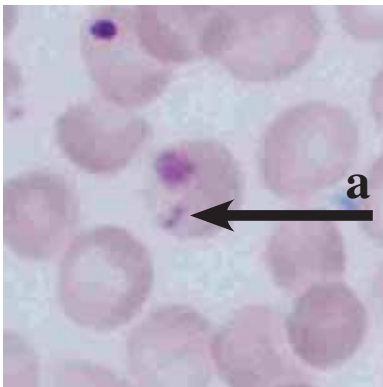
Amazingly, this slide which was reported as being free of protozoa, e.g., Babesia, has still more examples in this single visual field.



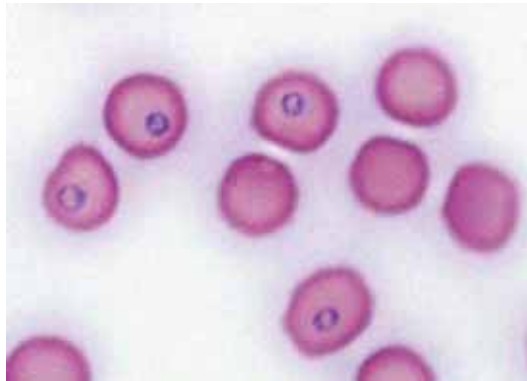
- a. A headphones form.
- b. Ring form.



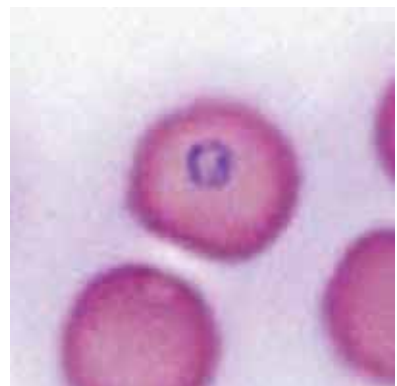
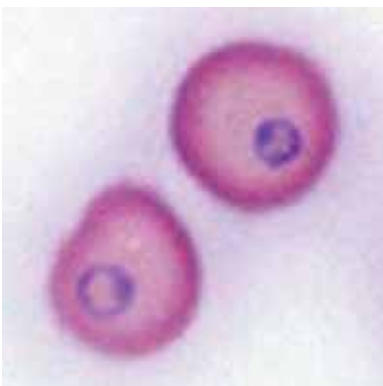
Same form in many places.



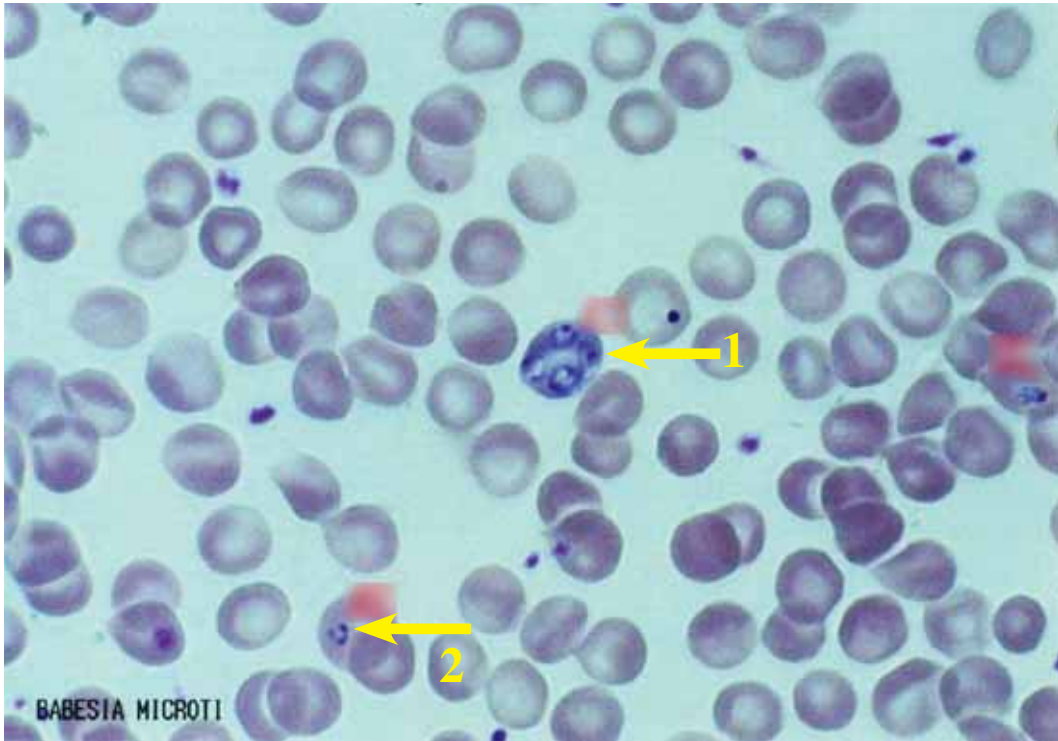
- a. An infectious Babesia merozoite or a platelet.
- b. A merozoite or platelet.



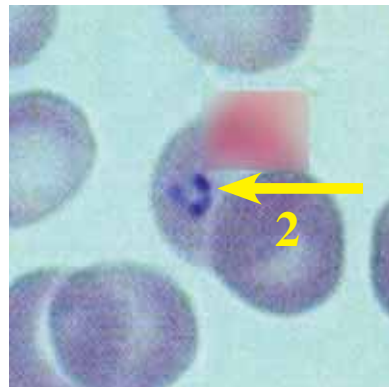
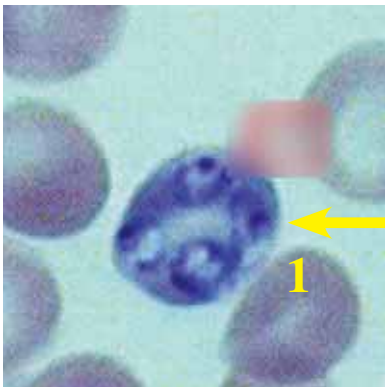
This blood sample is from a cat and was prepared with a Wright-Giemsa stain. Note the vivid intracellular piroplasms with erythrocytes (RBCs) in a feline blood smear.



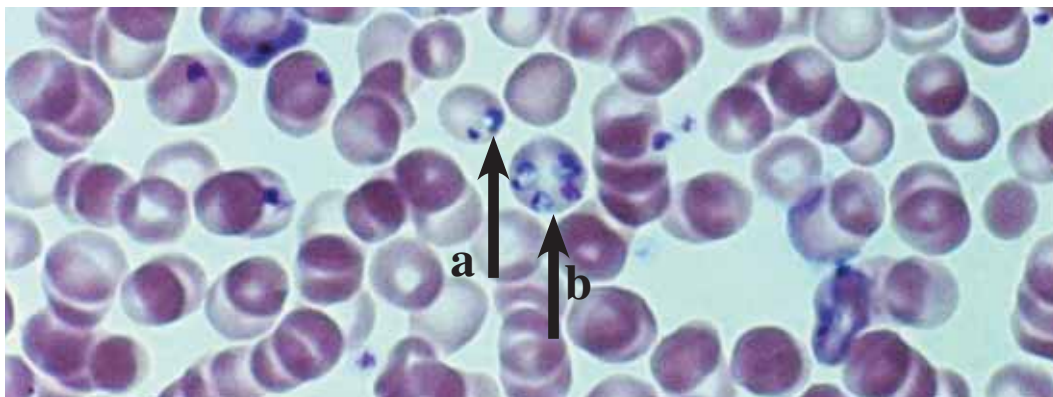
Same slide as above with two areas enlarged to amplify the profound obviousness of these Babesia forms. Unfortunately, under a regular microscope, unless it has computer enhancement software, the RBCs and rings are not this large and are harder to see. One purpose of this book is to help with the recognition of Babesia when dealing with enhanced slides. Another purpose is to help those viewing RBCs at 1,000x **with no software enhancement.**



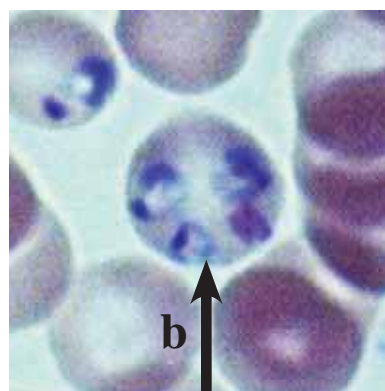
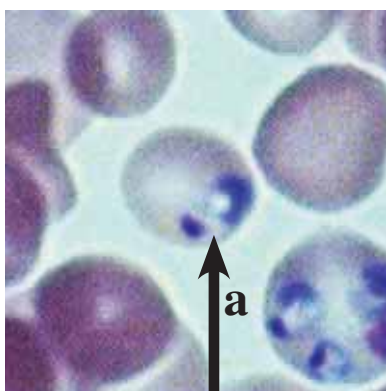
Two very different patterns are seen in this slide.



1. Four ring forms fill most of the RBC, again showing that rings can be large.
2. Here is a Babesia earmuff or headphone form.



Arrows show ring forms of various sizes.



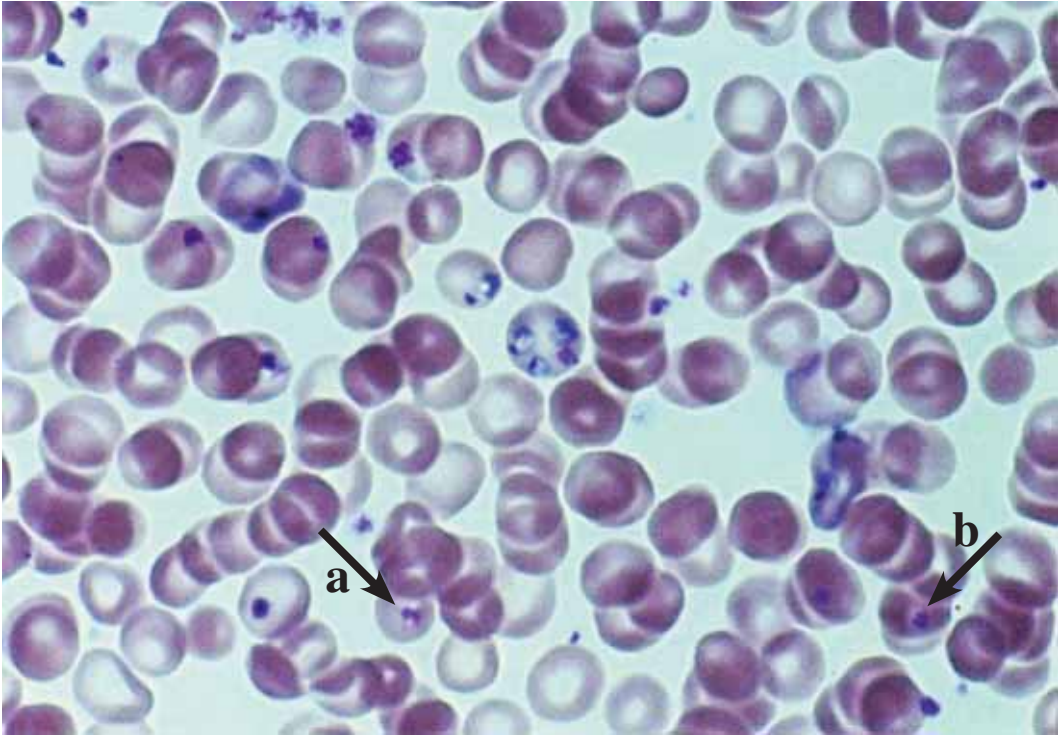
- a. Two crescent with markedly different sizes.

Both of these two crescents have areas of very dense DNA or chromatin which stains darkly.

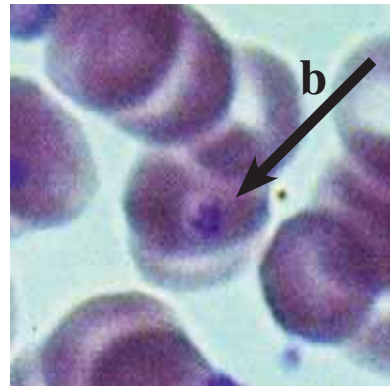
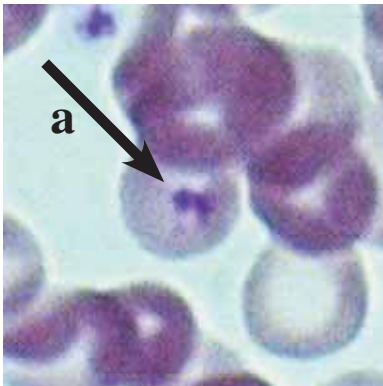
- b. Four forms of Babesia with markedly different shapes. When they are enlarged, one form looks like a simple pear at the 6 o'clock position.

The form at the 4 o'clock position is probably a Babesia form because it sits among three other clear Babesia forms, despite its resemblance to a literal high DNA dense square.

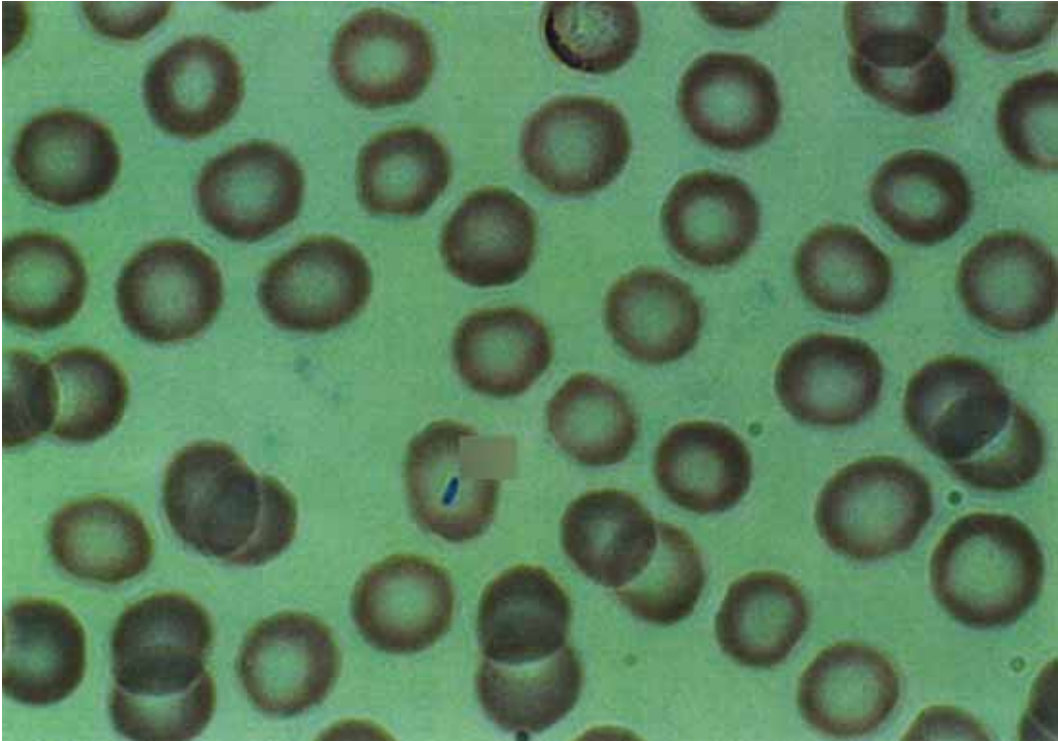
The form at 3 o'clock has a dark roof look due to its high staining chromatin, and this is not a form routinely seen in any Babesia book, perhaps partly because you would have to enlarge the image with a computer.



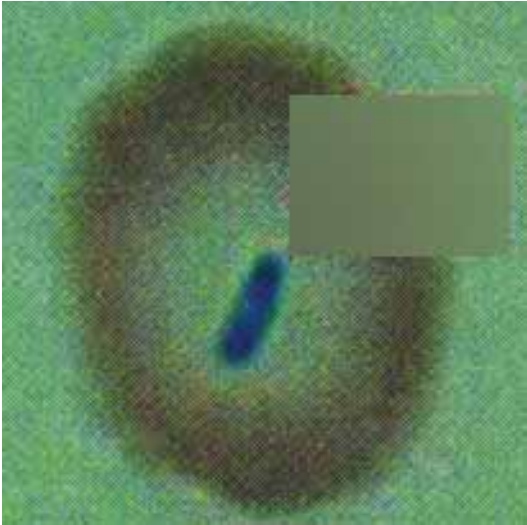
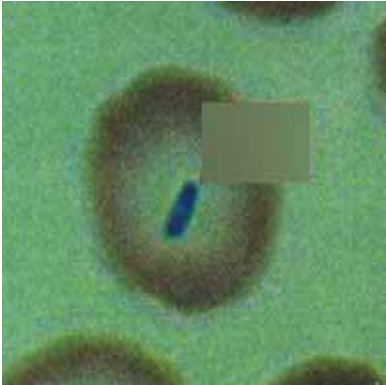
Diagonal arrows point to two very complex Babesia forms.

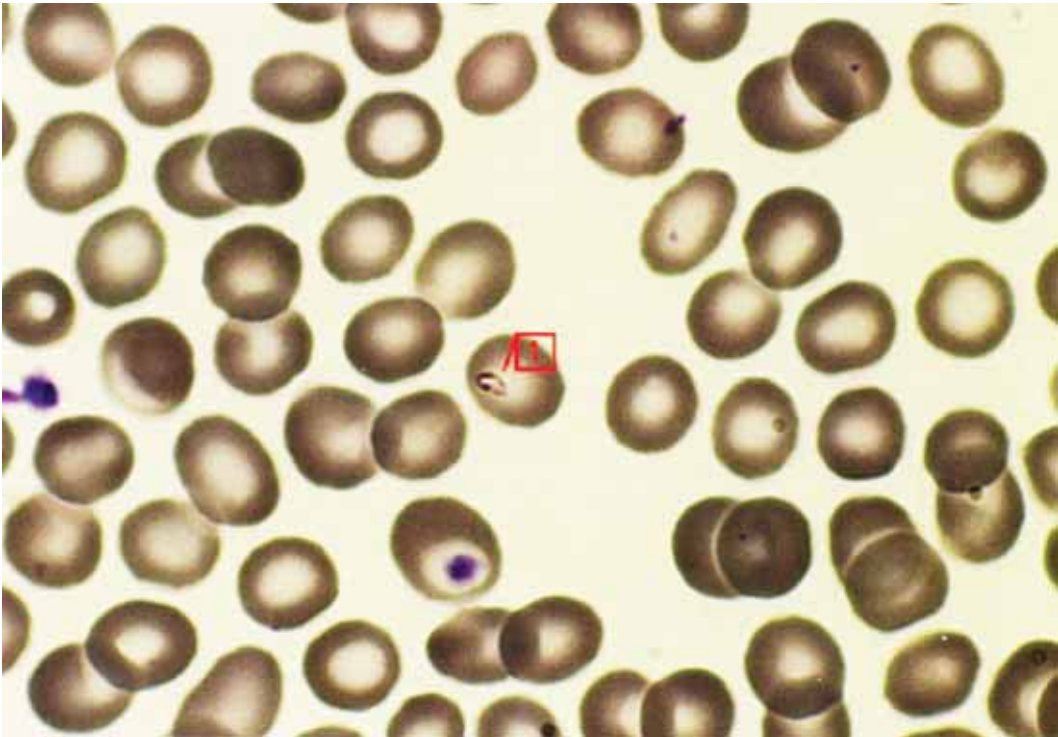


- a. This Babesia form looks like a white hotdog with two dark olives in the center. Perhaps it is just one merozoite with dark DNA clumps on either side. It could also be two Babesia forms fused together.
- b. This dark crown shaped form is found in many slides flooded with Babesia. I feel it is a unique complex Babesia pattern.

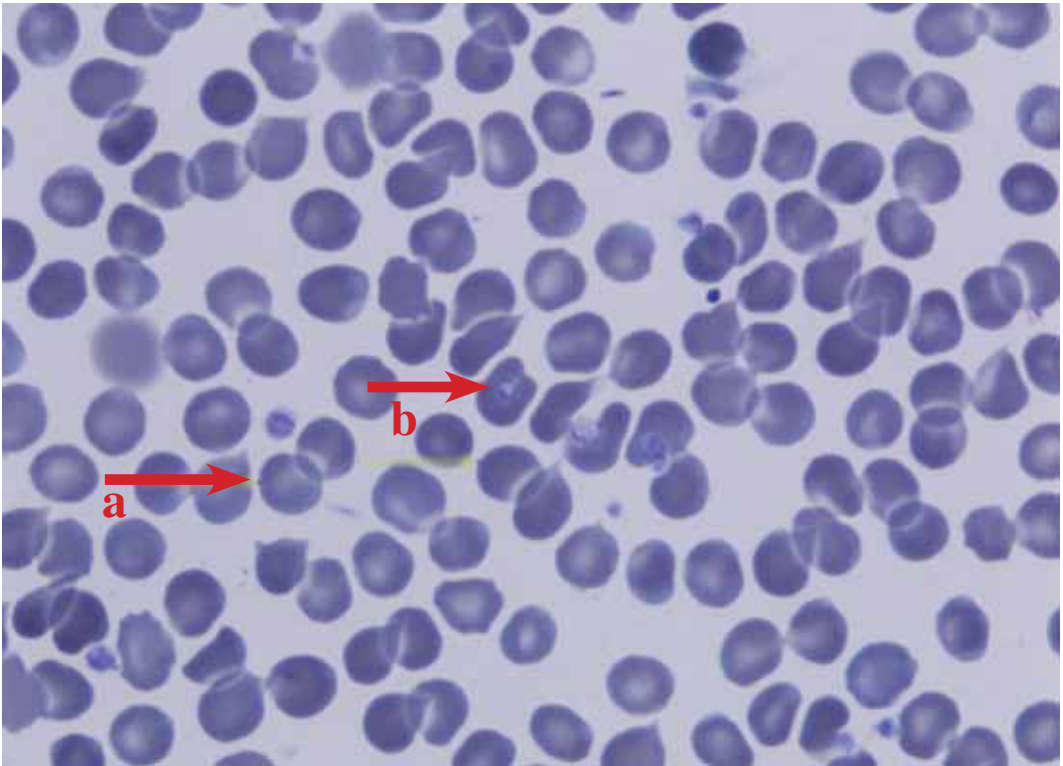


One microbiologist believes this is a ring form (side view) or a linear slit form. The top and bottom poles look darker than the center.

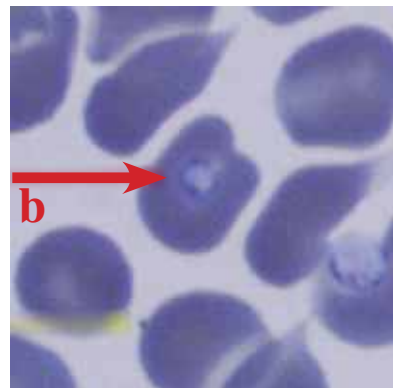
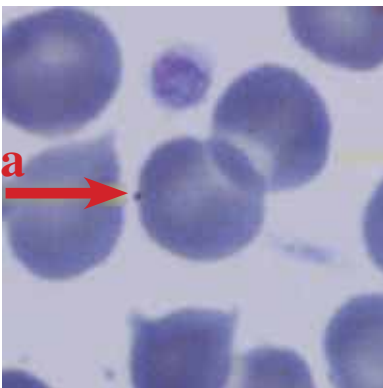




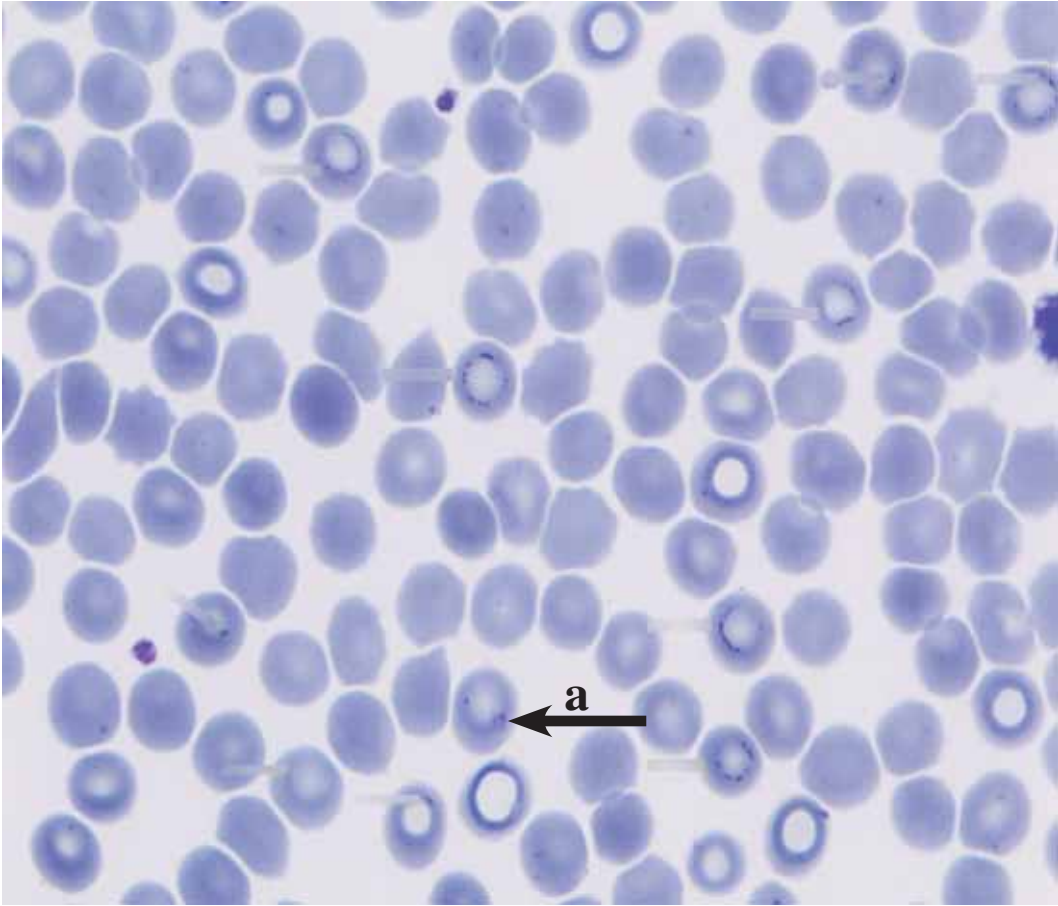
A clear solitary ring form with an oval shape. I wonder how long it would take a laboratory technician or pathologist to see this if it was only found in every 2000 cells?



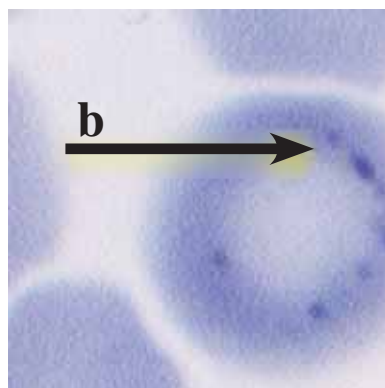
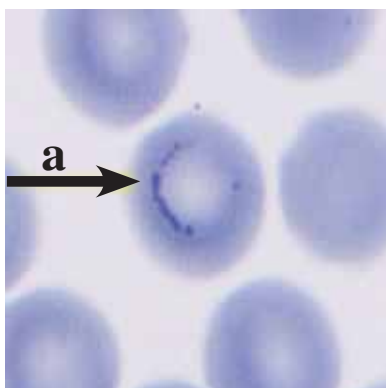
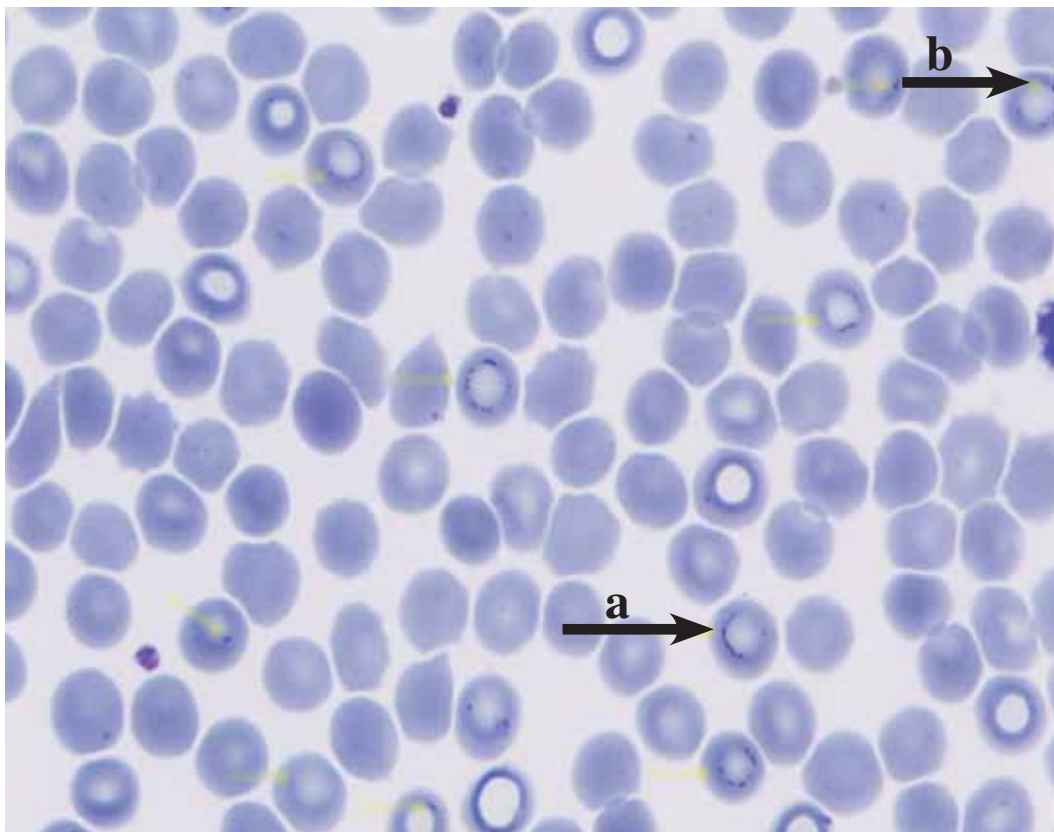
Complicated slide requiring careful examination due to the probability that more than one organism is present.



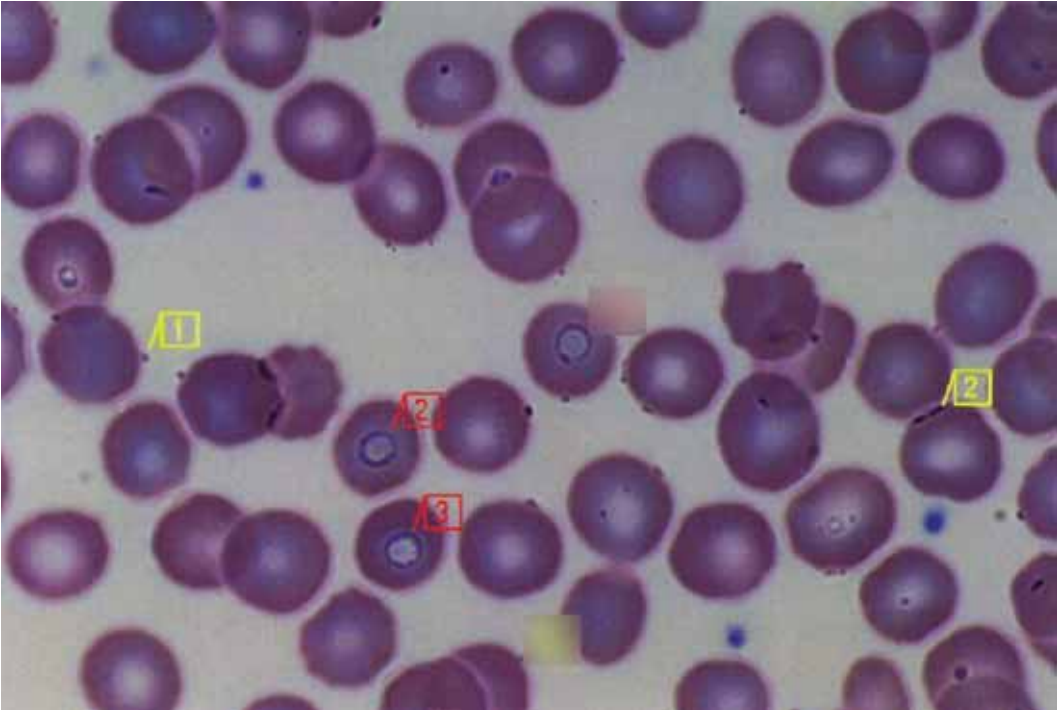
- a. This tiny round or oval infection is likely one of many *Bartonella* bacteria in this slide.
- b. A routine standard trophozoite *Babesia* ring stage which is presented in this manner in over 20 source textbooks, journals or parasite slide collections.



Arrow shows a likely tiny micro ring form found with Babesia.



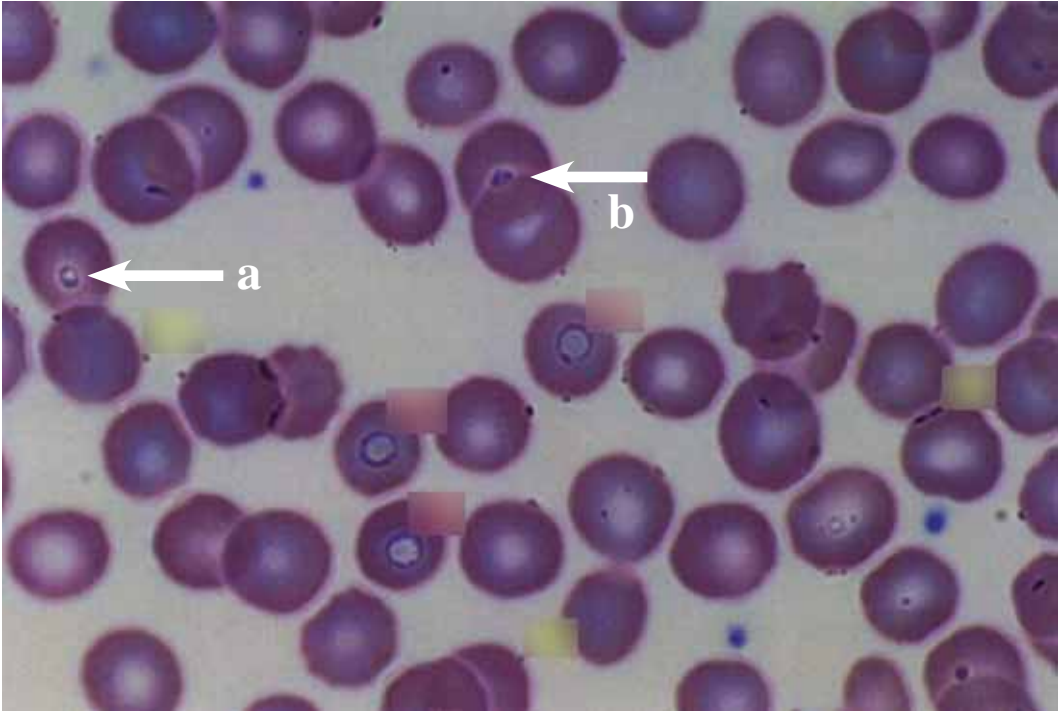
- a. This eccentric oval could represent many things. This could be Babesia with staining of dots of chromatin. It also could be a combination of Babesia and intracellular Bartonella. Some might feel it is an image seen with anemia or spleen pathology. I feel it is Babesia only if anemia, iron pathology, spleen pathology and genetic disease are all ruled out.
- b. I believe the options listed in “a” also apply to this cell.



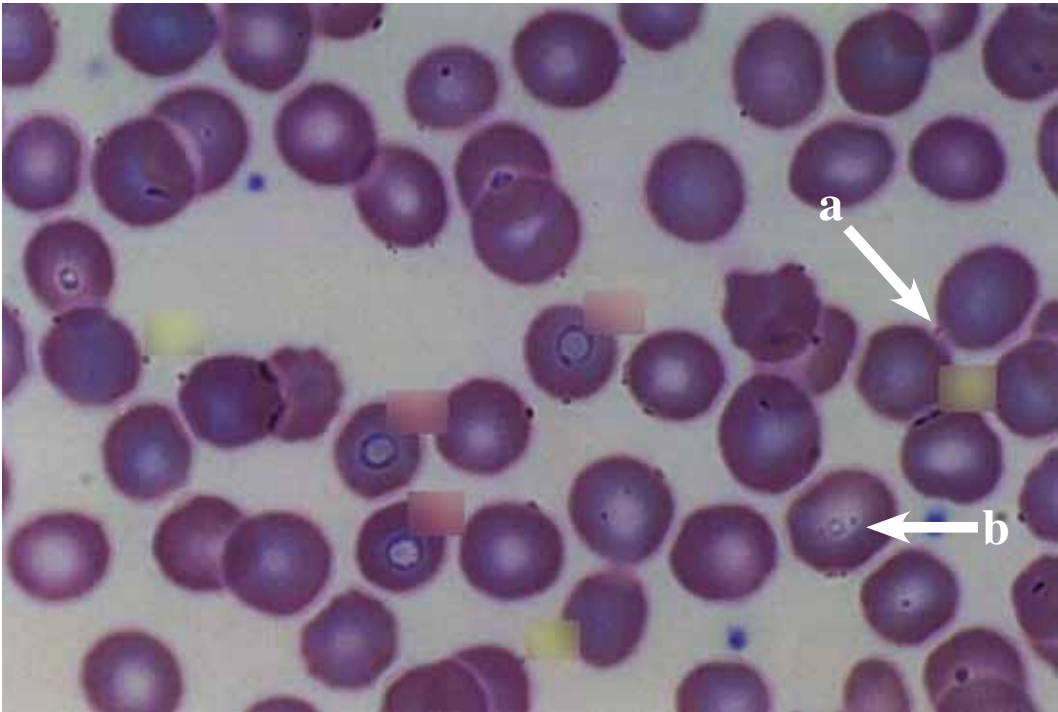
1. This RBC is marked with a boxed 1, and is profoundly enlarged by computer software, which makes a small Bartonella bacteria look large.
2. The red box marked 2 on the left side of the slide is a clear Babesia ring. One microbiologist feels this might be Bartonella, but with no evidence to support his belief. There is a profound lack of internationally available images showing Bartonella inside RBCs. Those who are knowledgeable about Bartonella rarely, if ever, have the same awareness of Babesia, which calls into question the authenticity of their identification in these cases.

The second “2” on the far right of the slide has a series of beaded dark forms. While I tend to think this is a flat Babesia form, due to the very large size of the pigmented forms, it is possible that it is a series of Bartonella bacteria in an oval presentation.

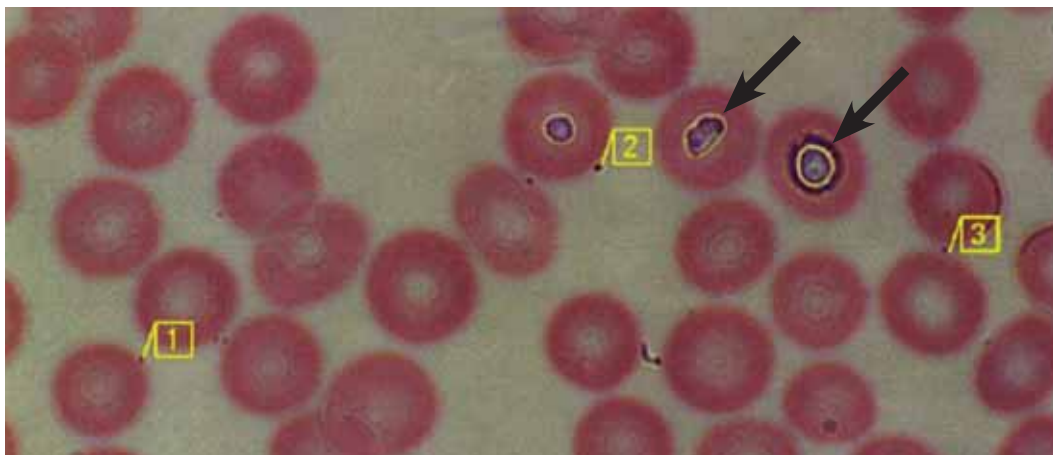
3. Classic large Babesia ring form.



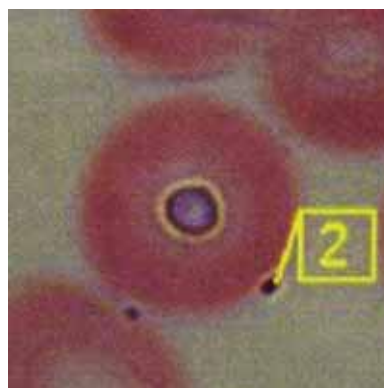
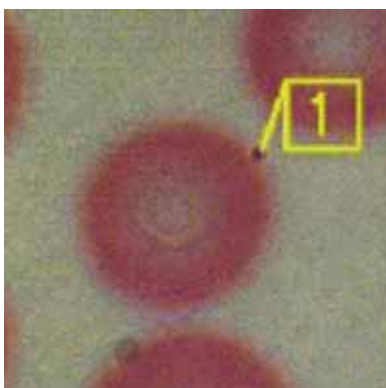
- a. Classic small ring form with irregular edges.
- b. Probably a ring form on the outer edge of the RBC.



- a. A Babesia gametocyte, merozoite or a platelet.
- b. Classic Babesia ring form. The real question is what are those two dots on either side of the ring form? I believe them to be associated with a Babesia form. It is also possible that at times these **might** be Bartonella bacteria.



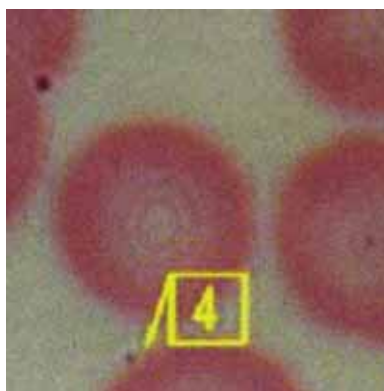
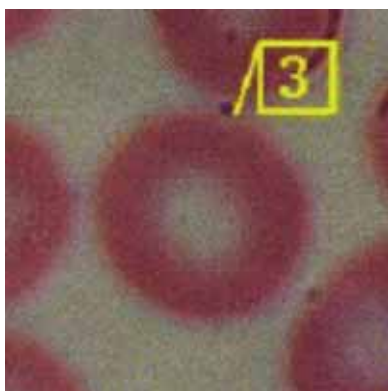
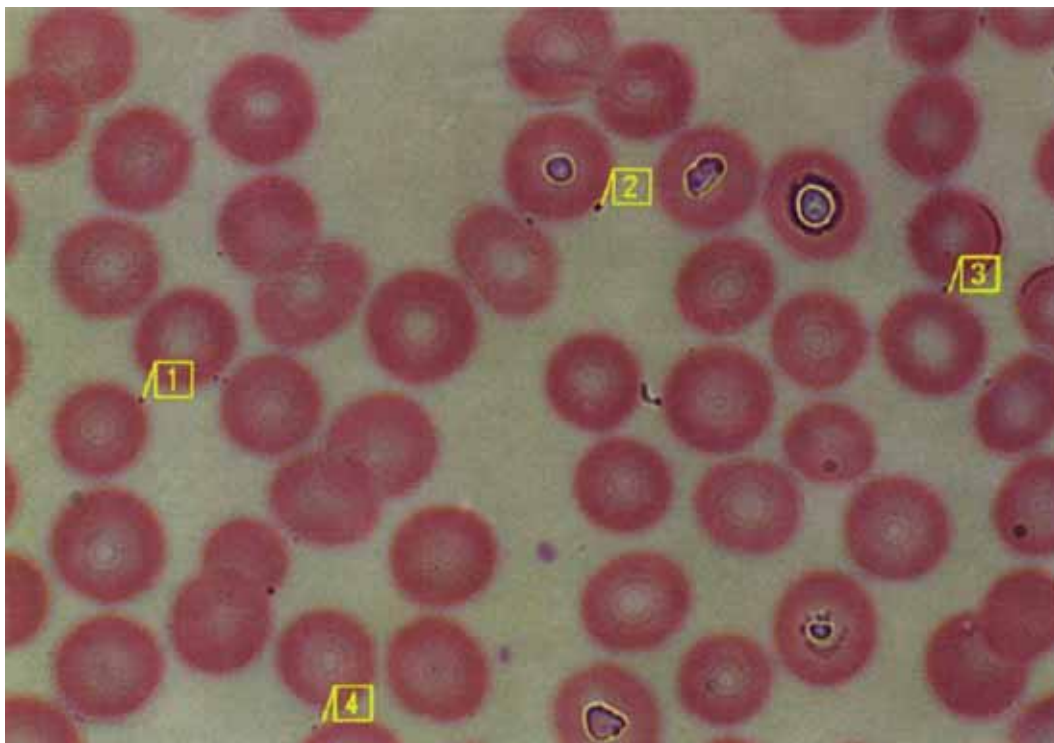
The most obvious parts of this slide are the artifact “ring shapes” which are not reliable. These might be caused by water or other substances. (They are identified by black arrows).



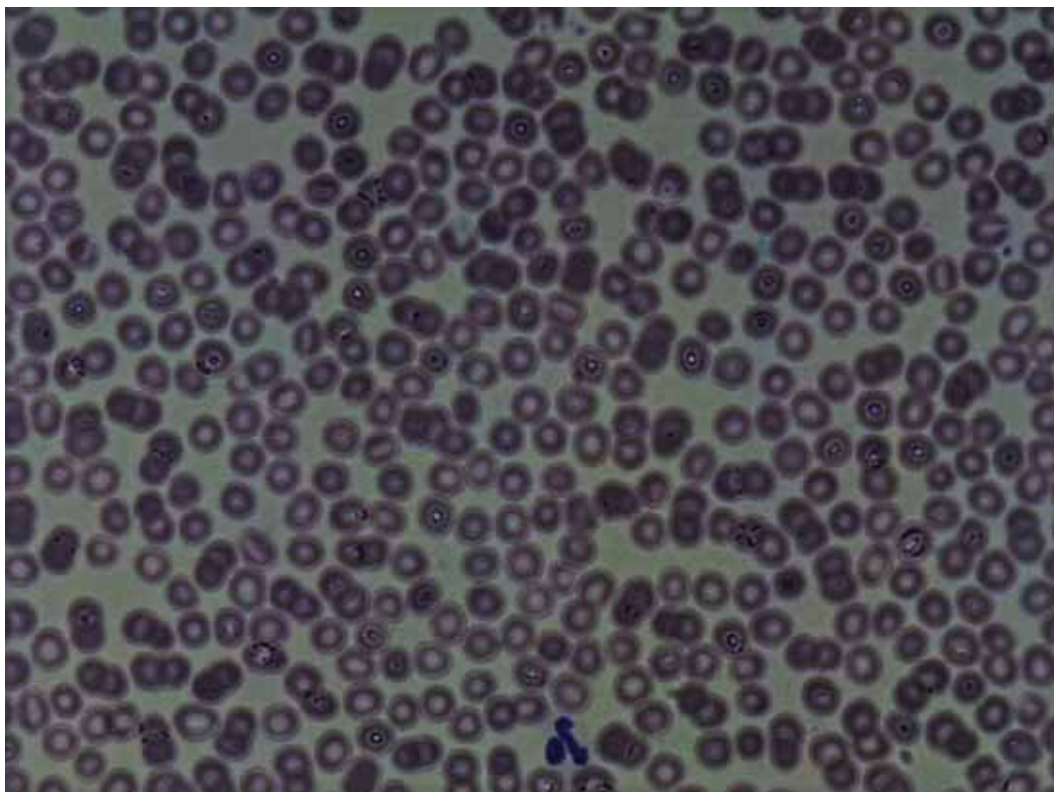
1. This is probably Bartonella because it is fairly small.
2. One problem with these dots on the outside of the RBCs is they can be extracellular Babesia or Bartonella. The available sources are not consistent, and Bartonella articles or chapters show no familiarity with Babesia.

Therefore, as a trend, I lean toward large dots with any clear and significant cytoplasm as being extracellular Babesia. And as a trend, small dots on the outside or inside or “top” of RBCs without cytoplasm are interpreted as Bartonella.

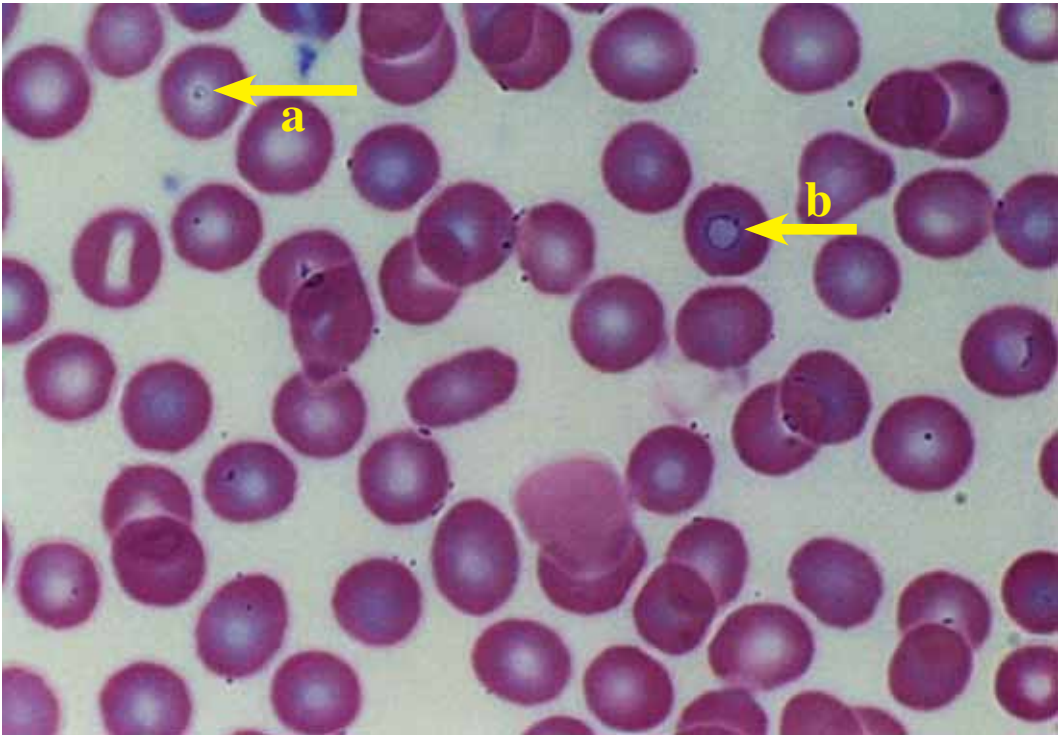
In contrast to routine pathology staff, I also have access to many other direct and indirect labs, and special physical exam findings to help confirm my diagnosis of vague dots.



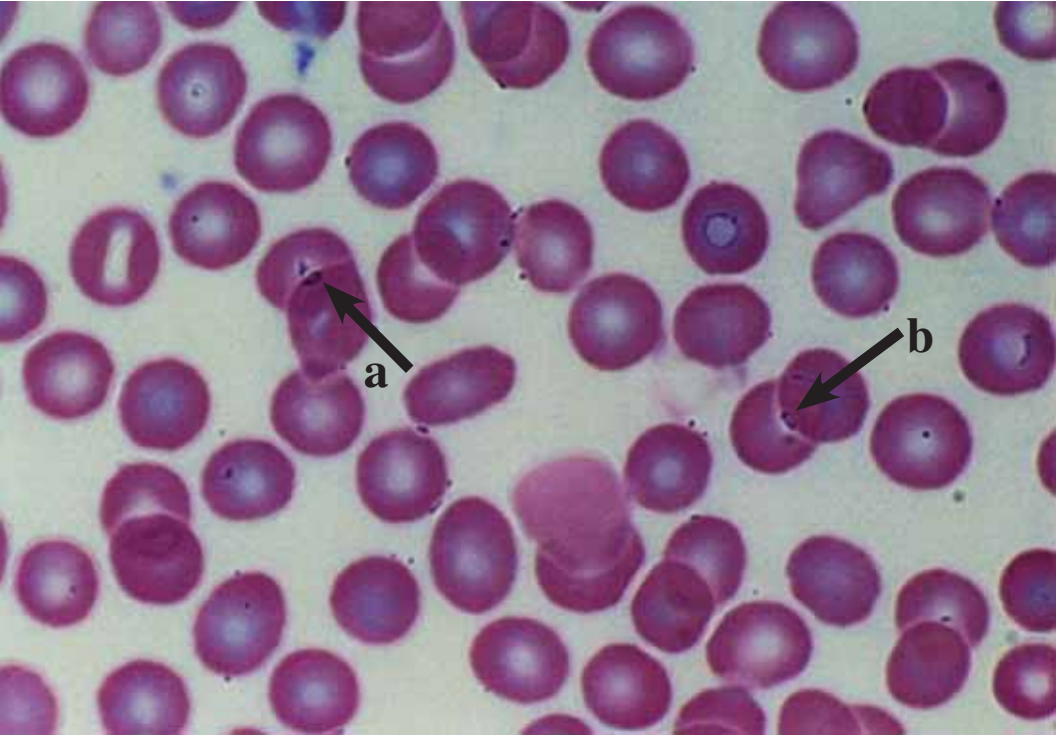
Both 3 and 4 are likely Bartonella bacteria because one does not see fully clear Babesia forms in the slide.



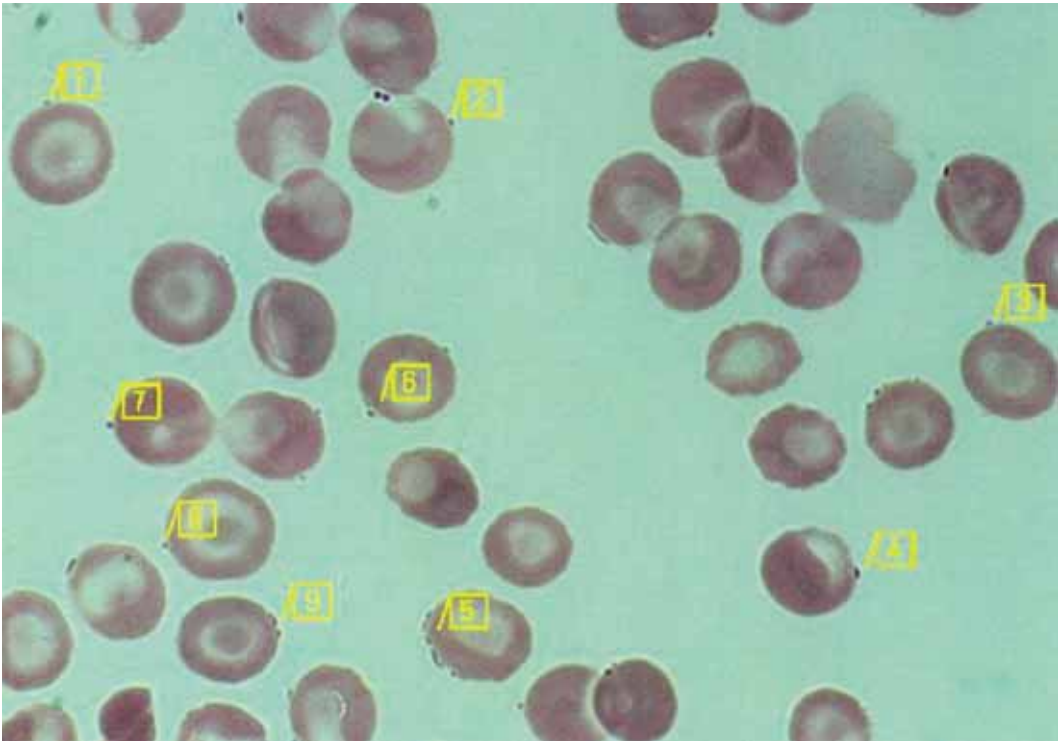
The use of computer aided enlargement has made identification of Babesia much easier. But this is what is commonly seen in an unmodified microscope smear. While you can see many types of ring forms, it would be virtually impossible to see Bartonella bacteria.



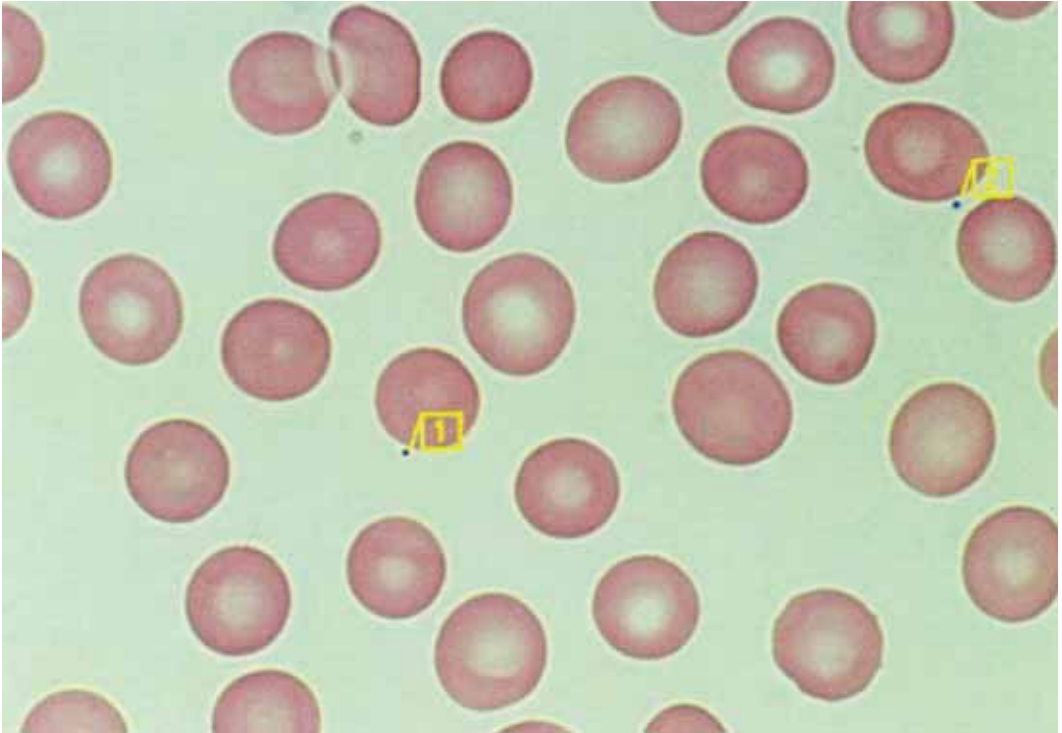
- a. A traditional small Babesia trophozoite or ring pattern.
- b. A traditional large ring pattern.



- a. Possible flat Babesia ring.
- b. Possible markedly flat Babesia ring or gametocyte.

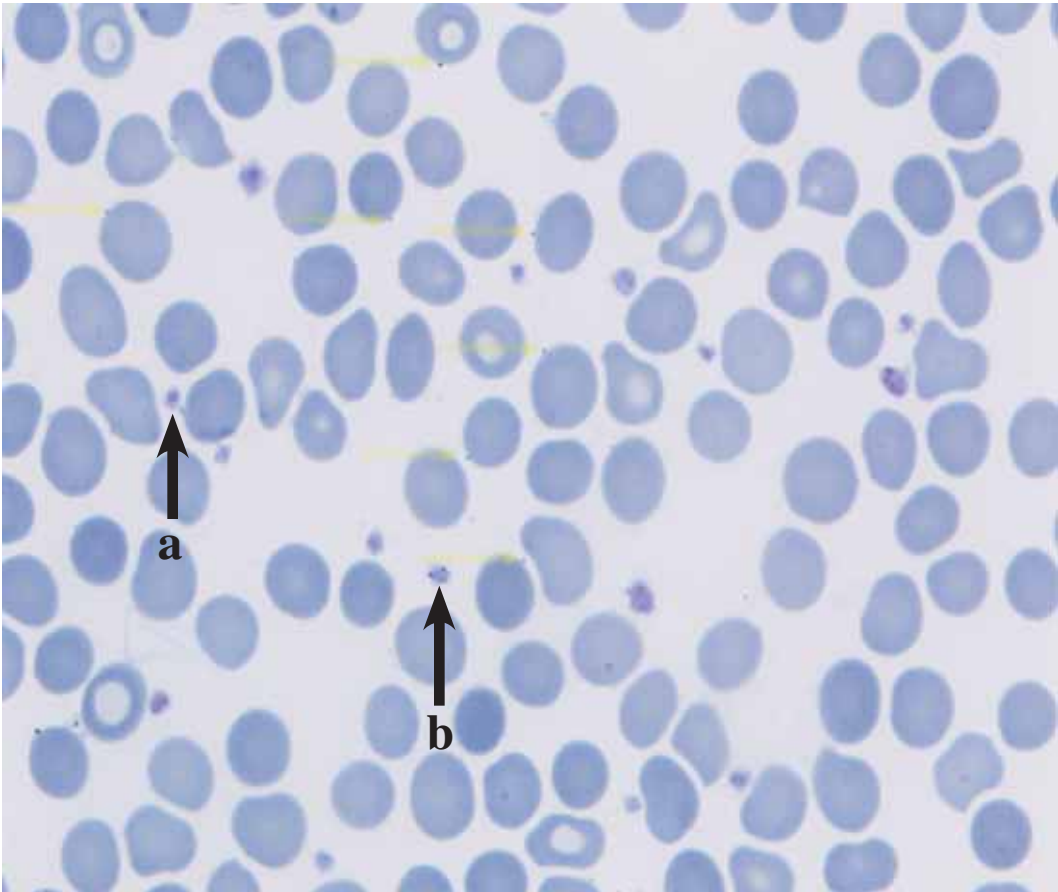


This lab suggests that numbers 1-9 are all Bartonella. I agree because we see so little Babesia activity.

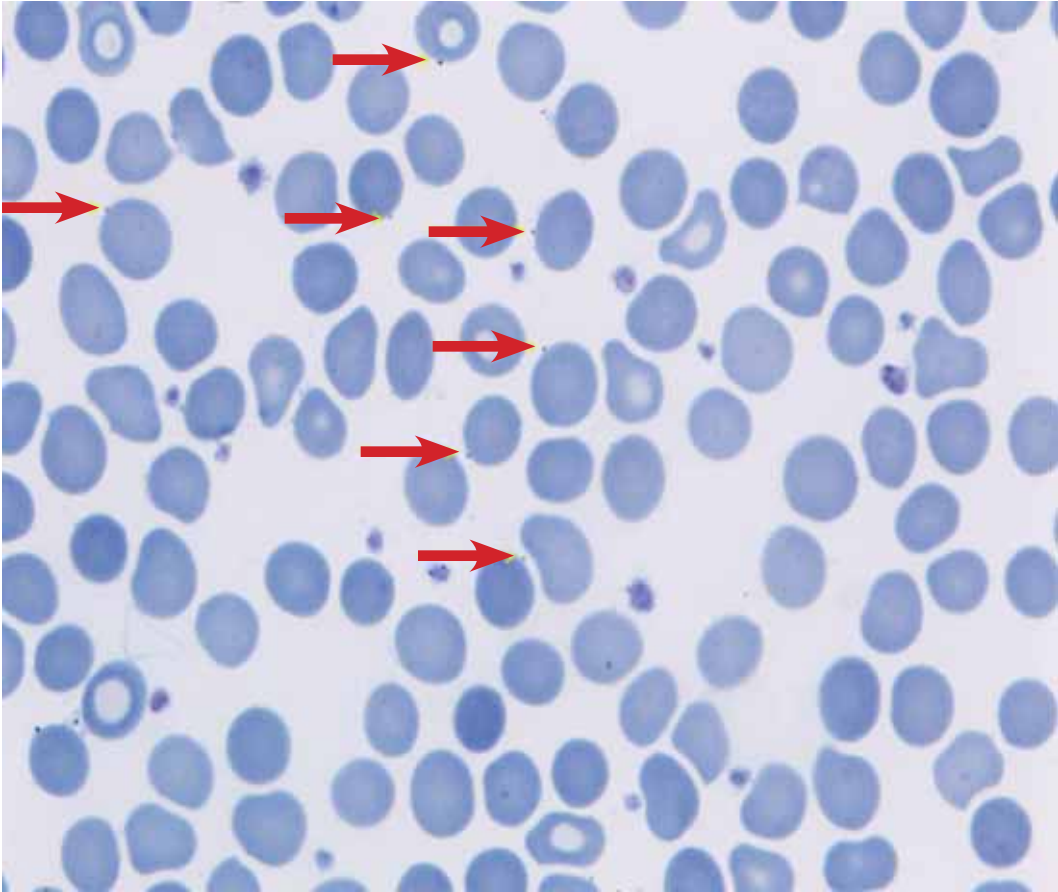


It is proposed that these are Bartonella bacteria. Since nothing else in this field remotely looks like Babesia, I think this is a reasonable working diagnosis. However, one problem I have seen with some labs is that their microscopy tech is not familiar with all the ways Babesia presents and therefore does not show that field.

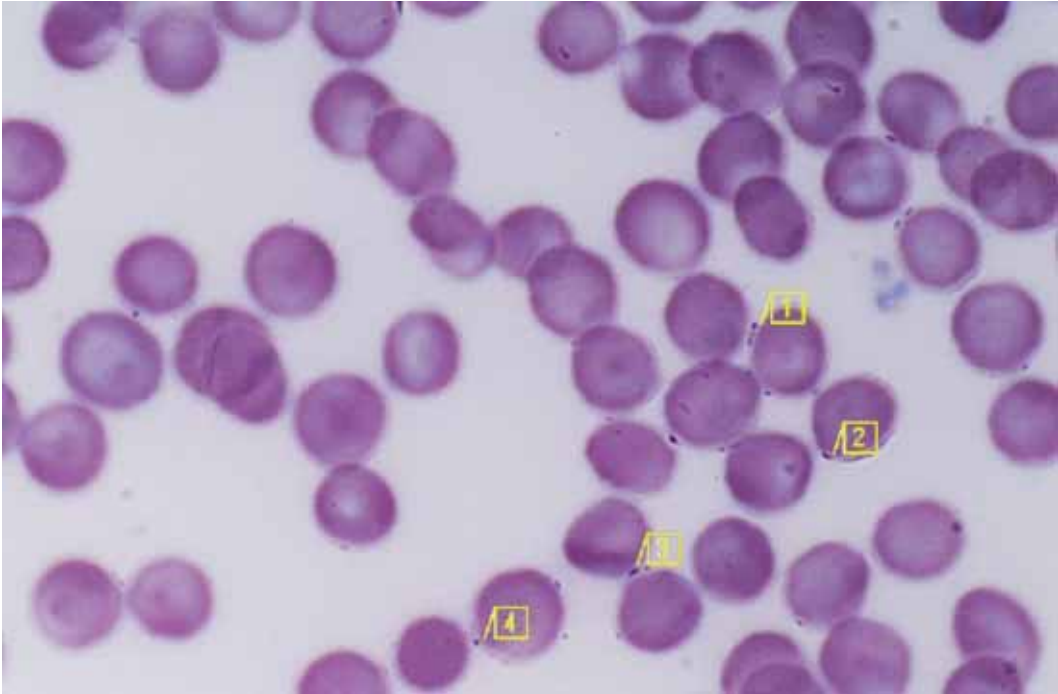
In other words, if the slide is moved 500 cells to the right, a microscopy tech or pathologist might see a Babesia form. But only if they are familiar with at least twenty forms and not merely four forms.



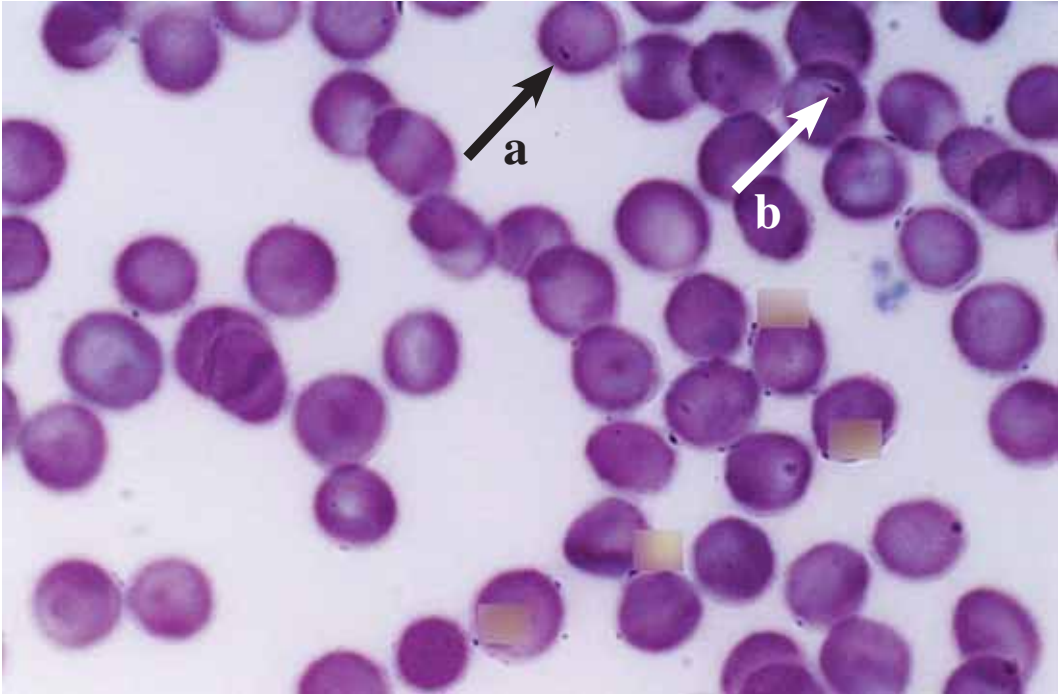
- a. It is likely this irregularly shaped object is a platelet
- b. Since this slide seems flooded with platelets approximately the same size as this object, I believe despite its two eye-like dots, that it is probably a platelet.



I believe that all these arrows are likely to be pointing to Bartonella on the outside edge of the RBCs. No clear Babesia forms are present in this slide.

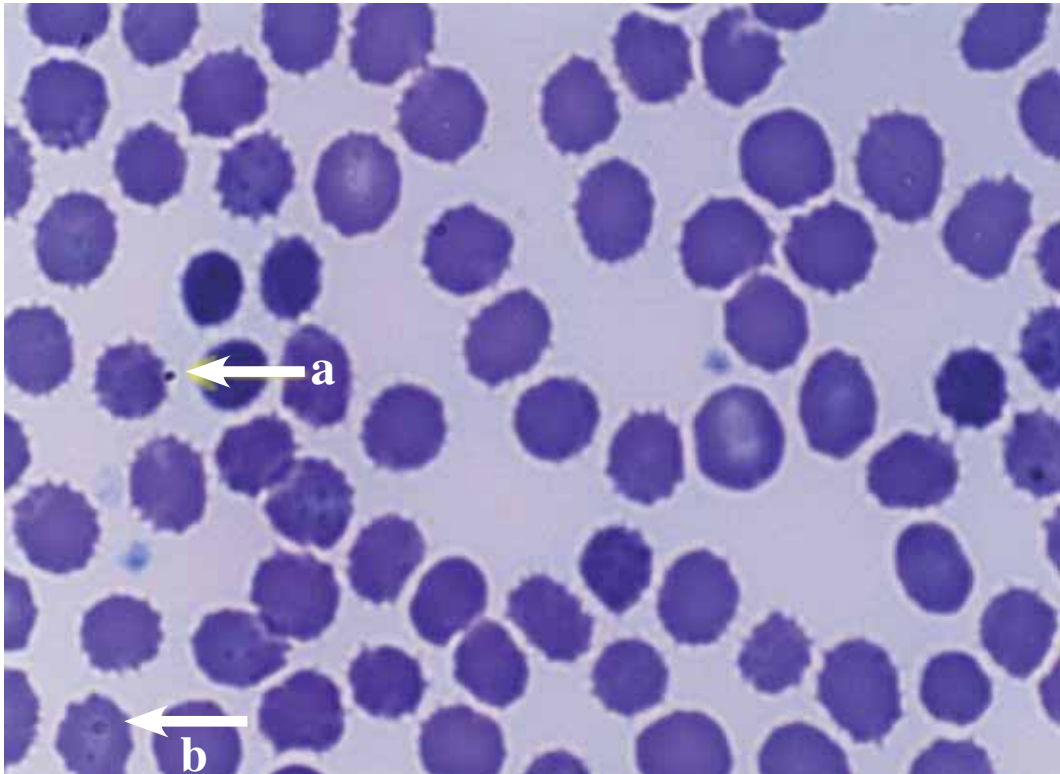


I believe that possibly all the forms sticking to these RBCs are Bartonella forms. Why? Because no clear Babesia shapes are present.

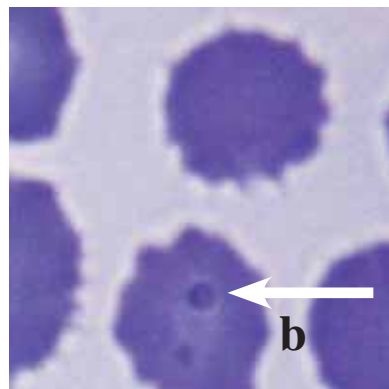
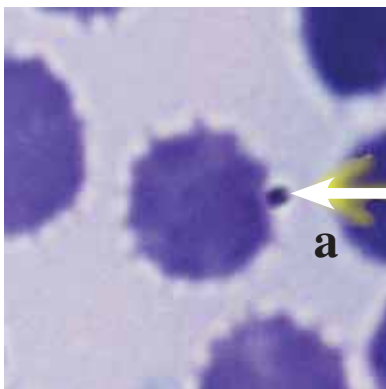


- a. This is either one infectious particle or two dots combined. It is not fully clear what infectious agent we are viewing.
- b. This infectious particle is shaped like a tadpole on which one end appears fairly large before trailing away, ending in a thin string. Is this Babesia with a long gamete tail? Is it a couple Bartonella in which one is pulled? Is it residue in a reticulocyte of an iron thread-like particle?

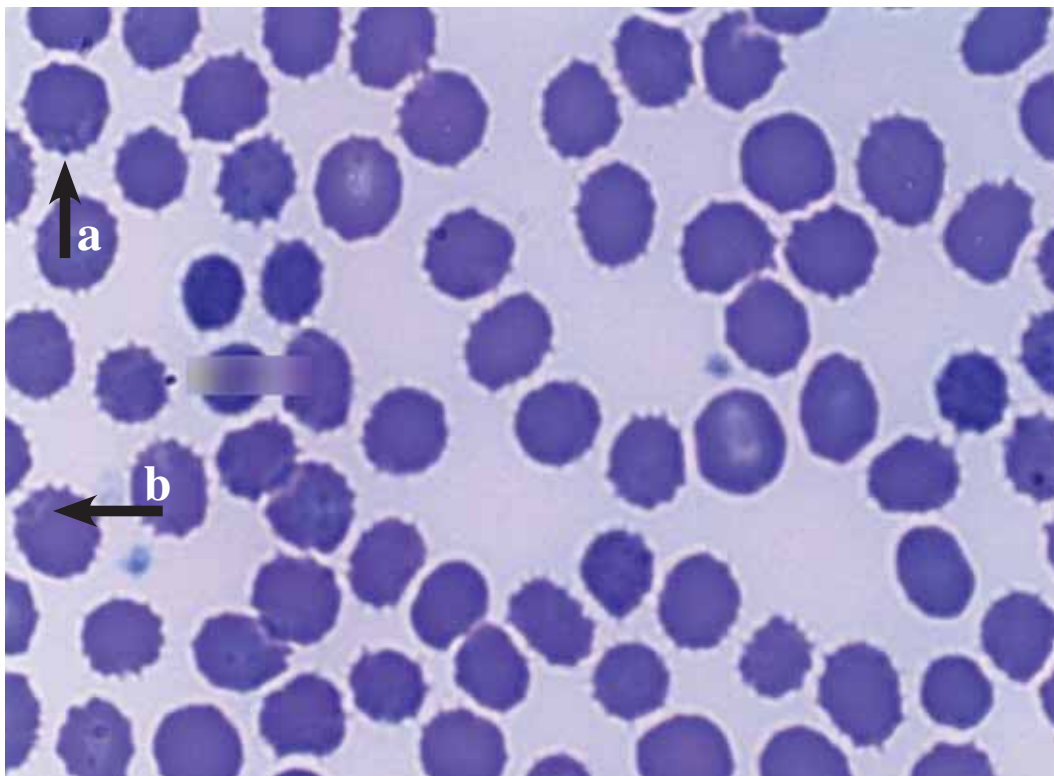
Since the answer is unclear, no comment can be made at this time.



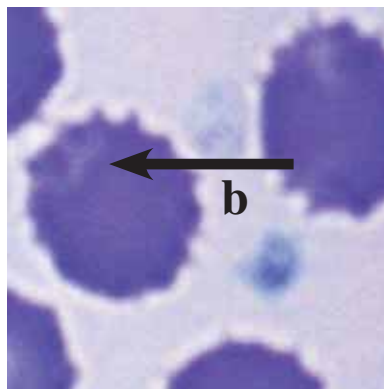
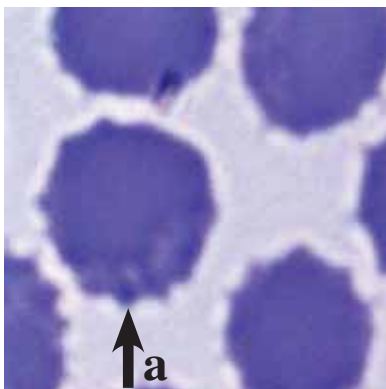
Some of the views on this slide call into question the quality of its preparation.



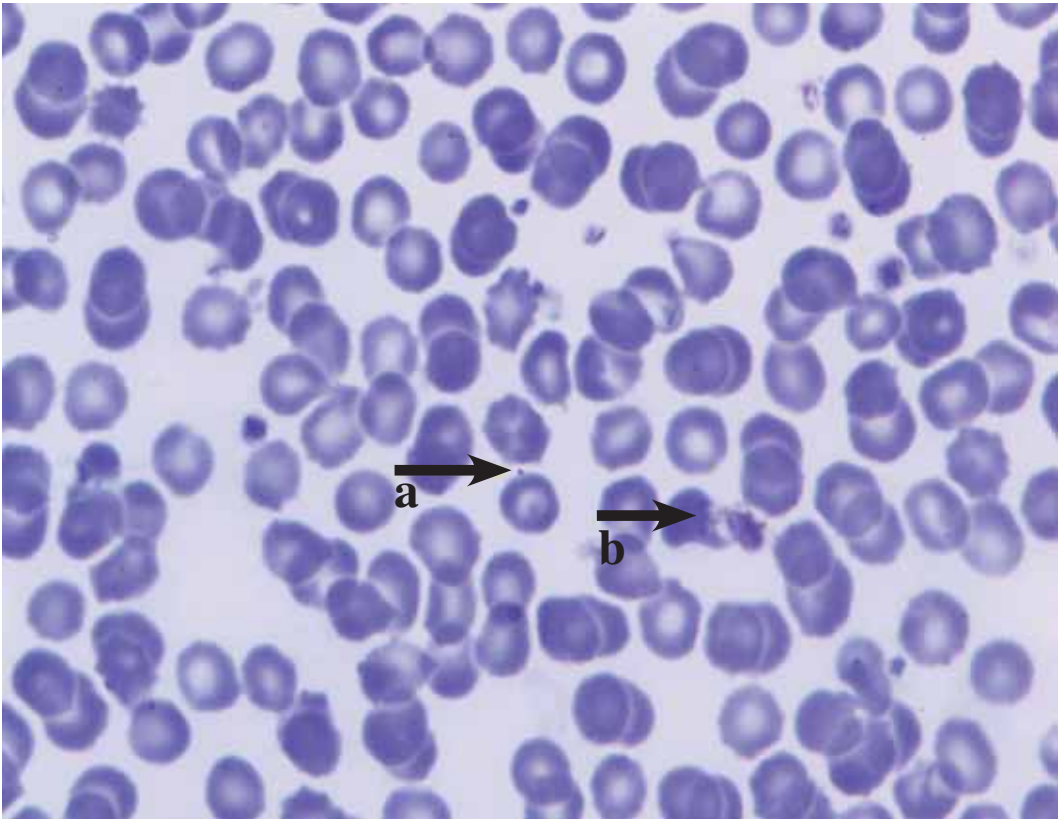
- a. A large Bartonella bacteria or a Babesia particle without cytoplasm.
- b. An artifact from the type of preparation used, or a possible ring form



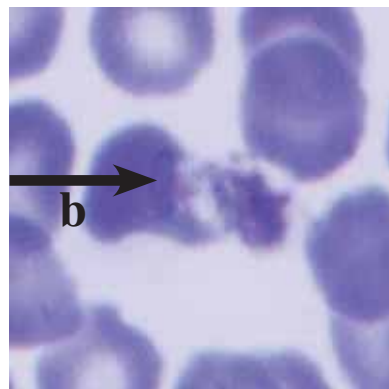
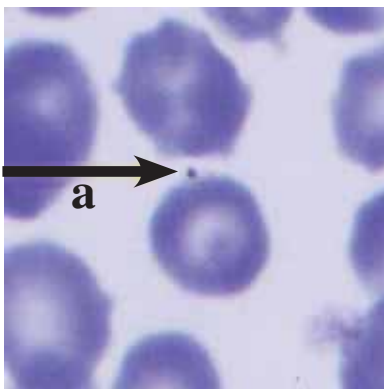
Findings are difficult in this challenging slide.



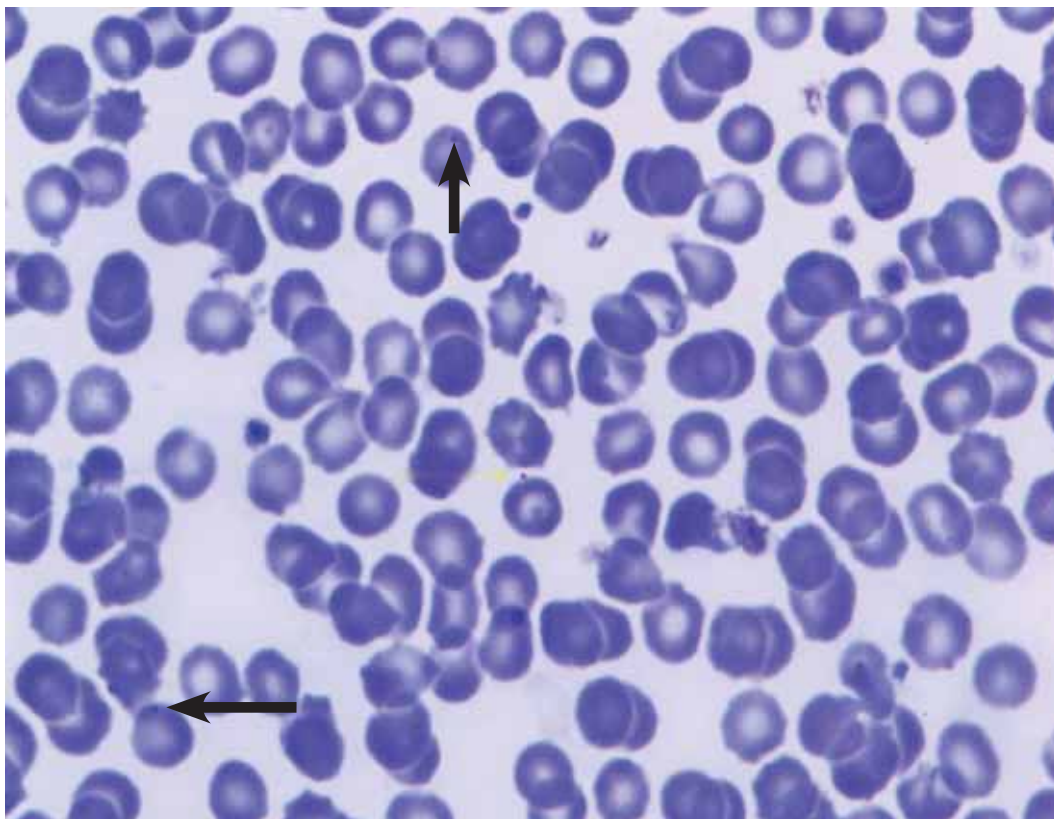- a. This appears to be a cluster of Babesia parasitic forms possibly getting ready to leave and infect other cells. It could also be an artifact.
- b. Due to the resolution, this suspicious area cannot be interpreted.



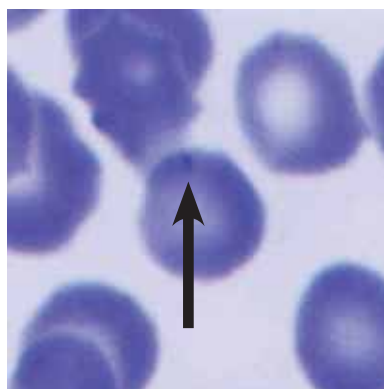
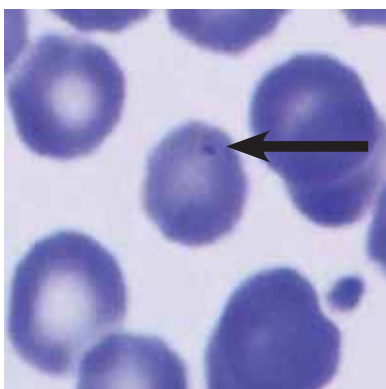
What do you see in this slide?



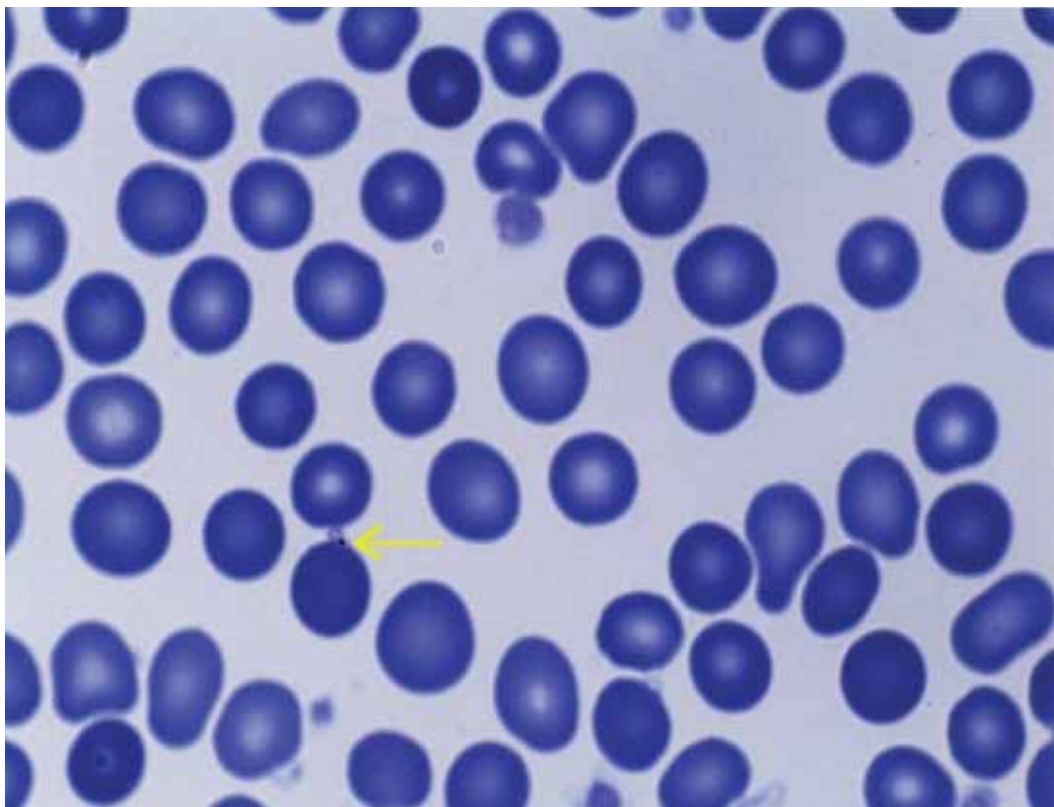
- a. I would suggest that this round bacteria is *Bartonella*, which can adhere to RBCs or enter them.
- b. This looks like a twirl of platelets next to a RBC and then covering the edge on an RBC.



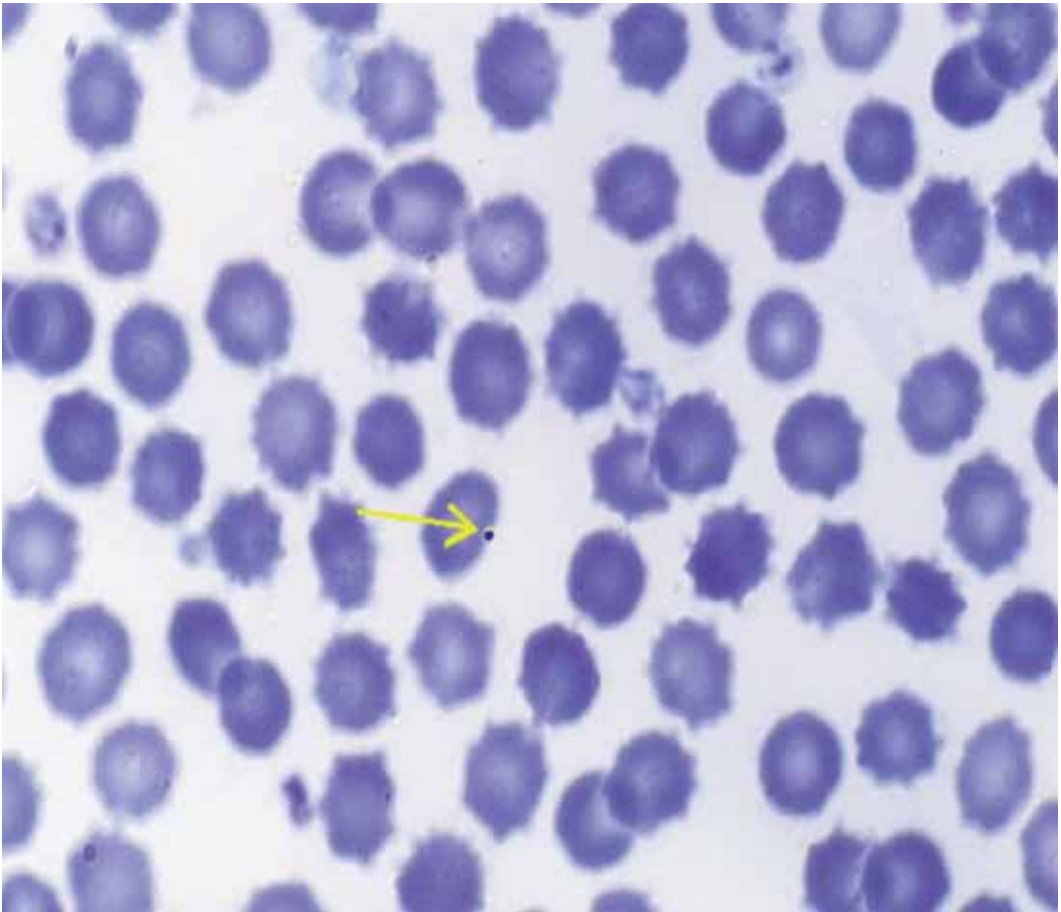
Do you see any certain Babesia?



Note that both arrows are pointing to dark short rod-shaped areas. It is not particularly obvious what is around these areas of darkening. Therefore, based on material already mentioned in this book, I would suggest refraining from a diagnosis.

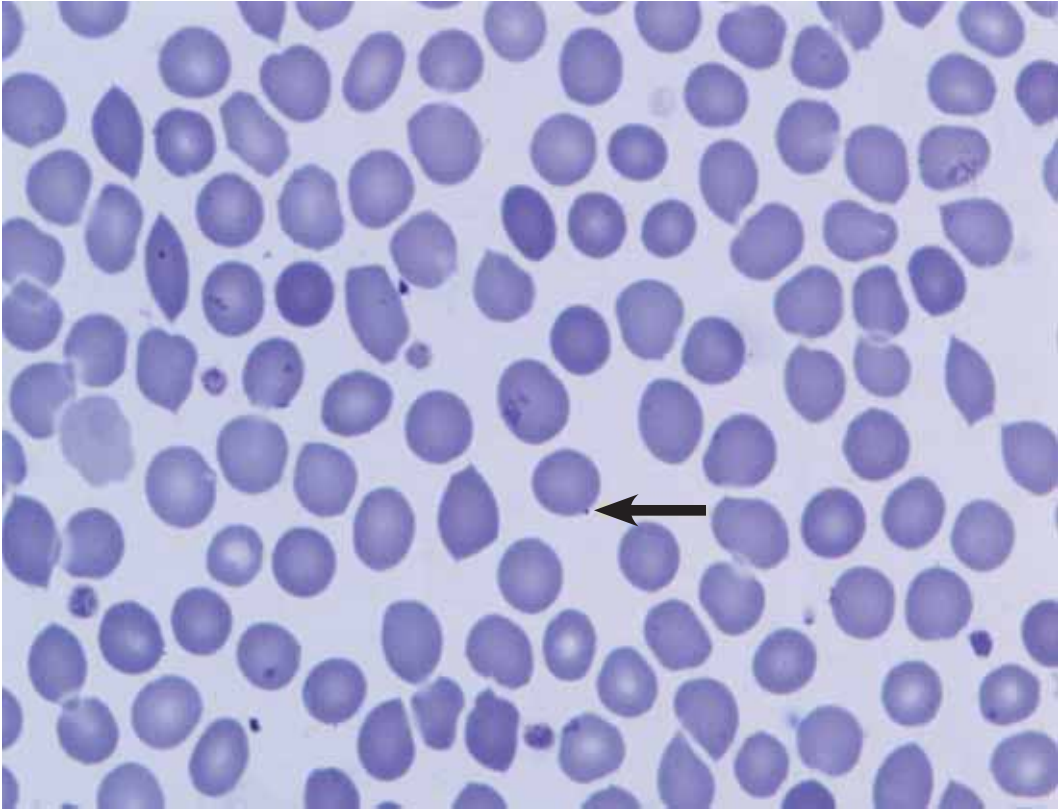


This is a Babesia form that few seem to realize exists. Since this patient had antibodies against two forms of Babesia, and there don't appear to be many small platelet particles, I am going with a 90/10 Babesia probability. Further, it is a perfectly formed version of extracellular form of Babesia.

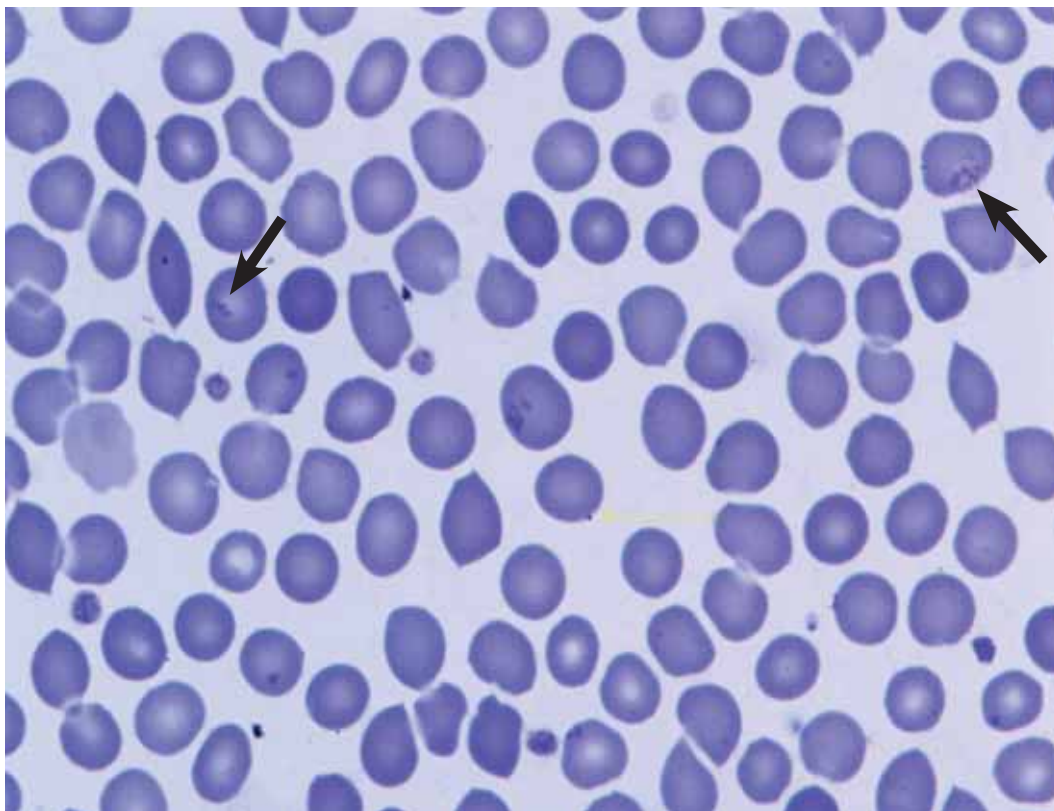


A probable *Bartonella* bacteria in which no cytoplasm is seen. Since the RBCs are enlarged, bacteria will also look larger. In the work of Greub and Raoult, we see some *Bartonella* that are fairly large ovals filling up large parts of RBCs as they multiply. And in the same article, noted below, they show a single *Bartonella* which appears very large.

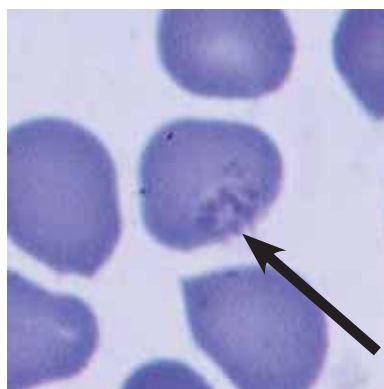
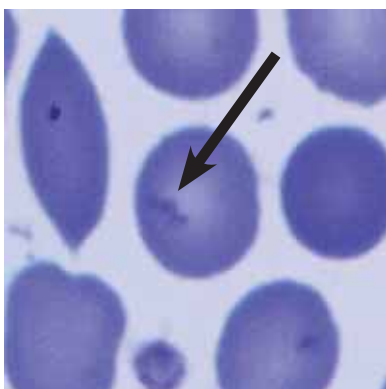
While these RBCs have a wide range of complex shapes, no clear *Babesia* forms are seen.



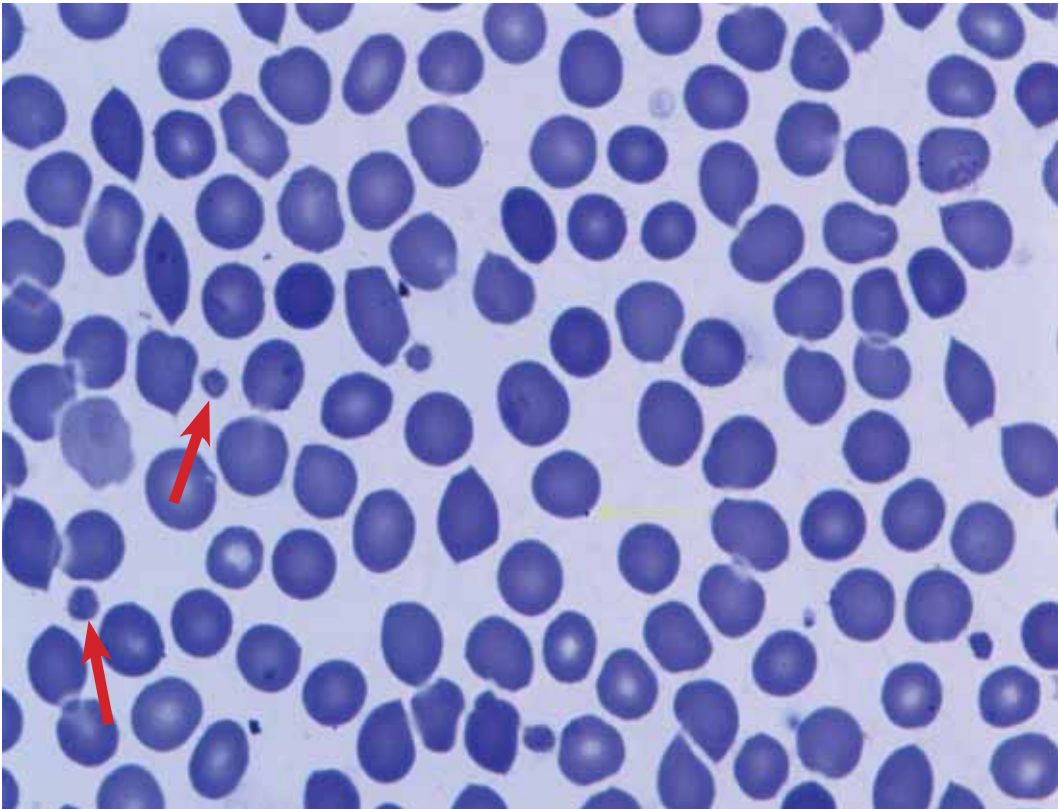
Since the RBCs are just slightly enlarged, this Bartonella bacteria looks like a mere dot.



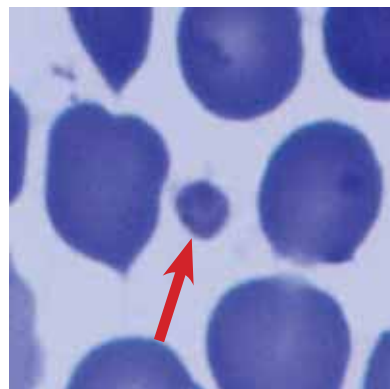
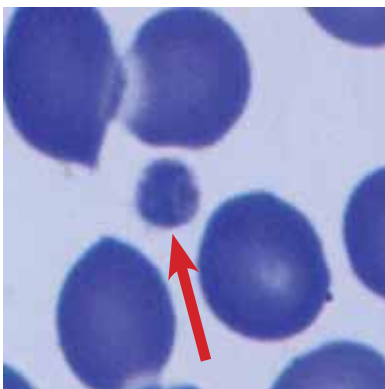
Do you see Babesia?



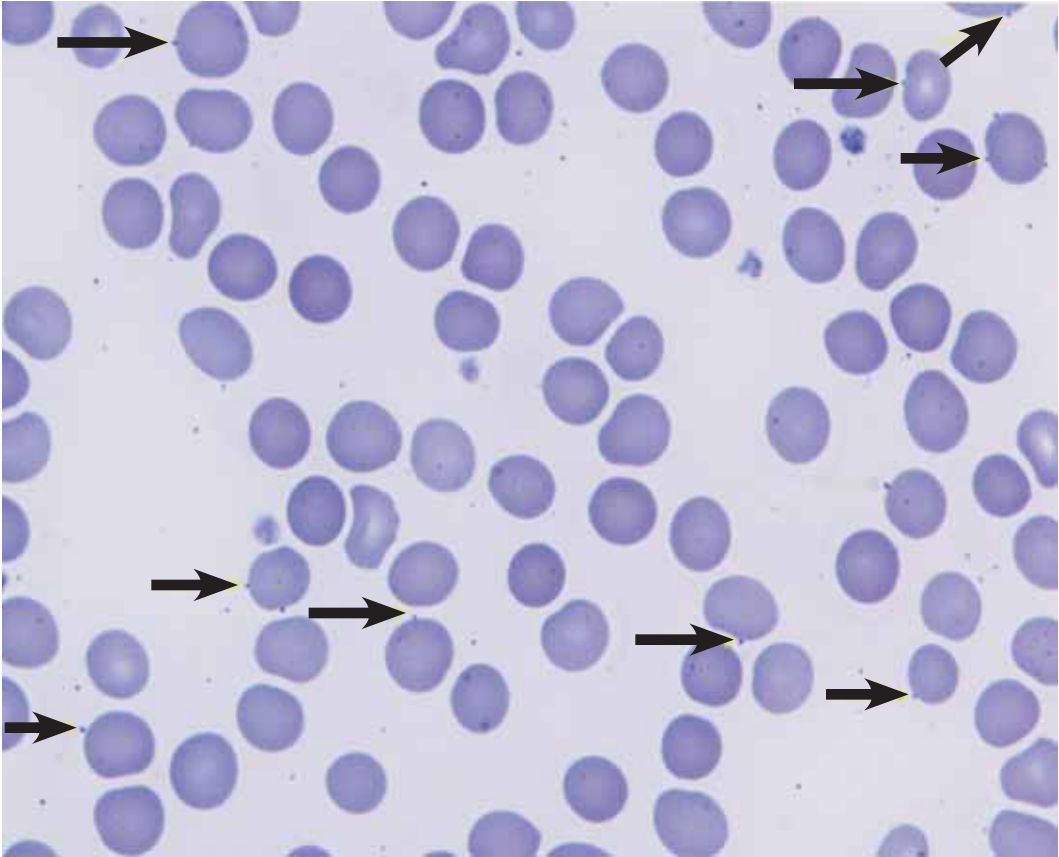
I do not feel that these cells show obvious iron pathology, nor do I see many reticulocytes. The image on the left has a thicker irregular band than I typically see in reticulocytes. It might be a Babesia form. I am unsure what the right image represents.



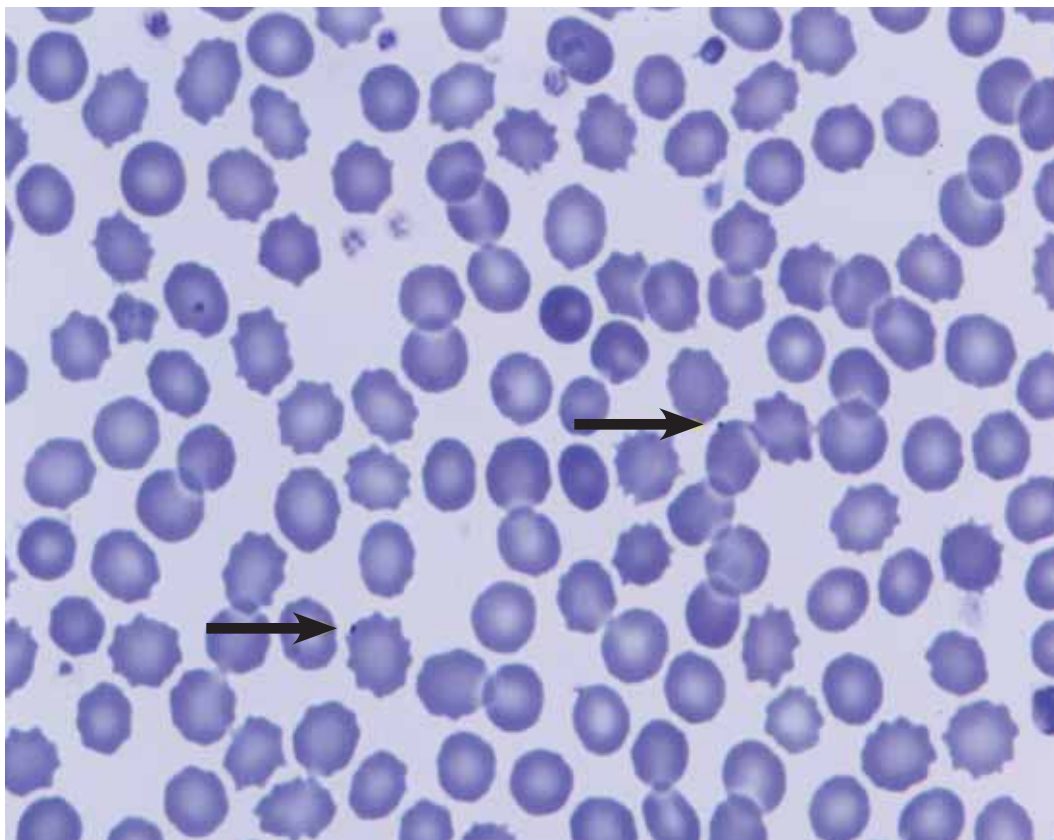
What are these dynamic round and box shapes?



While there appear to be possible swirls of color and round shapes in both, the markings are not pronounced. I feel that it is a staining variation and that these are probably large platelets.



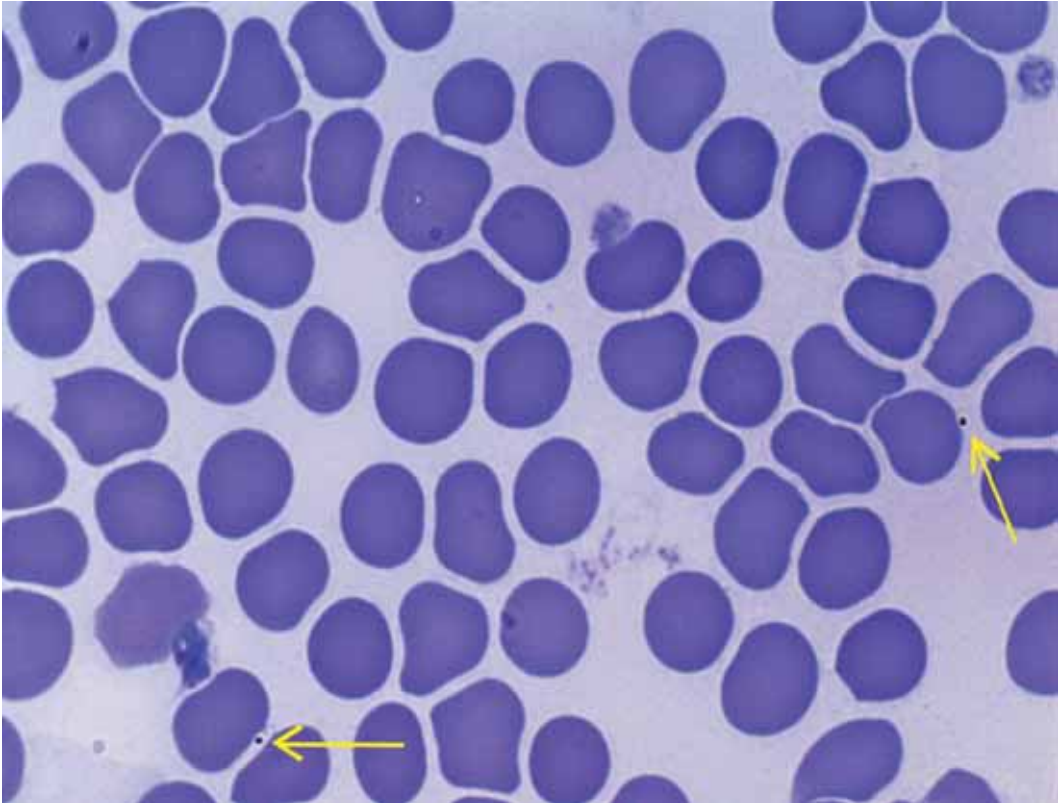
Many Bartonella direct and indirect lab tests confirmed these were Bartonella bacteria.



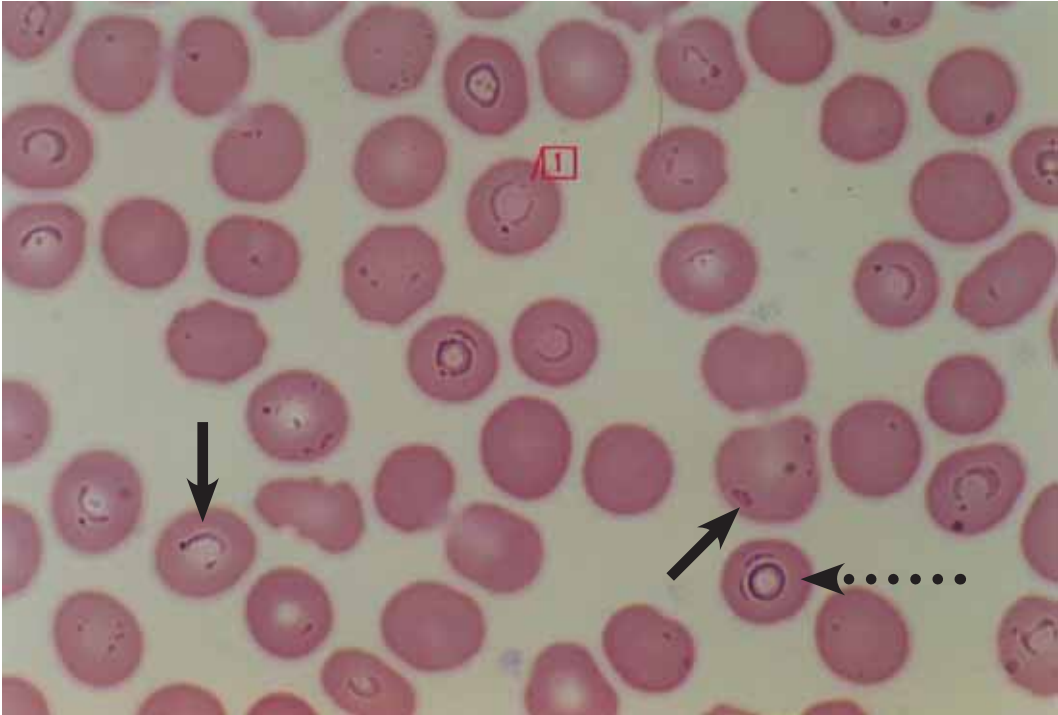
Black arrows pointing to probable Bartonella.

It is not yet fully appreciated that Bartonella is an explosively emerging infection all over the world. It infects humans in many ways. Therefore, it is not a surprise to me that many humans are positive for Bartonella.

In research planned to evaluate Bartonella induced impulsive violence we will have to get our Bartonella negative blood samples from the highest northern parts of Canada from individuals with no pet contact.



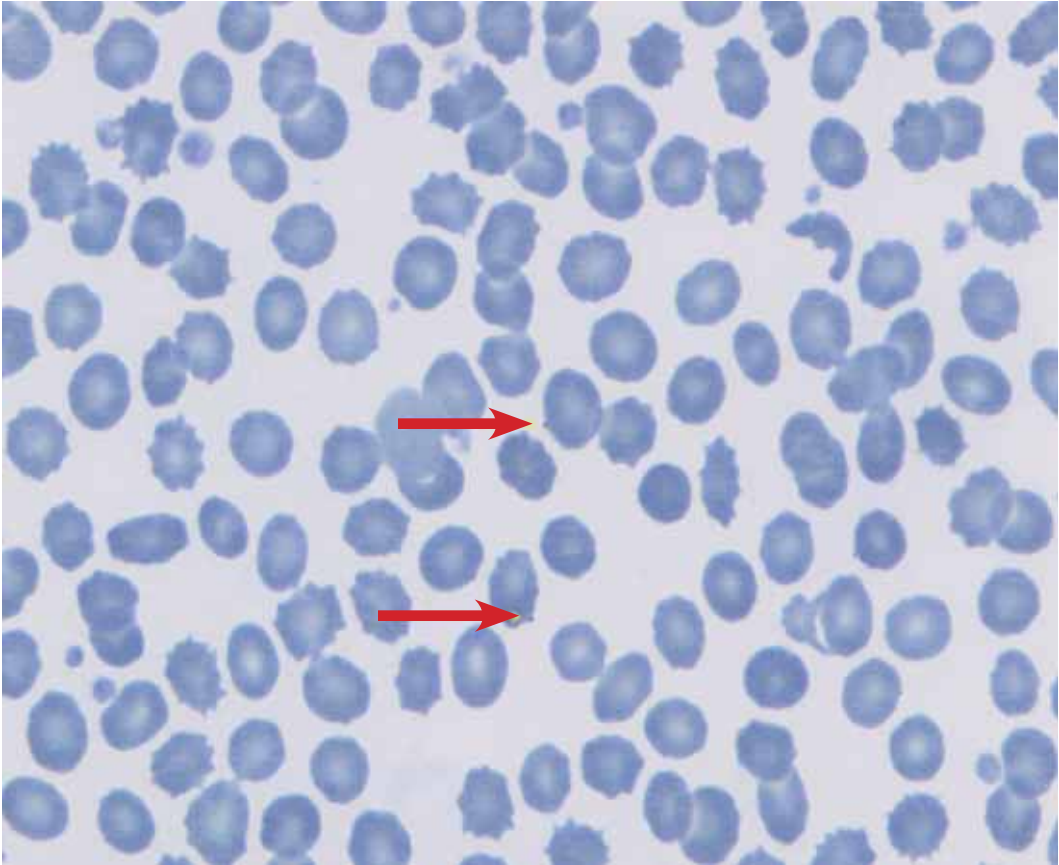
By now, you may be getting a proposed interpretation idea. Specifically, if I see dots around RBCs, and do not see any other Babesia presentation, I will tend to think it is Bartonella.



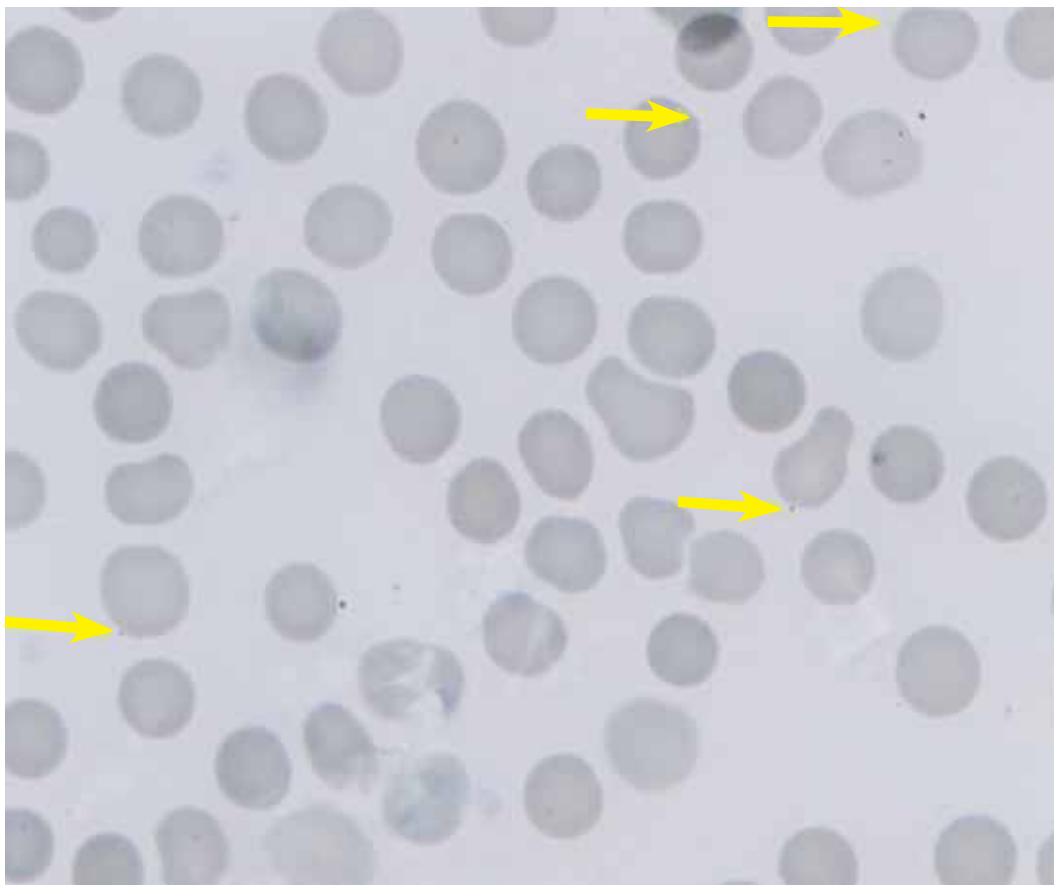
A very complex and dynamic slide requiring care. First, it is likely the red box number 1 in the middle of the slide is a Babesia ring.

It is also possible that some of the rings that form an irregular oval pattern are artifacts. (See the dotted arrow).

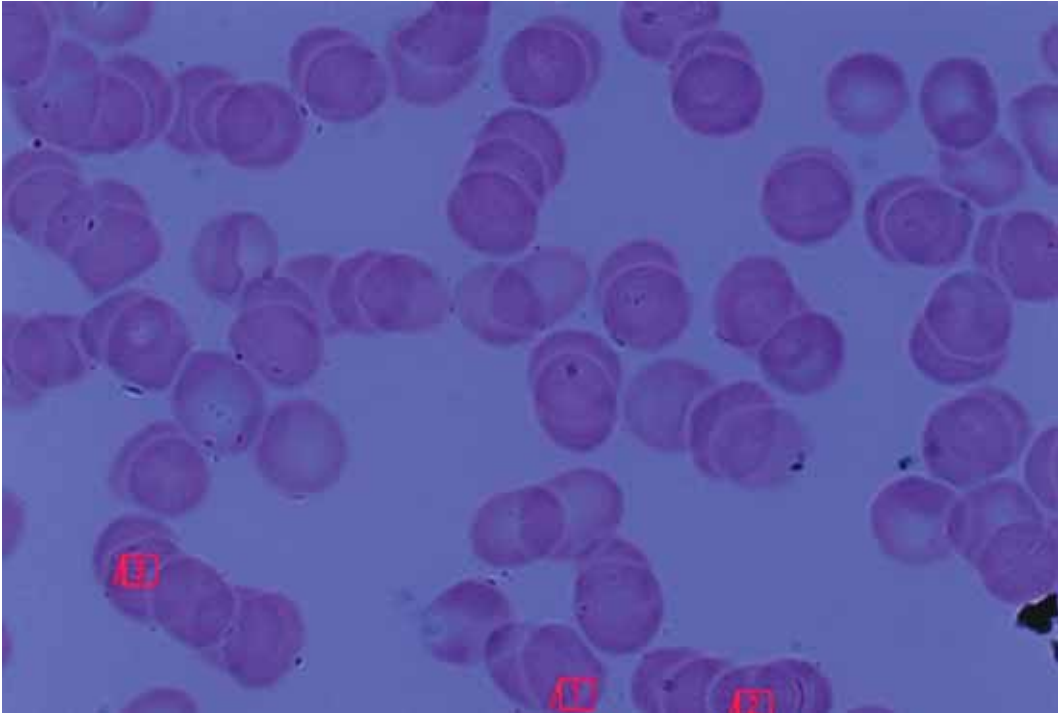
Other cells, which do appear to contain Babesia, are shown here (see solid arrows).



These cells are not very enlarged. The top dot appears to be Bartonella. The lower dot is a little more dynamic. It is not clear.



Small dots in enlarged cells tend to result in a Bartonella diagnosis. If you are starting to notice that many blood samples have Bartonella, you should be aware that, as of this writing, Bartonella has 32 species and 212 variants, and is one of the most common infections on the planet. Unfortunately it will be some time before these statistics are appreciated by the mainstream medical community as a whole. It is research from former human genome researchers working on Bartonella species.



Large round and solid oval dots in the presence of no obvious Babesia forms — Bartonella.

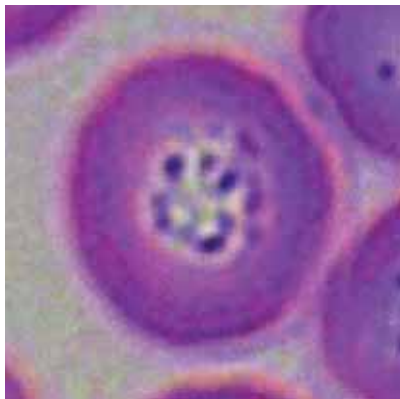
Enlarged Babesia Single Cells

**Presented to Enhance the Examiner's Ability
to See Many Forms of Babesia**

No patient in this collection had clear iron deficiency or excess blood iron, anemia, liver disease, malabsorption pathology or spleen morbidity.

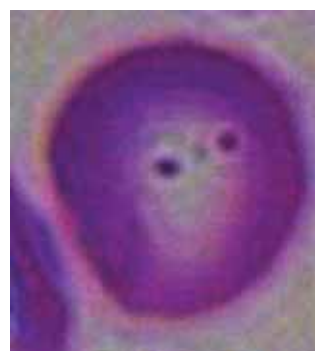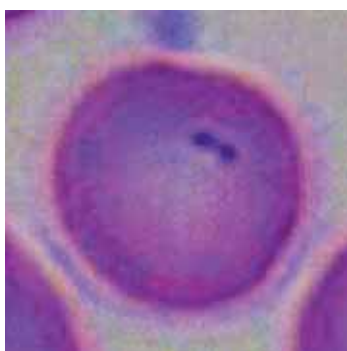
The following images were sent to me by Jeremy Brette, John Voss and Stephen Fry, M.S., M.D. at a great sacrifice. I enjoyed debating a wide range of interpretations with all of these fine men, and even if we have disagreed at times, it was always in the spirit of seeking the truth as honest scientists who share a passion to learn. This is a rare experience.

The style of staining shown here has varied over the years with various computer software modification programs and due to other possible factors such as humidity and season.



Babesia Cluster

If you look closely, you will see that the center of this RBC has at least four forms in close proximity.



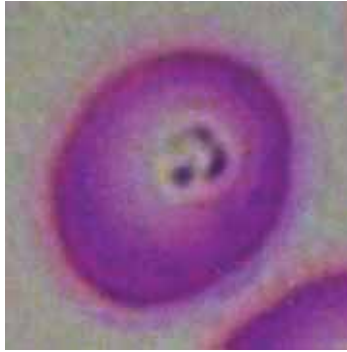Double Eye Pattern

The two samples on the left have no clear cytoplasm. The sample on the right has clear cytoplasm around the chromatin dots.

In one useful textbook, *Wintrobe's Atlas of Clinical Hematology*, a number of Pappenheimer bodies were presented with these shapes and other Babesia-like shapes **when stained for iron**. Of course virtually every slide in this book is from patients with approximately normal iron levels and who have no blood or bone marrow disease. No one had spleen disease.

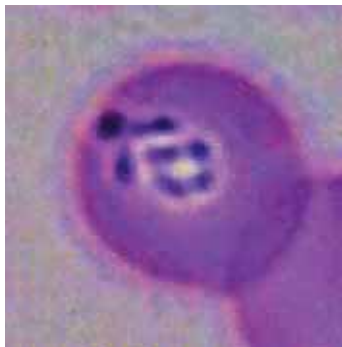
I wonder how many author's discussing Pappenheimer bodies in their books had any idea how common Babesia was in the USA blood supply? Their samples did not undergo rigorous Babesia testing.

I also wonder if both Babesia and Pappenheimer bodies have a similar presentation, in rare instances, or can be present in the same blood sample.

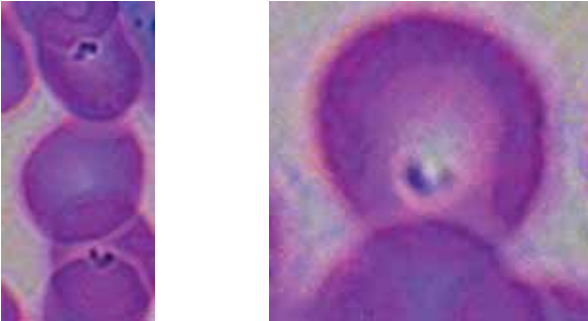


Classic Irregular Ring

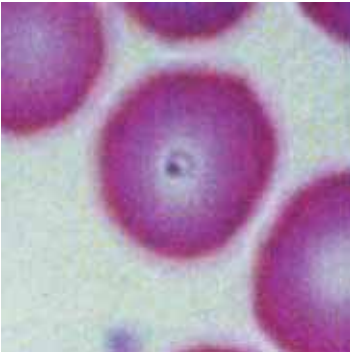
Most Babesia forms probably **do not** fit this obvious, simple form. And yet even this form is routinely and typically missed by small and large laboratories.



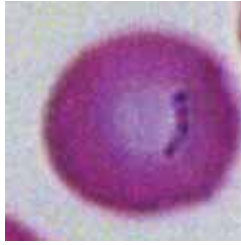Rectangle Form



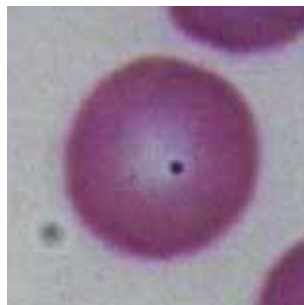
V-Form or Triangle Forms



Very Small Classic Ring Form



Worm or String of Pearls Pattern

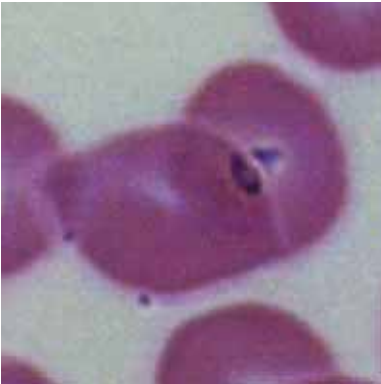

Eye Form

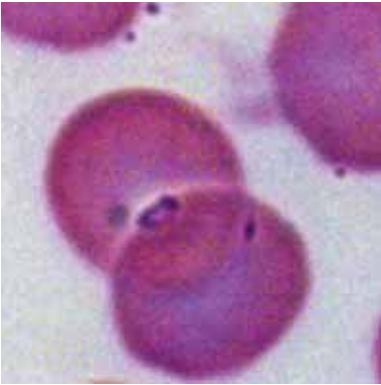
Black Chromatin or DNA dot in light colored cytoplasm. I hypothesize it is possibly a bit large for common, human Bartonella, and many Babesia forms were in nearby cells.

I do not believe this is a Howell-Jolly body because there is no anemia in this patient.

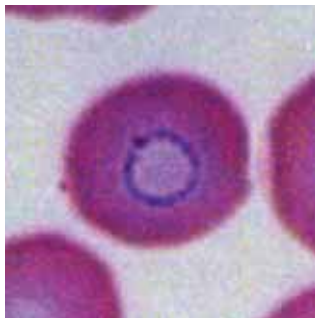
Oval Ring Form



This type of ring is on the outside edge of the RBC and is only half visible in this football shaped RBC.

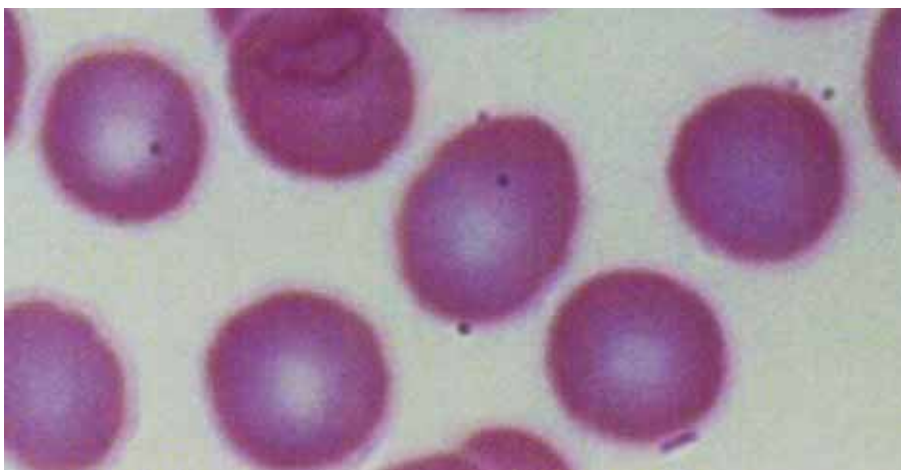


Another narrow oval ring at 11 o'clock on the lower RBC.



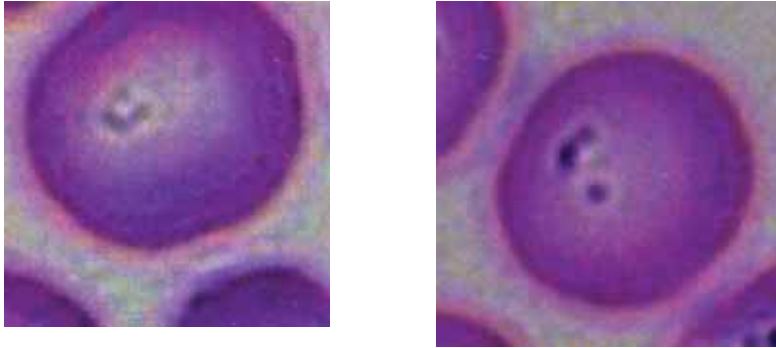
Very Large Ring Form

While the ring has a slight variation in color, it is a crisp ring and a clear chromatin dot.

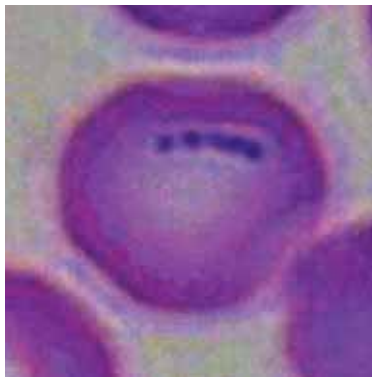


Bartonella or Babesia Forms?

Both organisms can be on the outside of RBCs. If one sees a number of organisms on the outside of the RBC, I would lean toward them being Bartonella bacteria. But ideally one really should have other evidence.

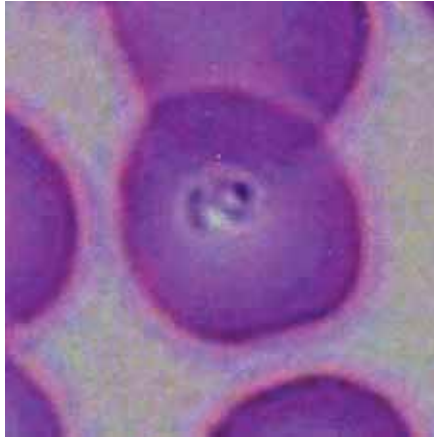


Triple Eye Form

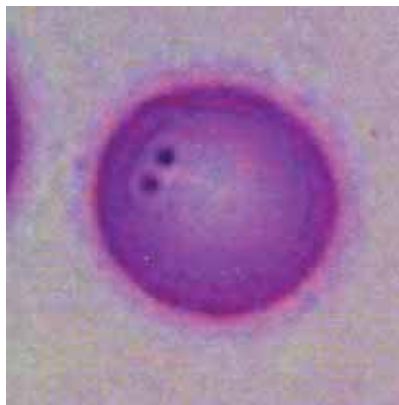

String of Pearls or Worm Pattern

Since this blood sample is clearly showing many forms of Babesia, I would suggest each dot here might be a Babesia chromatin or DNA cluster. Further, it does not seem that Bartonella inside RBCs become rings, crescents or long pearls.

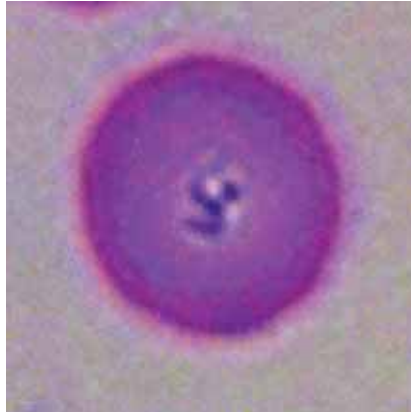

Ring Form with a Tail or a Hook

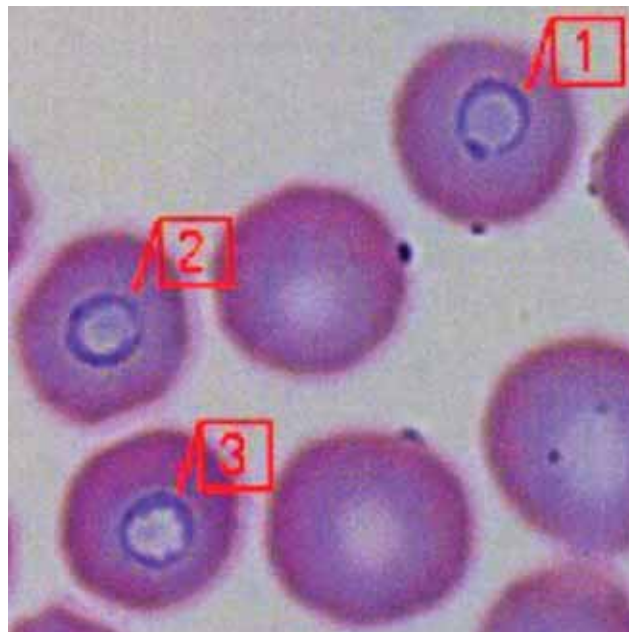


Double Eye Pattern

I do not believe this is a Holly-Jolly body because they are not typically seen in a pair, this patient has no iron pathology and other Babesia forms have parts like these large dots attached to them.

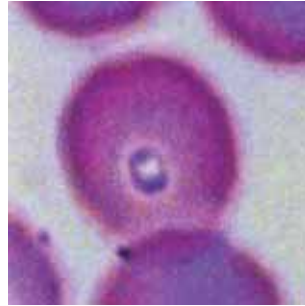
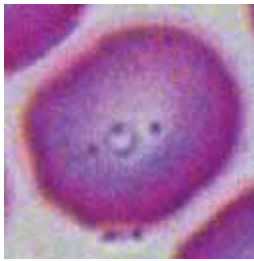

Y-Pattern or Triple Tail Pattern



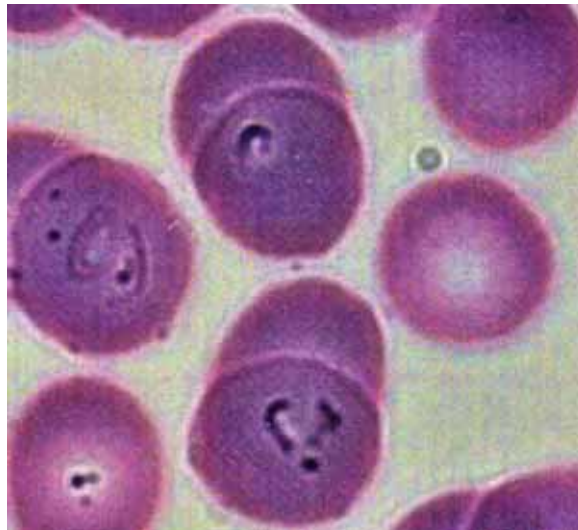
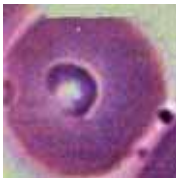Three Large Ring Forms

The top ring form is a classic Babesia form. It has a uniform ring with one clear dot. The other rings have thick rings and multiple dots which are found in Babesia infected RBCs.



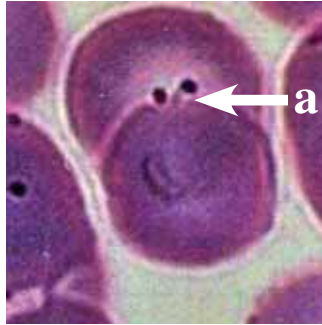
Micro Ring Forms

Most Babesia and malaria books report that Babesia rings have profound variation. Here are some that are very small, and depending on the stain, easy to miss.



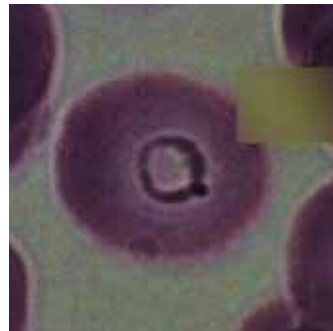
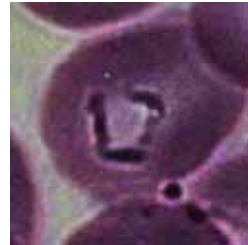
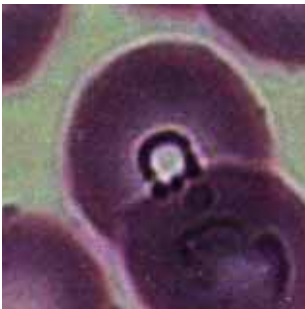
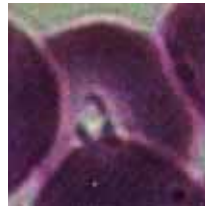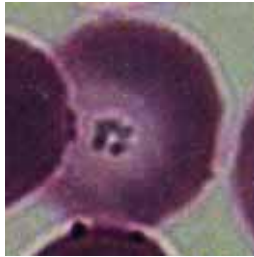
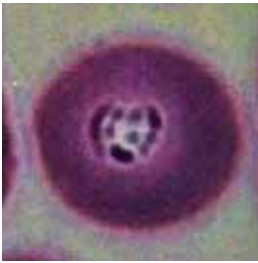Micro Crescents

Some crescents might be ring forms in which part of the ring is invisible to routine viewing.



Babesia Micro Ring with Babesia Dot?

The form in the right top of the RBC is clearly Babesia (a) with a trunk-like clear part emerging from the RBC. The dot next to it is likely Babesia since its dark top region is identical to the right Babesia. So here we see an example of Babesia, on the left top side, appearing as a mere dot.



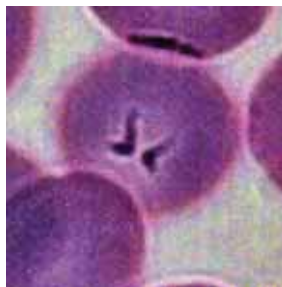Babesia "Rings" Are Highly Variable

These examples show the wide range of ring forms and sizes.



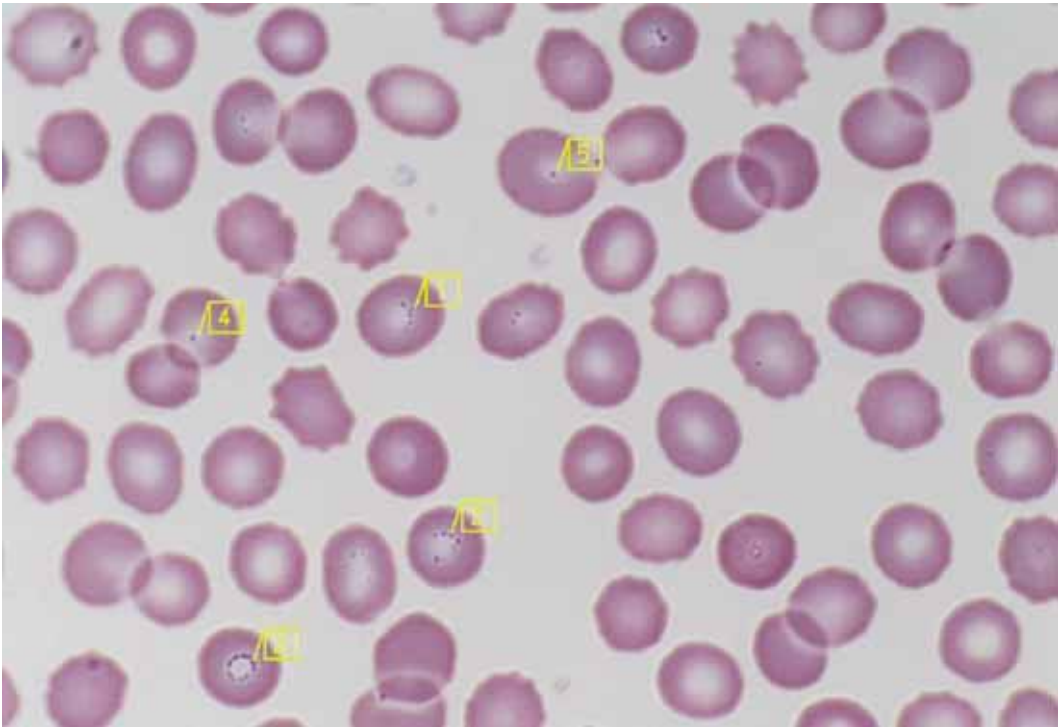
Rabbit Ear Pattern with “Drooping” Ear

One Babesia form looks like a rabbit ear and bends to the left. Another Babesia form is also drooping.



Triangle or V Forms

These Babesia forms are thick and have a sharp 90° bend. I do not believe these are Pappenheimer bodies because this patient had clear Babesia and no iron pathology.

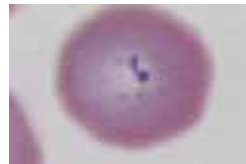

At lower magnification in the large slide above, one might incorrectly think this is two *Bartonella* bacteria in close proximity. However, with enlargement, it is certain there are at least six dots and that they are in an inner ring shape, and so are likely *Babesia*.

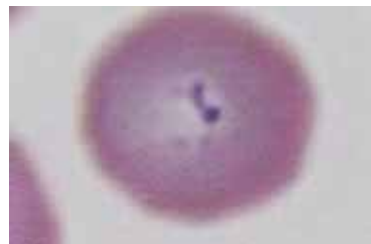
1x



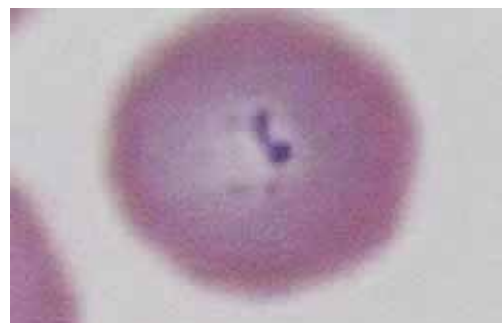
2x

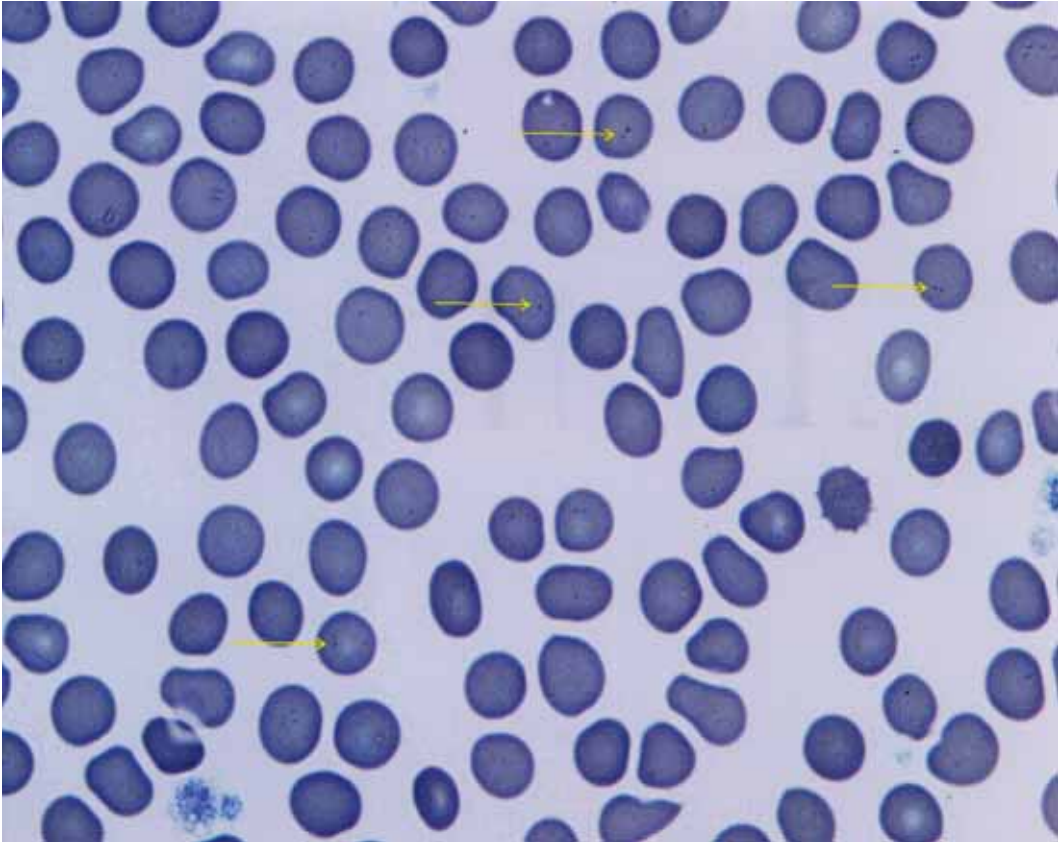


3x

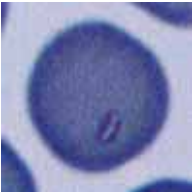


4x

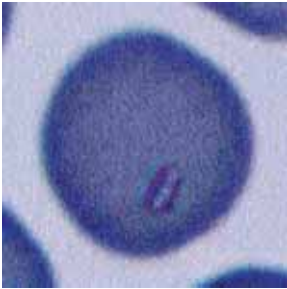




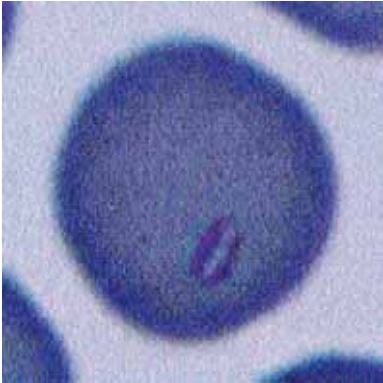
2x



3x



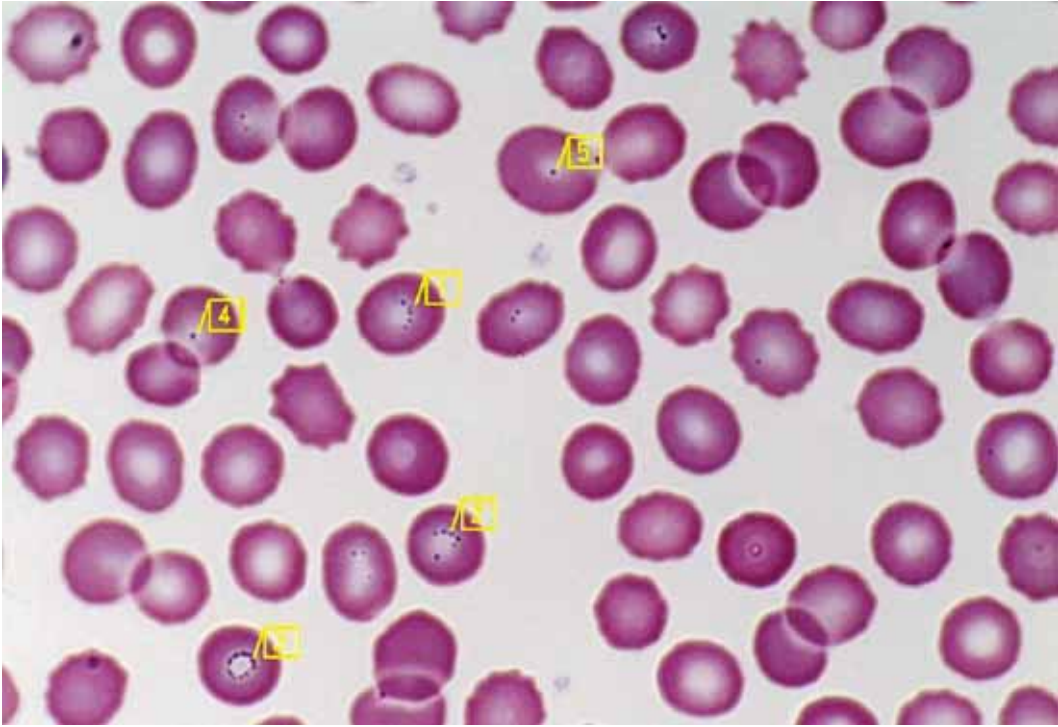
4x



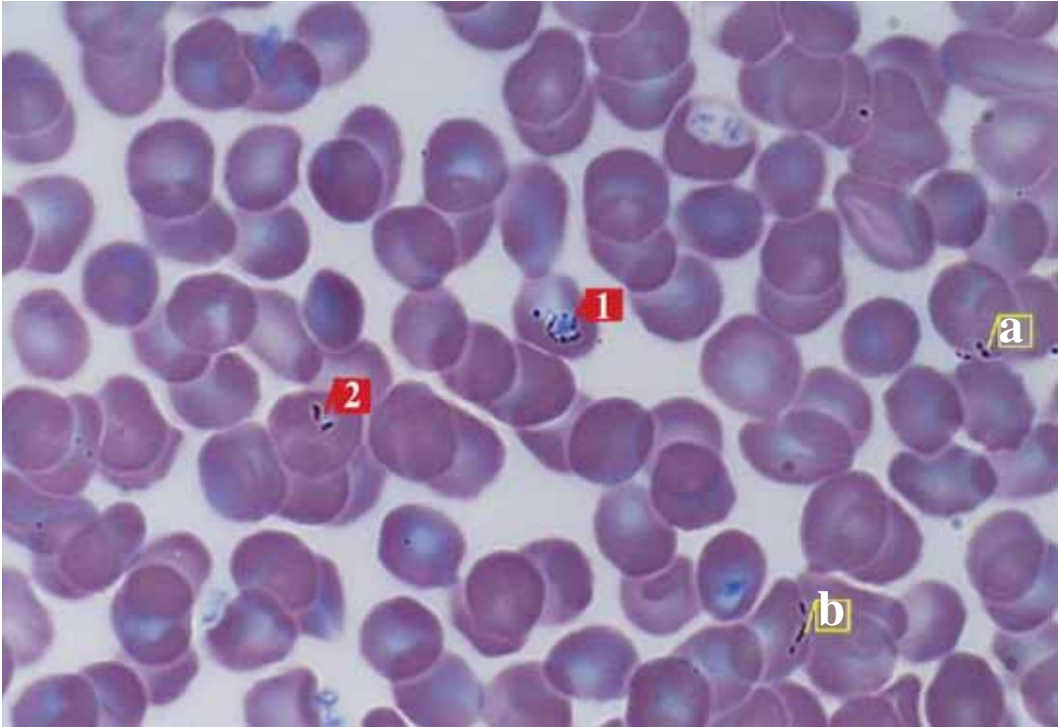
Some Bartonella forms look just like this hotdog pattern. And so can some Babesia forms.

Final Sample Forms

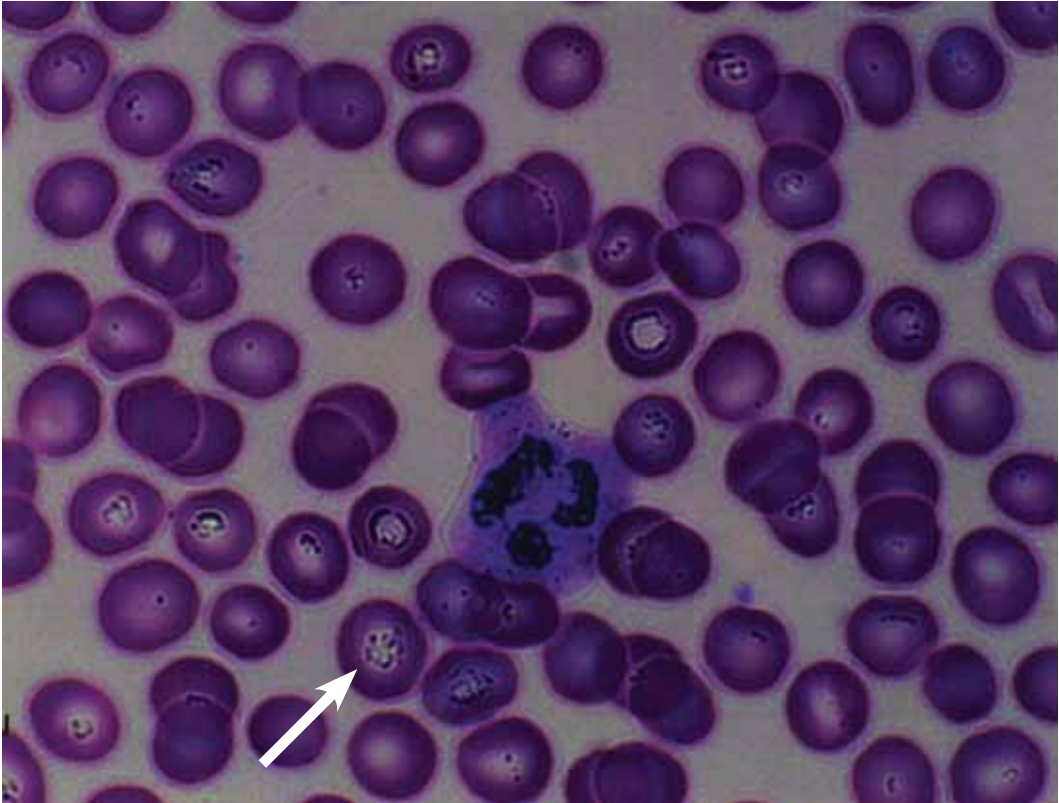
**Please try to look at the image and interpret what
you see before reading my proposed identification**



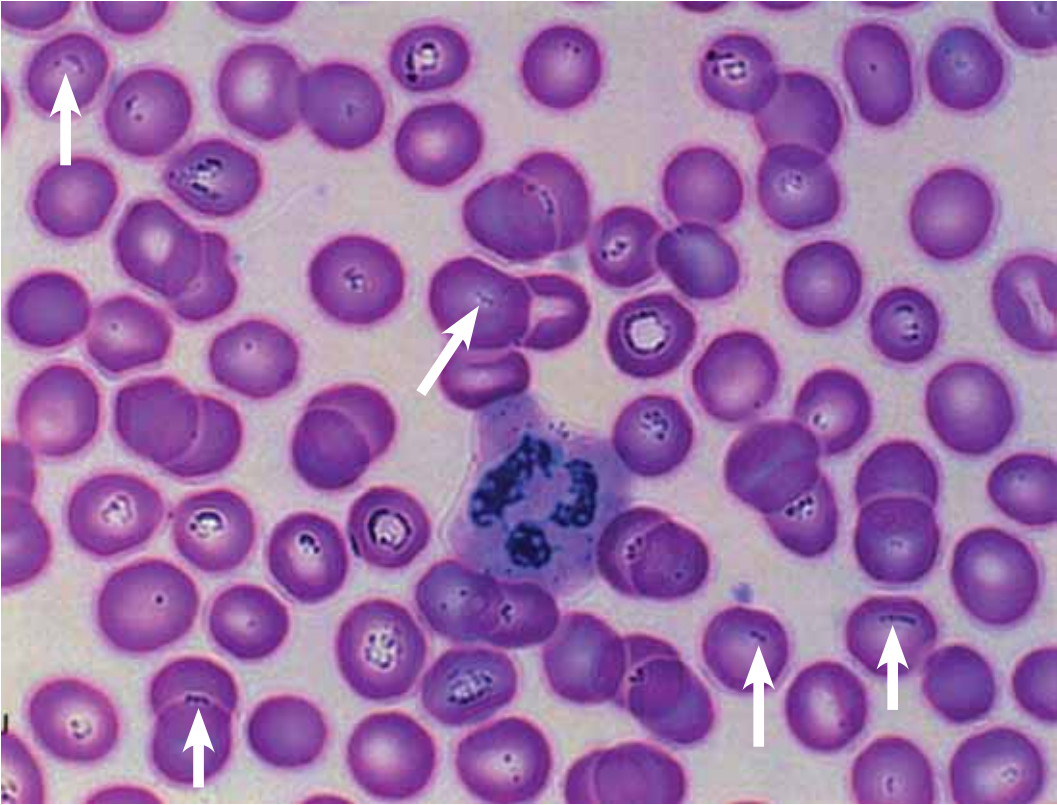
Because many of the numbered forms have dots which are part of clear ring forms, I would suggest perhaps all of these with markings are Babesia even though they are very small.



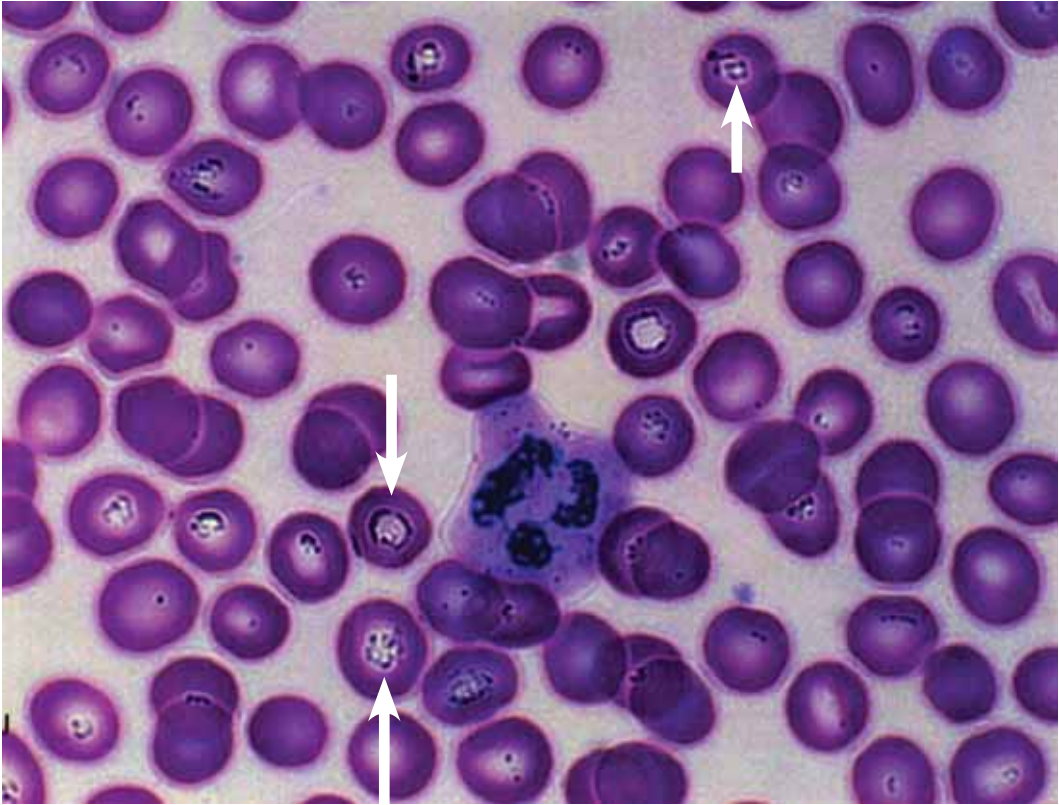
One microscopy expert feels that 1 and 2 show either a clear Babesia irregular ring or fat Babesia banana shapes, while a and b show possible thin linear or oval dots. I feel a and b could be either Bartonella oval or rod forms or immature Babesia forms or both. Some might consider b as representing the residues of a reticulocyte with classic dark thick lines.



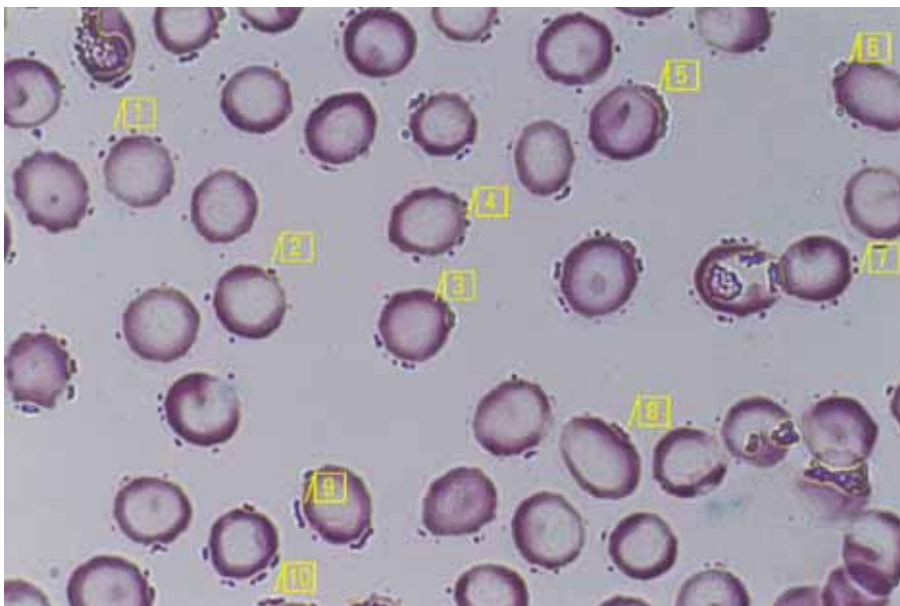
A cluster of Babesia forms which appear ready to burst out of the RBC allowing further infection of the human host. This slide shows about 15 Babesia patterns.



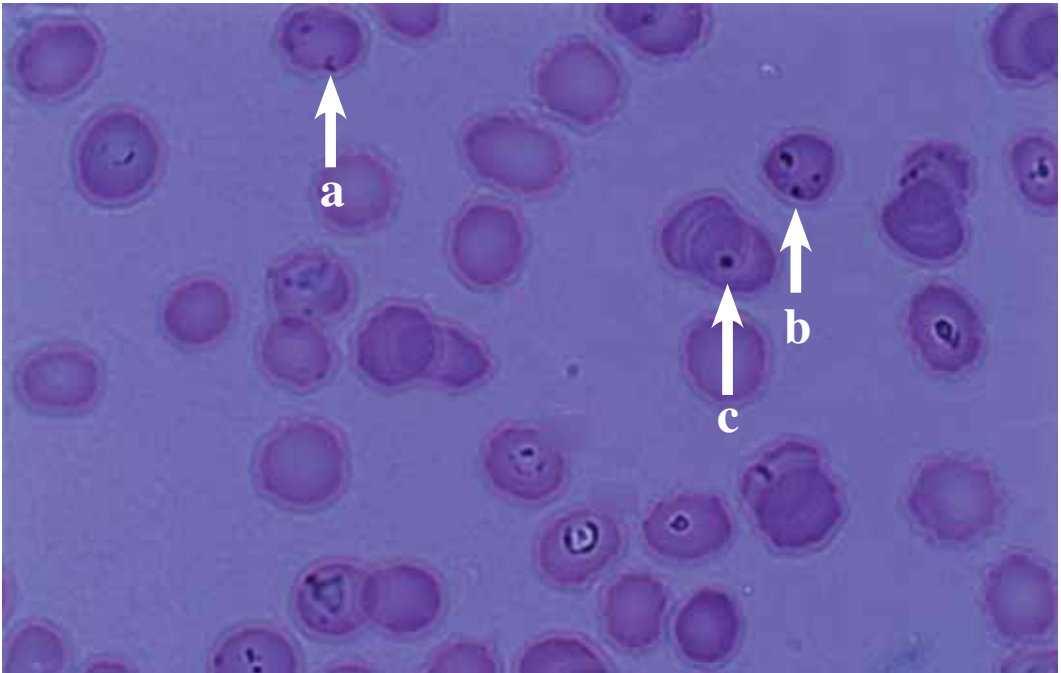
Since virtually every RBC is infected with Babesia, these wormlike forms are likely to be Babesia.



These cells look infested with Babesia. It is possible during the long preparation process some decay occurred which made some rings have breaks.

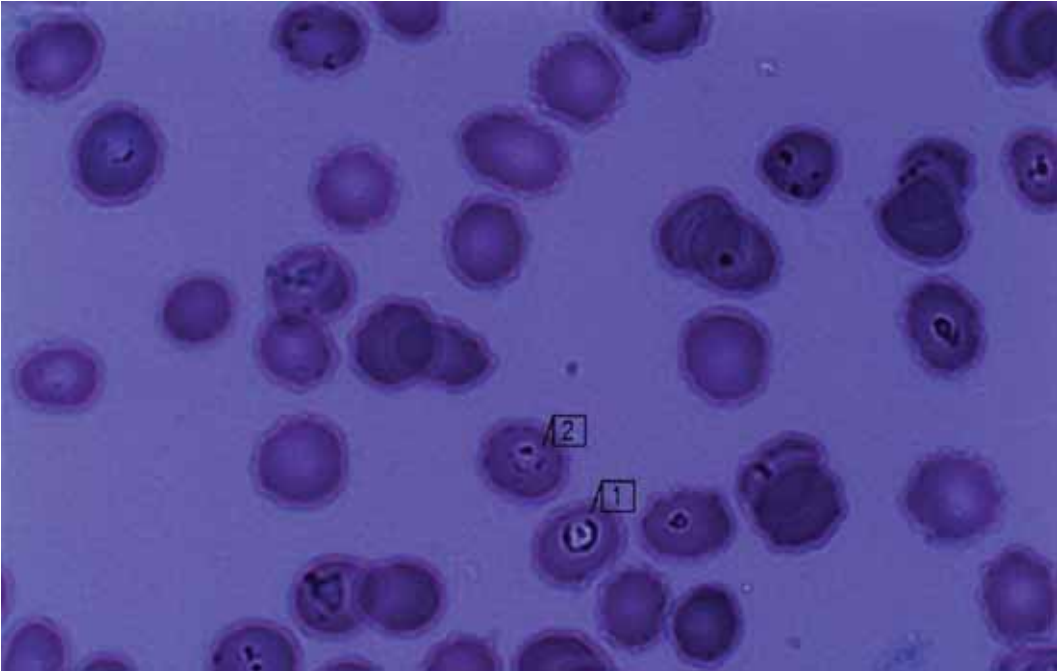


This is a British patient who had blood infected with *Bartonella* confirmed by many labs using a wide range of testing. She has three cats. She has no *Babesia* based on history, direct lab testing and indirect lab testing.

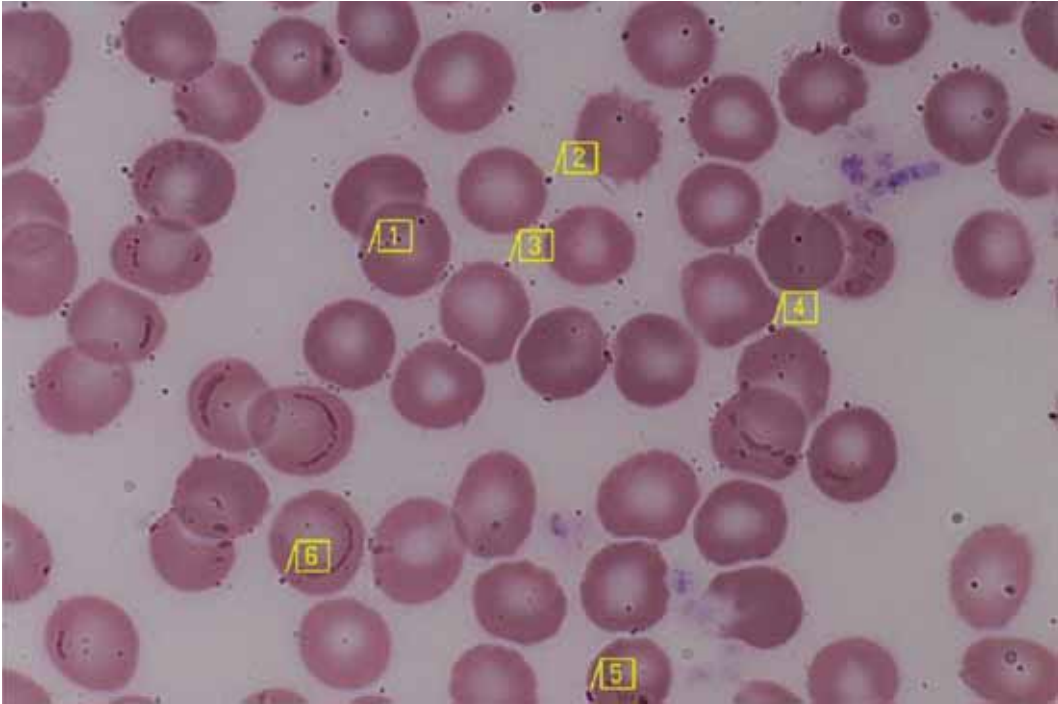


a-b: Initially I thought these might be Bartonella forms. However, these are generally profoundly quite thick. The Bartonella forms we have found inside cells seem to be long and sausage-like or dots. They generally do not look solid with fat tear drop shapes. I propose they may be Babesia forms.

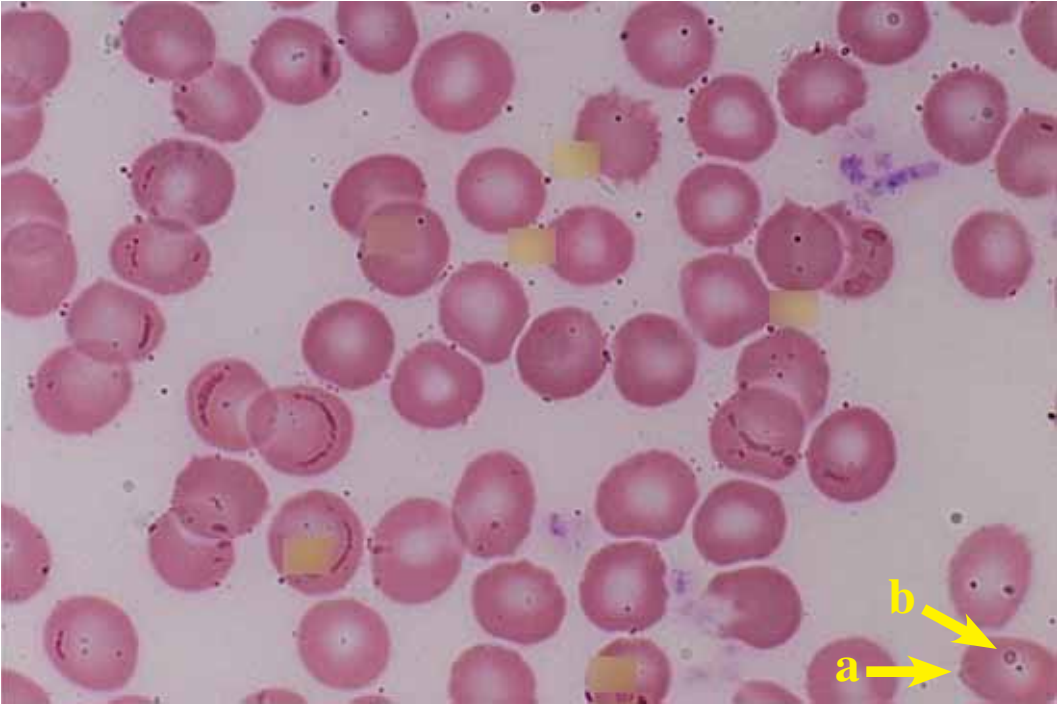
I do not believe a or b are Pappenheimer bodies because they have no cytoplasm around them, and one also does not see clear anemia in this patient with normal iron blood values.



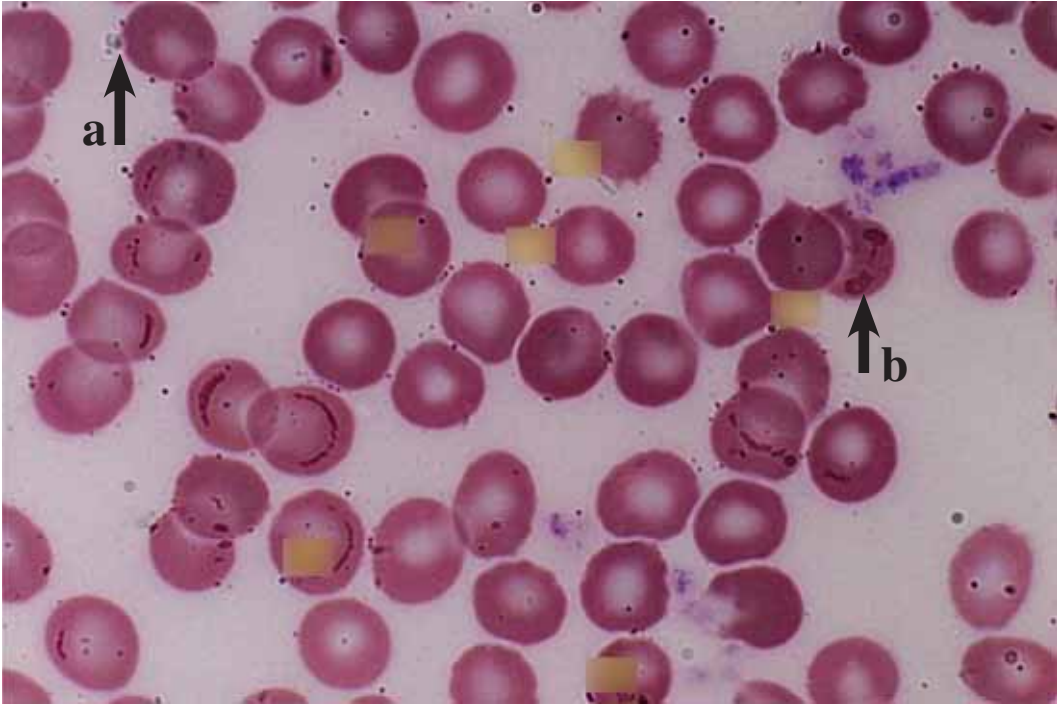
Box 1 and 2: These are likely crescent or roughly formed Babesia ring forms.



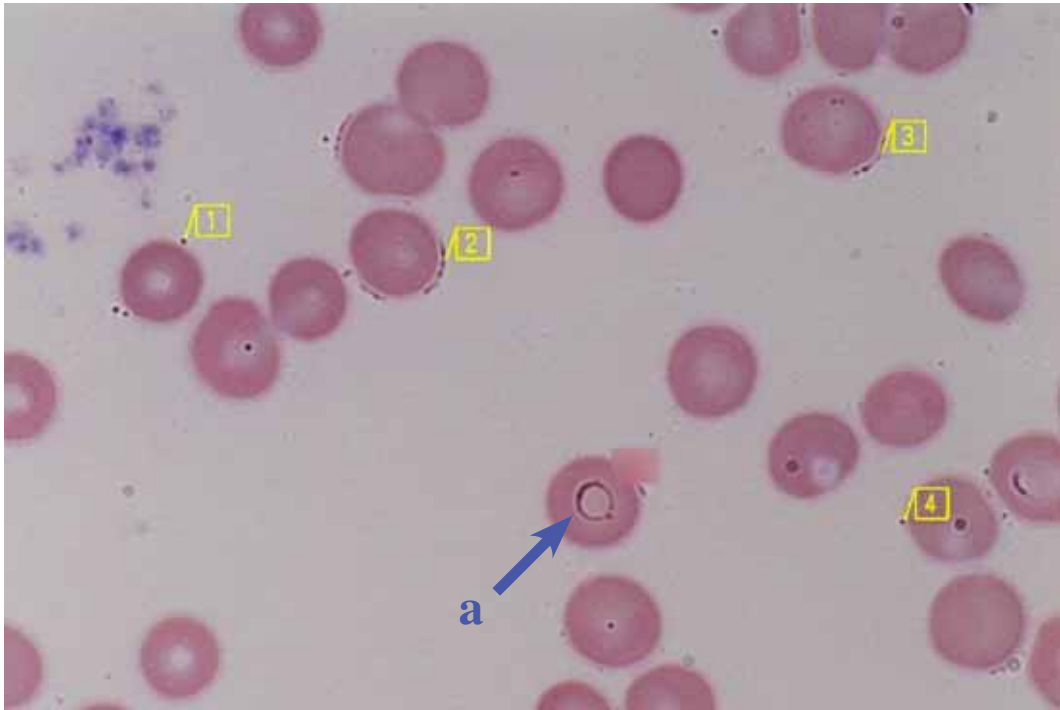Most of the numbered forms are likely Bartonella.



- a. This clear and long rectangular form might be Babesia.
- b. This might be a micro Babesia ring form. But this is not certain.

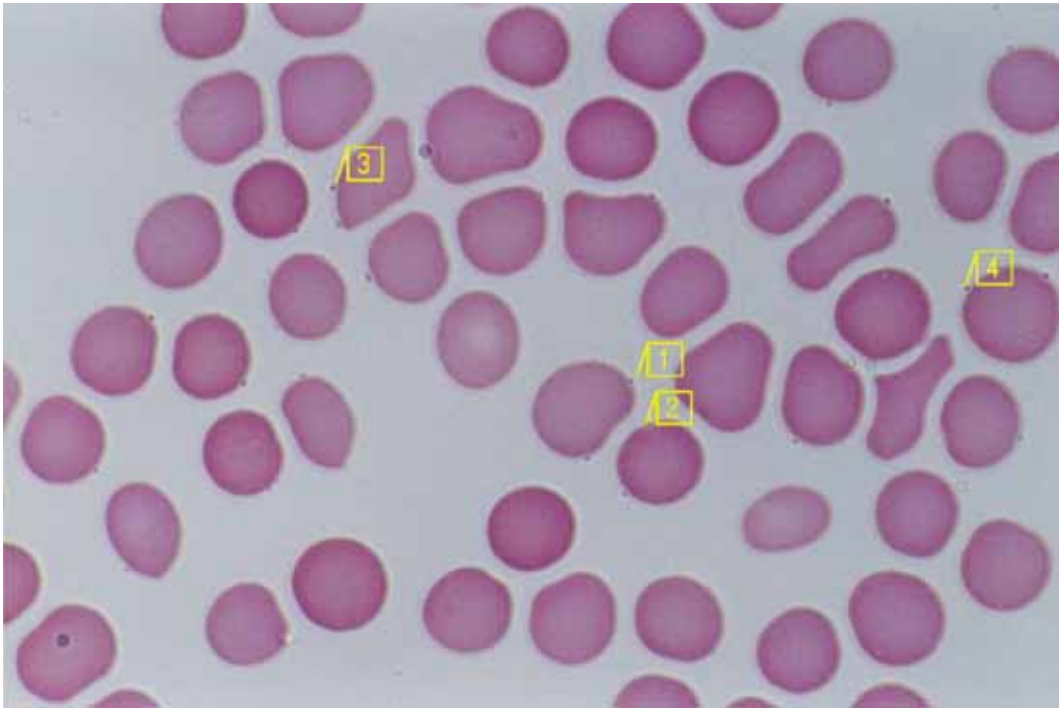


- a. A possible earring Babesia form.
- b. Probably an artifact.

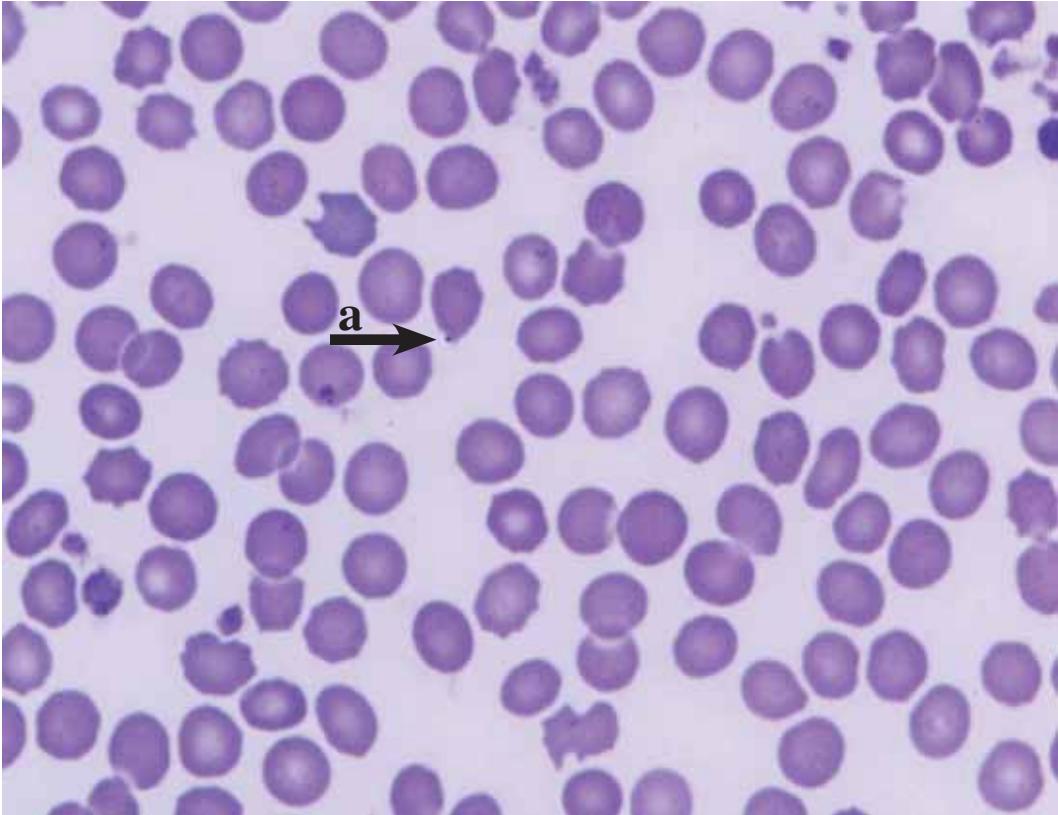


Many individuals have both Bartonella and Babesia, demonstrated in the slide pictured here. Since both types of infection are markedly under-diagnosed, and few health care professionals are up to date on the two thousand articles on each infection, this is a serious problem. Also, many trust poor labs which have invested virtually nothing to advance Babesia and Bartonella laboratory diagnoses. Indeed, many of the sickest people in this book were missed by top national labs, while actual results proved positive with new, indirect testing that we and others are just beginning to publish.

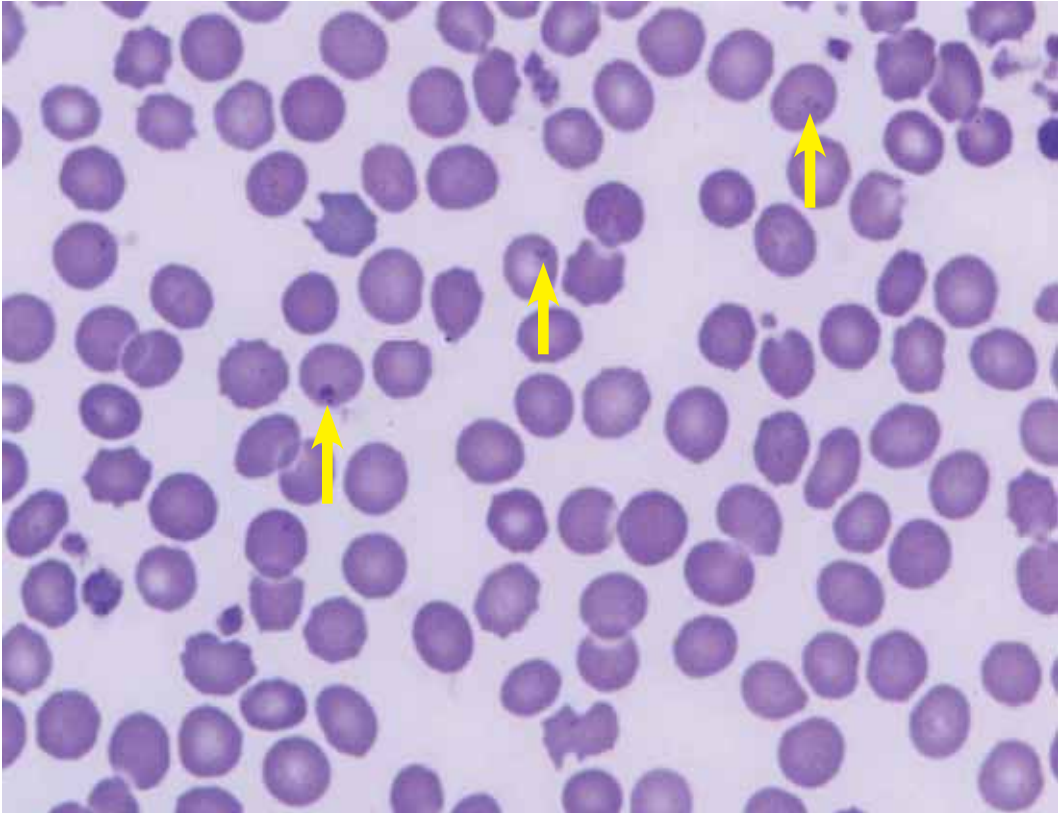
- a. This RBC is surrounded by normal RBCs, so it is doubtful this ring is representative of spleen troubles, iron pathology or genetic pathology. Therefore, I would conclude that this is actually a presentation of Babesia with chromatin dots.



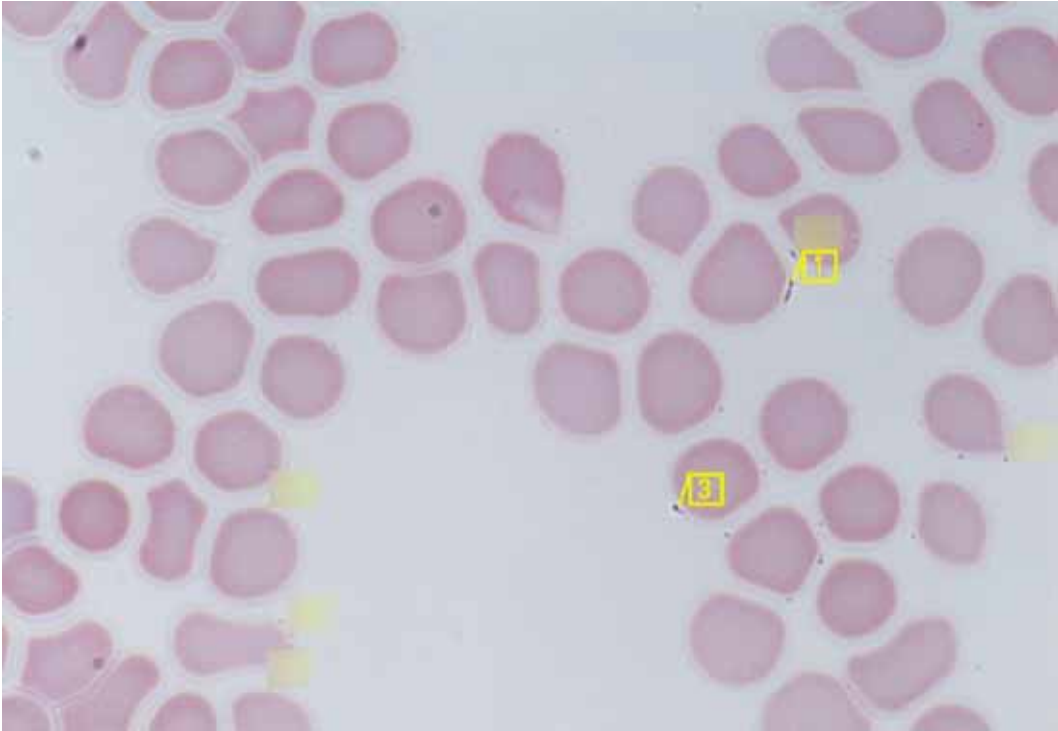
Here we see clear round or oval bacteria which are both small, and neither of which is surrounded by cytoplasm. These are most likely Bartonella. One infectious disease physician called them possible viruses; however, a virus would not typically be visible at this magnification.



- a. The arrow points to a possible Babesia form with a profound amount of cytoplasm around it.

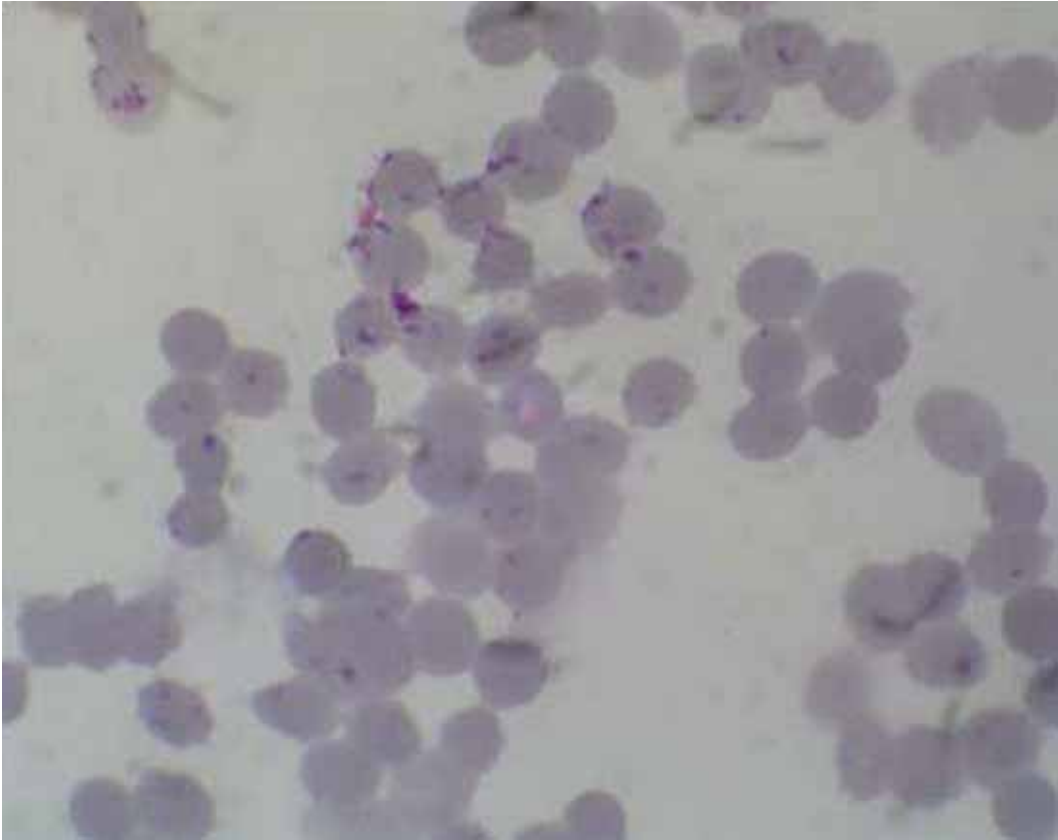

A series of vertical arrows pointing to possible Babesia forms. They are **not clear enough to diagnose** Babesia but only raise the possibility. The use of a magnifying glass might help in examination.



Box 1: This form has a linear part and a dot on the end. It could be a linear Bartonella bacteria next to a dot shaped Bartonella. It could also be two Babesia forms. Therefore I would resist offering a certain reading.

Box 3: The reasoning mentioned in the other marked cell also applies to this one. While this one has a larger dot, and some other dots on the outside of the RBCs are smaller, it is hard to be certain this is an extracellular form of Babesia.



A slide from an unknown source appears to show a wide array of Babesia forms.

Disclaimer

Dr. Schaller is not a dermatologist. He is also not a specialist in infectious disease medicine. He is not a pathologist. He is also not claiming any expertise as a microscopist. Each of these specialties has over 2,000 diseases to treat and study. Dr. Schaller is only interested in four infections and has read and published on only these four. The medical ideas, health thoughts, health comments, products and any claims made about specific illnesses, diseases, and causes of health problems in this book are purely speculative, hypothetical, and are not meant to be authoritative in any setting. No comment or image has been evaluated by the FDA, CDC, NIH, IDSA or the AMA. Never assume any United States medical body, society, or the majority of American physicians endorse any comment in this book. No comment in this book is approved by any government agency, medical body or medical society. Nothing in this book is to be used to diagnose, treat, cure or prevent disease. The information provided in this book is for educational purposes only. It is not intended as a substitute for the advice from your physician or other healthcare professional. This book is not intended to replace or adjust any information contained on, or in, any product label or packaging.

No patient should use the information in this book for the diagnosis or treatment of any health problem, or for prescription of any medication or other treatment. You should consult with a healthcare professional before deciding on any diagnosis, or initiating any treatment plan of any kind. Dr. Schaller does not claim to be an expert in any illness, disease or treatment. In this book, he is merely sharing one of his interests. Please do not start any diet, exercise or supplementation program, or take any type of nutrient, herb, or medication without clear consultation with your licensed healthcare provider.

Babesia or Bartonella treatment comments and reports of possible positive or negative treatment outcomes are hypothetical. No treatment should be rejected or embraced by anyone based on the preliminary research and study in this book.

Some reports in this book are the result of various novel dosing, self-initiated by proactive patients. They were nevertheless monitored often. Some patients were inherited right after various treatment trials. Their outcomes were promptly measured.

In this book Dr. Schaller makes no authoritative proven claim about any treatment. Dr. Schaller only offers hypothetical ideas. Dr. Schaller makes no authoritative claims about medications, nutrients, herbs or various types of alternative medicine. The ideas in this book will need to be submitted to your local expert in allopathic medicine or to other licensed health care practitioners. This book is not meant to be an informal or formal guideline book that presumes to control 800,000 physicians or the 300 million patients they serve. You are asked to let the wisdom of your health care practitioners and your own study be a starting point to guide treatment tailored specifically to your body. Again, Dr. Schaller makes no claim to be an expert in any aspect of medicine. He makes no claim to know more than other physicians.

Dr. Schaller makes no claim that any statement in this book is correct.

Names and minor personal details within this book have been changed to preserve privacy.

Since this appears to be the first book exclusively dedicated to showing Babesia forms, it is likely it contains errors. This is common with books that are the first on a topic. Every reasonable effort has been made to try to not overstate findings. Further, it is important to realize that any single image can have multiple causes, and not all of these may be known to this author or to other health practitioners. Therefore, all health care practitioners should look for other confirmations outside this book, before beginning on any treatment plan if possible. It is fully appreciated that it is hard to diagnose Babesia infections.

BABESIA SEARCH REQUEST LIST

PLEASE LOOK FOR THE FOLLOWING FORMS WHEN YOU SCAN MY SLIDES:

- * ameboid
- * angled form
- * Babesia forms external to the RBC
- * band forms
- * binary fission stage
- * circled tail form
- * crescents on the inside or outer edge of the RBC
- * crown shape
- * double eye pattern
- * earmuff or headphone forms
- * earring pattern
- * fingernail pattern
- * fried egg or eye pattern
- * gametes
- * harp form
- * irregular ring
- * large rings
- * large rings off center
- * merozoites
- * micro rings -- pale and profoundly small
- * micro rings in clusters
- * rabbit ears — together or isolated
- * rings with chromatin dots or chromatin thickenings
- * slit form
- * sporozoites
- * tail form
- * tetrad — together or isolated in 4 pieces
- * trophozoites
- * vacuolated forms
- * worm forms
- * zygote

**Dr. Schaller has been published in
the following Journals and Newspapers:**

Journal of the American Medical Association

Journal of Clinical Neuroscience

Medscape (Academic Journal of WebMD)

Journal of the American Society of Child and Adolescent Psychiatry

American Journal of Psychiatry

European Journal of Child and Adolescent Psychiatry

Compounding Pharmaceuticals: Triad

Fleming Revell Press (Four Languages)

Internal Medicine News

Family Practice News

Spire Mass Market Books

Internet Journal of Family Medicine

Child and Adolescent Psychiatry Drug Alerts

Clinical Psychiatry News

Psychiatric Drug Alerts

Townsend Journal

OB/GYN News

AMA News

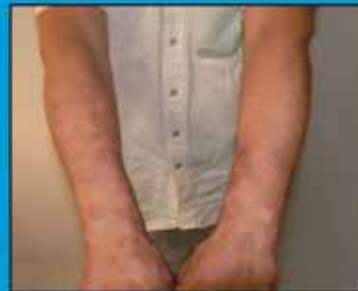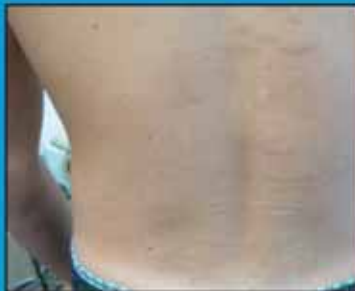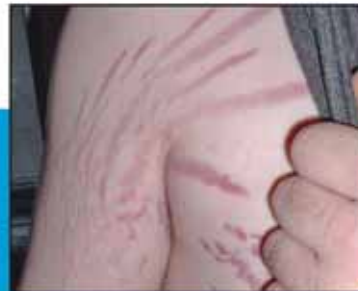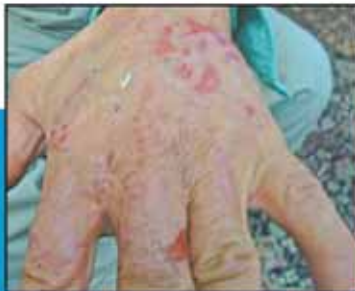Currents

A Sample of Other Books by Dr. Schaller

JAMES SCHALLER, M.D.

The Diagnosis, Treatment and Prevention of **Bartonella**

***Atypical Bartonella Treatment Failures and
40 Hypothetical Physical Exam Findings***

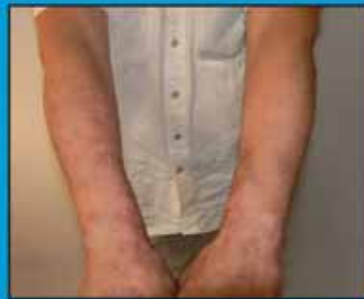
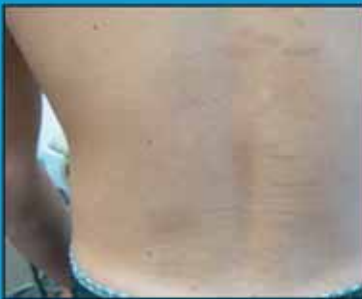
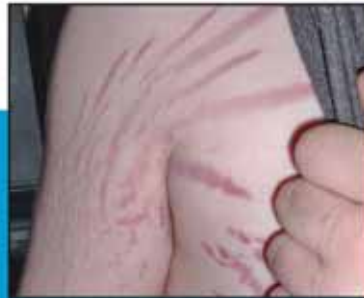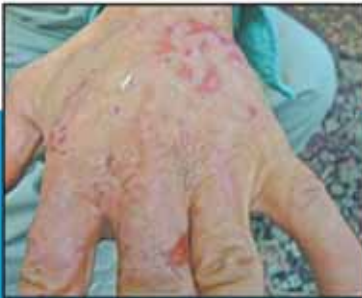FULL COLOR EDITION - PART ONE

JAMES SCHALLER, M.D.

The Diagnosis, Treatment and Prevention of **Bartonella**

***Atypical Bartonella Treatment Failures and
40 Hypothetical Physical Exam Findings***



FULL COLOR EDITION - PART TWO

JAMES SCHALLER, M.D.

The Diagnosis and Treatment of
Babesia



Lyme's Cruel Cousin: the OTHER Tick-borne Infection

Artemisinin, Artesunate, Artemisinic Acid and Other Derivatives of Artemisia Used for Malaria, Babesia and Cancer

**A Health Care Practitioner's Guide to Dosage,
Side Effects, Effectiveness, Toxicity and Interactions.
A Review of the Research on the Most Common
Clinical Artemisia Medications.**

JAMES SCHALLER, M.D.

JAMES SCHALLER, M.D., CMR **GARY ROSEN, PhD, CIE**

MOLD ILLNESS AND MOLD REMEDIATION MADE SIMPLE

Removing Mold Toxins From Bodies and Sick Buildings



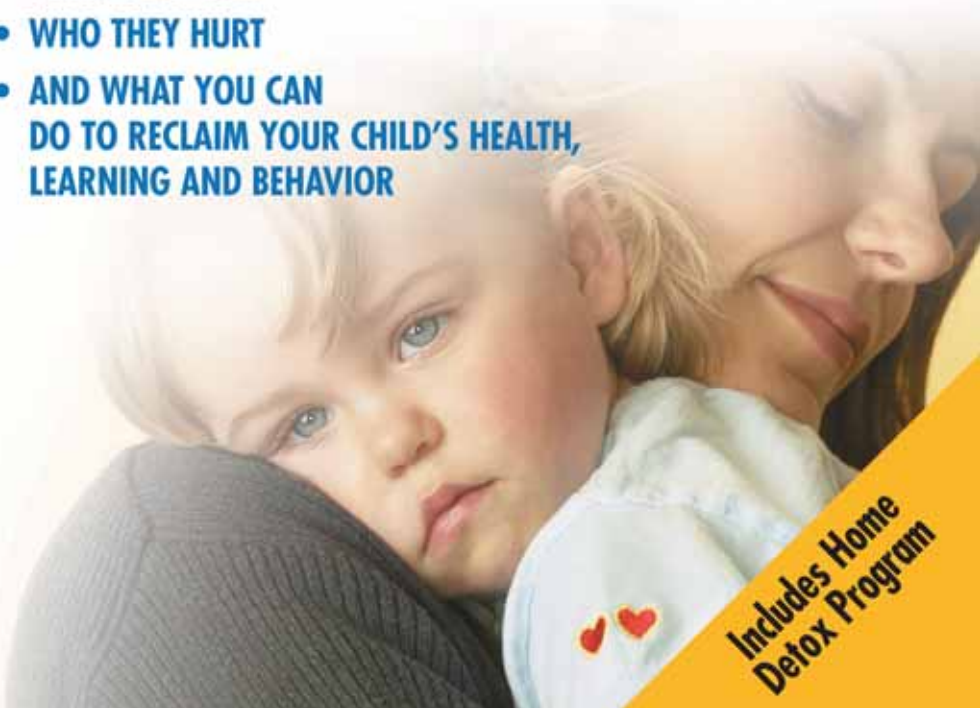This obvious mold is far safer than the mold spore toxins you do not see.

When Traditional Medicine Fails...

YOUR GUIDE TO MOLD TOXINS

Gary Rosen, Ph.D. & James Schaller, M.D.

- WHAT THEY ARE
- WHO THEY HURT
- AND WHAT YOU CAN DO TO RECLAIM YOUR CHILD'S HEALTH, LEARNING AND BEHAVIOR



**Includes Home
Detox Program**

JAMES SCHALLER, M.D.

SUBOXONE

**TAKE BACK YOUR LIFE
FROM PAIN MEDICATIONS!**



JAMES SCHALLER, M.D., M.A.R.

A.D.D. IRRITABILITY AND OPPOSITIONAL DISORDERS

CUTTING-EDGE SOLUTIONS

SINCERE THERAPISTS AND DOCTORS MISS



Contacting Dr. Schaller

Should you wish to talk to Dr. Schaller he offers individualized education consults, which can be arranged by calling 239-263-0133. Please leave all your phone numbers, a working email and a fax number. These are typically in 15 minute units and can last as long as you wish. All that is required is the completion of a short informed consent form.

If you would like a full diagnostic consult or to see Dr. Schaller as a patient, know he treats patients from all over the USA and from outside the country. He meets with you first and then does follow up care with you by phone. He does require you to have a family doctor, internist or pediatrician, since he is only a consultant.

If you would like to fly in to see Dr. Schaller, his staff are very familiar with all the closest airports, and we have special hotel discounts.

I wish you the very best health!

Warm Regards,

Rona C. MBA
Office Manager

A Laboratory Babesia Guide

James Schaller, MD

Babesia is a *powerful emerging infection* that causes dozens of medical problems, including an unknown rate of fatalities.

This is the First Hematology Book Entirely Dedicated to the Identification of Babesia



Dr. Schaller is the author of 25 books, is published in five languages, and has published 27 peer-reviewed journal articles in JAMA and Medscape (academic arm of WebMD). He has also published in some of the largest pediatric, medical, and neurological journals and newspapers in the world. He is the inventor of a natural, bio-identical anti-depressant, and has also published the first case of a functional blood cancer “cure” which has become an international standard.

To contact Dr. Schaller, visit
www.personalconsult.com.

To locate his other current books,
go to Amazon.com and enter
“James Schaller.”

