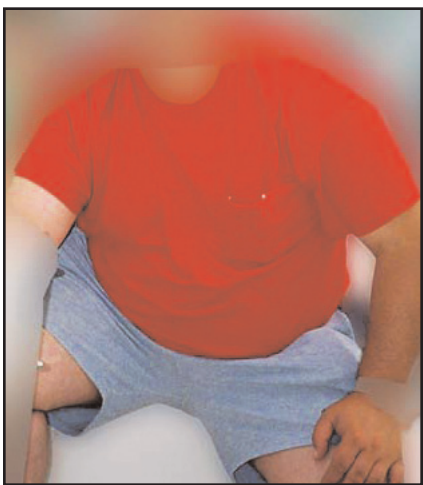

A Sampling of Obesity Photos from Dr. Schaller's Collection



This is a lawyer with Babesia, Bartonella and Lyme. Patient lost 6 inches with limited dieting and no exercise with newer up to date Babesia dosing-not 2 teaspoons/day of Mepron which typically leads to a relapse. He lost this weight in 7 weeks. He also took aggressive double antibiotic treatment for Lyme disease and Bartonella.

This type of obesity is called "Blown up like a Balloon" obesity in our practice. It is global with perhaps a few modest extra pounds in the belly, rear and thighs, but increased girth all over the body.

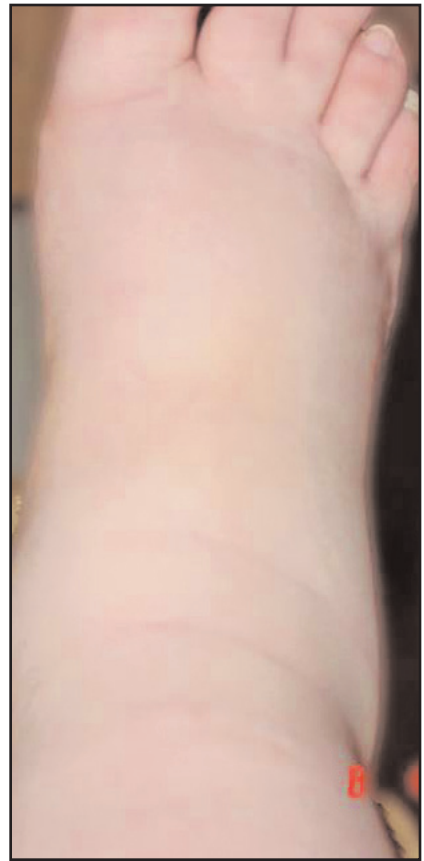

This is full body bloating obesity. The patient is positive for Babesia and Bartonella and was given routine treatments which helped, but then all treatments led to relapse. Treatments included 1500 mg of Mepron per day (only two teaspoons), Artesunate (Artemisia) at a useless dose of three/day, high dose Artemisinin, high doses of Zithromax, Biaxin, Levaquin, Minocycline, gentamycin and Rifampin. We have found these treatments generally only lower the body volume of both infections-they do not cure.

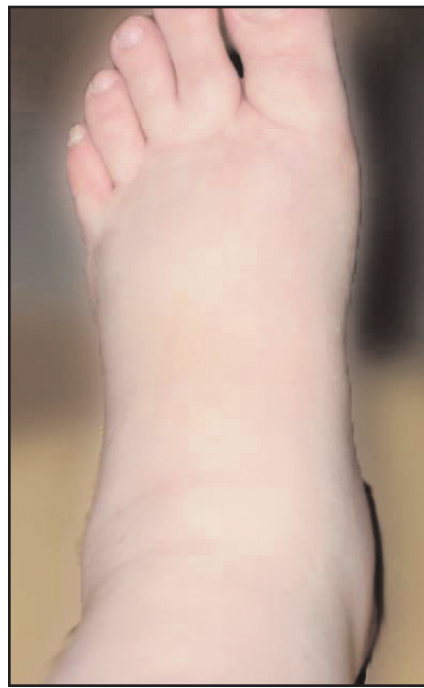This man lost some weight on some of these treatments but it rapidly returned to his very high baseline. We hypothesize both Bartonella and Babesia contributed to his obesity and transient weight loss.



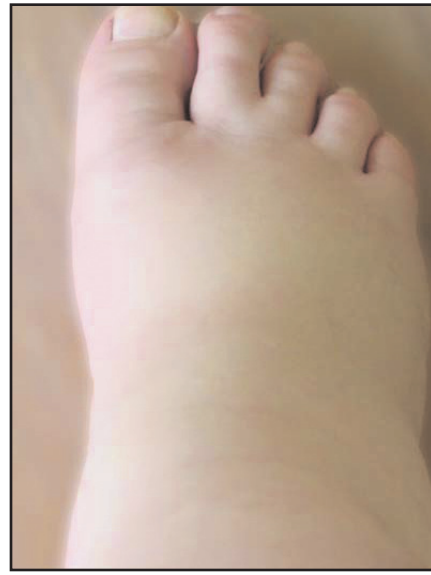Same patient with massive obesity throughout his entire trunk area, including his back tissues and not just his lower abdomen.



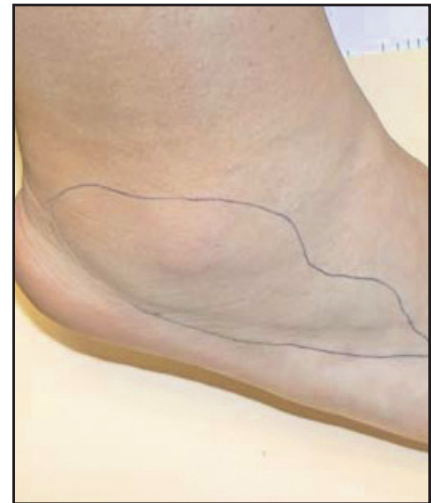This 35 year old Texas woman has clear Bartonella and also meets CDC criteria for Lyme at a large national lab. Please note the massive non-pitting swelling of her entire lower legs.



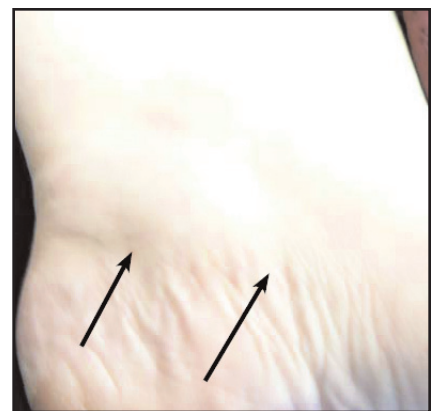
After taking a new Bartonella treatment that quickly clears the blood of visualized Bartonella, her legs significantly decreased in size.



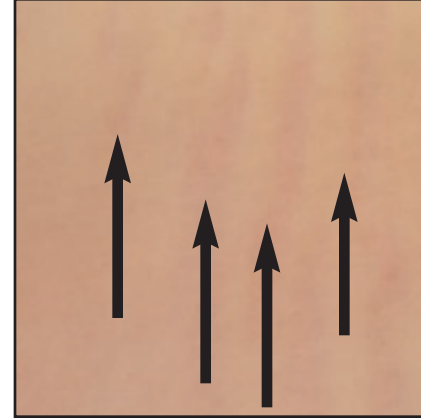
This same woman was told by her cardiologist that her heart Echo was "that of a 25 year old" and her EKG was normal. Her WBCs however had been abnormally high at "16" for years. Two diuretics at full strength had zero impact on this swelling which did not pit. We have found Babesia and Bartonella edema typically does not pit. The cause for this edema or high white blood cell count has never been found, despite consultations with over 15 respected specialists.



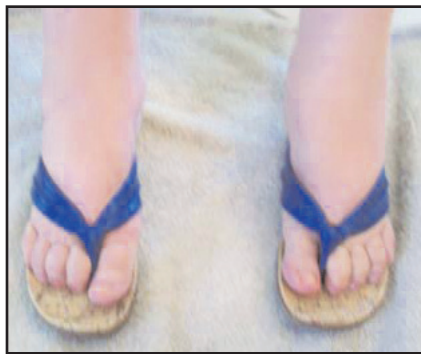White female in her late 30's with markedly enlarged feet and calves with no pitting of the skin when pressed, but they are markedly enlarged. She is only positive for Bartonella at this time. The outlined area is particularly enlarged.



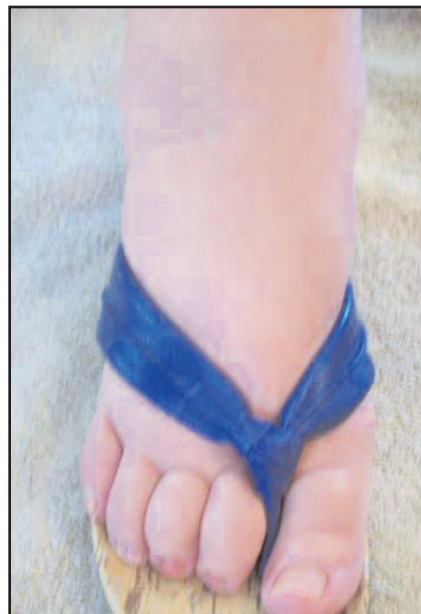This physician has a long band of large and protruding tissue along the foot joint. He is Bartonella and Lyme disease positive. We believe these foot findings might be related to body obesity, since one merely seems to be a worse case of the same problem.



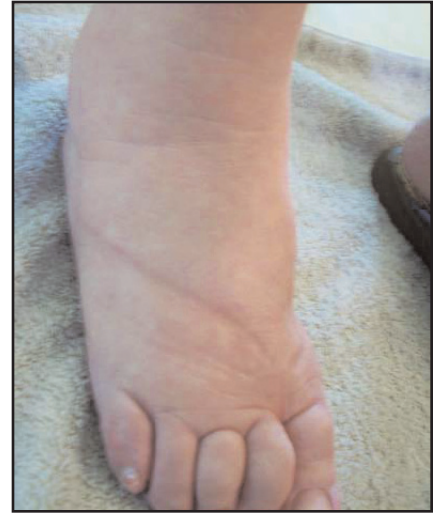These are easy to miss Bartonella striations on one side of an obese female who has failed care with two smart Bariatric experts. She has lost weight with aggressive and newly researched Babesia and Bartonella treatments. Lyme treatments worked effectively after this because Lyme cannot be cured with massive Bartonella suppression -- only the Lyme body load can be reduced. Bartonella is far more common than Lyme. It can never be a side topic in LL medical care. Never.



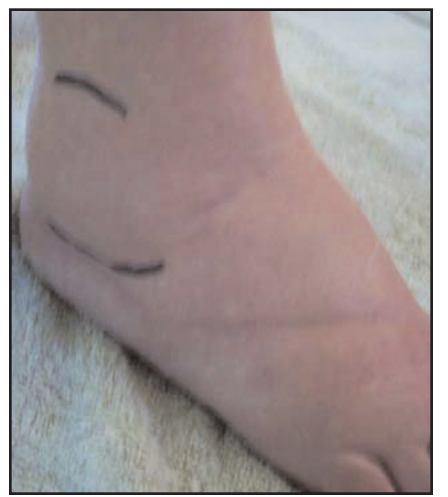Patient with clear Bartonella who is improving on HH capsules and losing weight after two types of water pills, cardiac medications and diet/exercise failed. HH lowered the size of these entire legs 2 inches after a short modest trial.



Same woman with front view. This was markedly worse and had a higher diameter in the past, before treatment was started by her daughter in the form of the pharmacological herb mix HH, which is designed to kill bacteria of the Bartonella class.

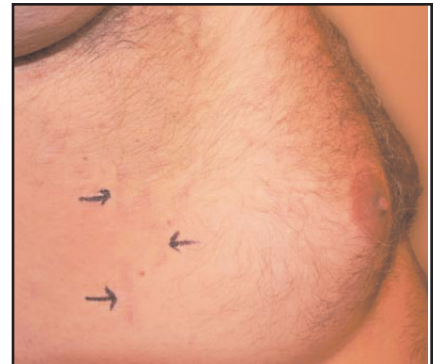


Same woman with sandal removed. See the deep indentation from the sandal. But she has no pitting in any form when you press on her enlarged sections. The tissue does not indent in any way. This is not like routine congestive heart failure enlarged legs, and in fact, her ECHO and other cardiac tests were fully normal. Her leg blood vessel tests were also normal.



Same woman. Note the enlarged ankle joint collection, the large size of the top of the foot and also the enlarged side of the foot.

This was ignored over 8 years during her exams. This has markedly improved with initial Bartonella treatment.



A young man in his late 20's with Bartonella, Lyme disease and Babesia. The later two were treated very aggressively. This huge excess skin and fat on his chest and side is believed to be due to Bartonella or residual Babesia. Another angle shows a drooping upper arm and large fat filled breasts. Black arrows point to acute colored striations or residual white or skin colored residual striations found in some patients with Bartonella.

pha



Therasage
FEEL THE HEAT!

Therasage Home Sauna with Far-Infrared Heat

Massage Bed

Healing Pad

HEATING PAD FEATURING
Far-Infrared Heat Technology







Therasage is proud to bring you the world's largest storefront featuring products with far infrared heat. Far infrared heat has been widely used for its many therapeutic benefits in the Far East for the past twenty-five years and is now becoming very popular in North America.

(888) 416-4441

www.therasage.com

- RELIEVES BACK PAIN
- REDUCES TENSION AND STRESS
- IMPROVES FLEXIBILITY
- IMPROVES BLOOD CIRCULATION

Made with natural jade stone!